



## Case Report

# Metastatic carcinoid tumor of the ovary-A rare entity and role of CDX2 to distinguish pure primary carcinoid from metastatic carcinoid to the ovary

Ranjana Giri<sup>1,\*</sup>, Urmila Senapati<sup>1</sup>, Subrat Kumar Sahu<sup>2</sup>

<sup>1</sup>Dept. of Pathology, Kalinga Institute of Medical Sciences, Bhubaneswar, Odisha, India

<sup>2</sup>Dept. of Surgery, Kalinga Institute of Medical Sciences, Bhubaneswar, Odisha, India



## ARTICLE INFO

### Article history:

Received 15-01-2020

Accepted 26-02-2020

Available online 15-06-2020

### Keywords:

Metastatic carcinoid tumor

Ovary

CDX2

## ABSTRACT

**Background:** Metastatic ovarian carcinoid is a very rare entity which is usually of primary gastrointestinal origin. Distinction is difficult between pure primary ovarian carcinoid from metastatic carcinoid tumor of ovary, but distinction is very much crucial because it has clinical and prognostic implications.

**Case History:** We are reporting a case of a 55yr old female presented with abdominal pain. Ultrasonography revealed bilateral solid ovarian mass. Macroscopically both the ovaries were enlarged, solid with surface nodularity. Morphology showed tumor cells mostly in insular and acinar configuration, round to oval nucleus, stippled chromatin and granular eosinophilic cytoplasm. IHC for synaptophysin and chromograin were strong positive. CDX2 was done which showed strong nuclear positive in 80% of tumor cells. The tumor was diagnosed as a metastatic carcinoid tumor to the ovary and primary tumor in the small intestine.

**Conclusion:** This case was reported because of its rarity and usefulness of CDX2 to distinguish pure primary carcinoid from metastatic carcinoid to ovary.

© 2020 Published by Innovative Publication. This is an open access article under the CC BY-NC license (<https://creativecommons.org/licenses/by-nc/4.0/>)

## 1. Introduction

Carcinoid tumors are rare causes of ovarian malignancy and represent 0.1% of all ovarian neoplasms.<sup>1</sup> Primary ovarian carcinoids are 2nd most frequent monodermal teratomas. Out of which 15% occur in pure form and 85% combine with other teratomatous elements like struma ovarii and mature teratoma.<sup>1,2</sup> Metastatic ovarian carcinoids are very rare. They are usually of primary gastrointestinal origin.<sup>3,4</sup> Primary ovarian carcinoids usually behave in a benign fashion but metastatic carcinoids are aggressive and associated with poor outcome. Hence distinction between pure primary ovarian carcinoid and metastatic carcinoid is crucial and it has also clinical and prognostic importance.<sup>5,6</sup>

Pure primary carcinoid and metastatic carcinoid morphologically looks alike with no distinguishing features. Recently immunohistochemistry of CDX2 has been used to distinguish primary carcinoid of ovary from metastatic

carcinoid. CDX2 is a nuclear transcriptional factor that appears to be expressed in intestinal epithelium. It has a role in regulation of cell proliferation and differentiation and also acts as a tumor suppressor.<sup>7</sup> CDX2 expression by carcinoid tumors points to GI origin.<sup>4</sup> Midgut tumors and their metastatic tumors express high level of CDX2 compared to foregut and hindgut carcinoids.<sup>8-10</sup> CDX2 positivity is seen in tumors arising in small intestine (95%), appendix (92%) and duodenum (80%) but rare in tumors of colorectum (12%) and stomach (0%).

## 2. Case History

55yr female presented with intermittent right sided abdominal pain for last few months. No medical and gynecological history with regular menstrual cycle. There was a palpable abdominal mass. Ultrasonography showed presence of bilateral solid ovarian mass. The patient underwent hysterectomy with B/L salpingo-oophorectomy. Macroscopically bilateral ovaries were enlarged with

\* Corresponding author.

E-mail address: [drranjana.pth@gmail.com](mailto:drranjana.pth@gmail.com) (R. Giri).

surface nodularity. Cut section was solid homogeneous with no hemorrhage or necrosis (Figure 1). Microscopic examination showed tumor cells of varying size and shape present in a fibromatous stroma. Tumor cells were arranged mostly in insular pattern at places in acinar configuration. Lumen contains homogeneous eosinophilic secretion and calcification (Figure 2). Tumor cells had round to oval nucleus, stippled chromatin with abundant granular eosinophilic cytoplasm. Focal area showed mild nuclear atypia and occasional mitosis. Vascular invasion was also noted. IHC for synaptophysin and chromogranin was done. Both were strong positive. Diagnosis of ovarian carcinoid was done. To distinguish between primary or metastatic carcinoid, IHC of CDX2 was done and it showed strong nuclear positive in 80% of tumor cells (Figure 3). Considering the clinical presentation and immunohistochemical findings, the tumor was diagnosed as metastatic carcinoid to the ovary and the primary location could be in the small intestine. On thorough examination primary lesion was detected in the small intestine.

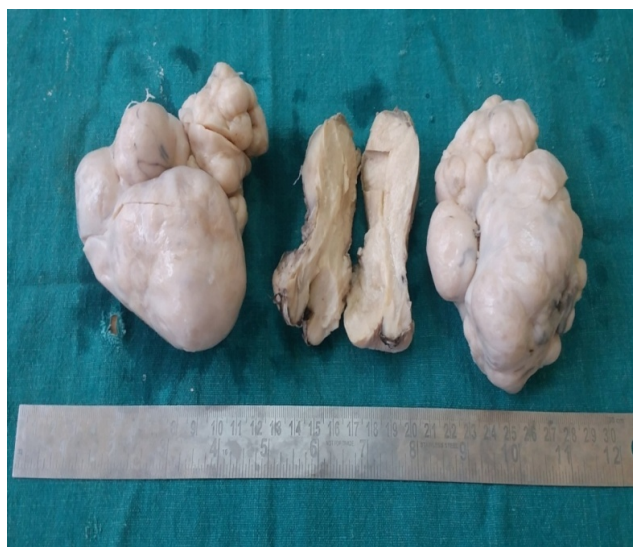Metastatic carcinoid tumors to the ovary are very rare. Distinguishing primary and metastatic carcinoid is practically impossible by cytomorphologic features alone. Up to certain extent clinicopathological features may help to discriminate between these two. Metastatic ovarian carcinoids are usually bilateral, multinodular with presence of lymphovascular invasion, but primary ovarian carcinoids are unilateral, usually arise in a setting of mature cystic teratoma. Distinction between primary and metastatic carcinoid is of clinical and prognostic significance. The former usually follows a benign course. On the other hand metastatic carcinoids have worse prognosis.

It is relatively easy to diagnose tumor as ovarian primary in the setting of associated teratoma. But in case of pure ovarian carcinoid it is difficult to distinguish them from metastatic GI carcinoids especially from small intestinal/duodenal metastasis. In that situation IHC of CDX2 will be useful to confirm metastatic GI carcinoids to ovary.

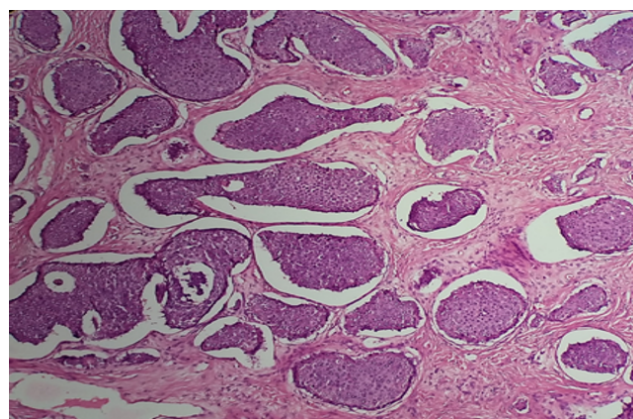
In our case though clinical presentation like bilaterality, multinodularity, absence of teratomatous component was favouring towards metastatic carcinoids but still IHC for CDX2 confirm diagnosis as metastatic carcinoid to ovary which is of small intestine (midgut) origin.

### 3. Conclusion

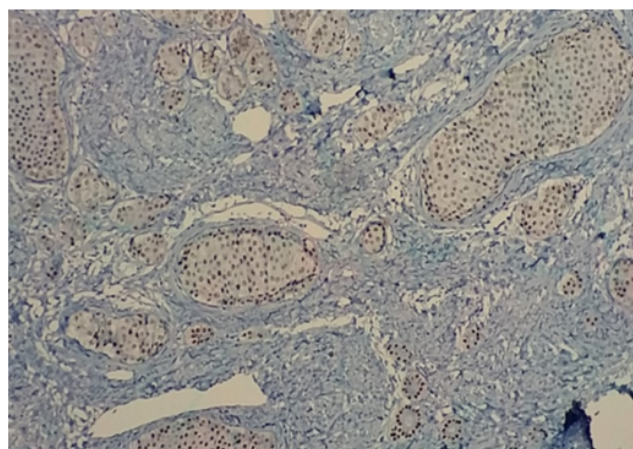
Metastatic carcinoid tumor to ovary is a very rare entity and CDX2 can be useful marker distinguishing pure primary ovarian carcinoid from metastatic GI carcinoid. However clinicopathological features including laterality, growth pattern, lymphovascular invasion and teratomatous components are important variables that should be taken in to consideration in case to case basis.



**Fig. 1:** Gross appearance of B/L ovary showing enlargement with multinodularity. Normal uterus, cervix



**Fig. 2:** Tumor cells mostly in insular pattern. (H&E, 100X)



**Fig. 3:** Tumor cells are positive for CDX2 (IHC, 100X).

#### 4. Source of Funding

None.

#### 5. Conflict of Interest

None.

#### References

1. Modlin IM, Lye KD, Kidd M. A 5-decade analysis of 13,715 carcinoid tumors. *Cancer*. 2003;97(4):934–59.
2. Baker PM, Oliva E, Young RH, Talerman A, Scully RE. Ovarian Mucinous Carcinoids Including Some With a Carcinomatous Component. *Am J Surg Pathol*. 2001;25(5):557–68.
3. Baker PM, Oliva E, Young RH, Talerman A, Scully RE. Ovarian Mucinous Carcinoids Including Some With a Carcinomatous Component. *Am J Surg Pathol*. 2001;25(5):557–68.
4. Takeuchi M, Matsuzaki K, Uehara H. Primary carcinoid tumor of the ovary: MR imaging characteristics with pathologic correlation. *Magn Reson Med Sci*. 2011;10(3):205–9.
5. Scully RE, Young HR, Clement PB. Monodermal teratomas. Tumors of the ovary, mal developed gonads, fallopian tube, and broad ligament. Washington, DC: Armed Forces Institute of Pathology; 1998.
6. Talerman A, Evans MI. Primary trabecular carcinoid tumor of the ovary. *Cancer*. 1982;50(7):1403–7.
7. Guo RJ, Suh ER, Lynch JP. The role of Cdx proteins in intestinal development and cancer. *Cancer Biol Ther*. 2004;3(7):593–601.
8. Jaffee IM, Rahmani M, Singhal MG, Younes M. Expression of the intestinal transcription factor CDX2 in carcinoid tumors is a marker of midgut origin. *Arch Pathol Lab Med*. 2006;130:1522–152.
9. Erickson LA, Papouchado B, Dimashkieh H, Zhang S, Nakamura N, V R. Lloyd Cdx2 as a marker for neuroendocrine tumors of unknown primary sites. *Endocr Pathol*. 2004;15:247–252.
10. Lin X, Saad RS, Luckasevic TM, Silverman JF, Liu Y. Diagnostic Value of CDX-2 and TTF-1 Expressions in Separating Metastatic Neuroendocrine Neoplasms of Unknown Origin. *Appl Immunohistochem Mol Morphol*. 2007;15(4):407–414.

#### Author biography

**Ranjana Giri** Associate Professor

**Urmila Senapati** Professor and HOD

**Subrat Kumar Sahu** Associate Professor

**Cite this article:** Giri R, Senapati U, Sahu SK. Metastatic carcinoid tumor of the ovary-A rare entity and role of CDX2 to distinguish pure primary carcinoid from metastatic carcinoid to the ovary. *Indian J Obstet Gynecol Res* 2020;7(2):273-275.