



Original Research Article

Fine needle aspiration cytology in assessment of lymph node lesions

Sanya Sohal¹, Mayurika S Tyagi^{1,*}, Swati Singh¹, Subir Mitra¹, Priyanka Gulati¹¹Dept. of Pathology, Santosh Medical College and Hospital, Santosh Deemed to be University, Ghaziabad, Uttar Pradesh, India

ARTICLE INFO

Article history:

Received 25-03-2020

Accepted 11-05-2020

Available online 31-07-2020

Keywords:

Lymph node

Fine needle aspiration cytology

FNAC

Tubercular lymphadenitis

Reactive lymphadenitis

Lymphoma

ABSTRACT

Introduction: Fine needle aspiration cytology (FNAC) is widely accepted as the accurate, sensitive, specific and cost-effective procedure in the diagnosis of lymphadenopathy. Tubercular lymphadenitis is one of the most common causes of lymphadenopathy in developing countries like India.

Materials and Methods: An observational study was carried out at the pathology department of teaching hospital in Delhi NCR from March 2013 to April 2017. A total of 3392 patients presented in the FNAC OPD of the hospital, out of which 1730 had lymphadenopathies. Smears were stained with Giemsa and categorised into the cytological pattern. Zheil Neelson (ZN) stain was done in all clinically suspicious cases to tuberculosis. Data regarding brief history, site, age, sex, the gross appearance of aspirate and cytomorphic features were collected and analysed.

Results: Out of the 1730 cases of consecutive lymph node aspirations, 17 were excluded from the study due to inadequate material, 979 cases (57.15%) showed features of Tubercular Lymphadenitis followed by Reactive Lymphadenitis, 524 cases (30.58%). Out of the 20 cases which showed HIV positivity 18 showed the presentation of tubercular lymphadenitis. TB was prevalent in all age groups, with the majority of cases affecting people more than 50 years of age.

Conclusion: FNAC of lymphadenopathy is of particular importance in view of the high prevalence of tuberculosis in our country, atypical presentation of tuberculosis and because AFB are seen mostly in purulent aspirate smears which do not show granulomas, necrosis or epithelioid cells and which in the absence of Ziehl-Neelsen staining can be dismissed as acute suppurative lymphadenitis. FNAC is a simple, reliable, quick and economical diagnostic tool for peripheral lymph node lesions especially in the quick and simple diagnosis of Tubercular Lymphadenitis.

© 2020 Published by Innovative Publication. This is an open access article under the CC BY-NC license (<https://creativecommons.org/licenses/by-nc/4.0/>)

1. Introduction

Lymphadenopathy is one of the most frequent clinical presentations of patients, attending the outpatient department. The cause may be a reactive inflammatory process, granulomatous disease, and malignant conditions. Enlarged lymph nodes are easily accessible for fine-needle aspiration, and hence fine needle aspiration cytology (FNAC) is a straightforward and vital diagnostic tool for lymph node lesions.

Malignancies in lymph nodes in the studied region are predominantly metastatic in nature with an incidence

varying from 65.7% to 80.4%^{1,2} and lymphomas range from 2% to 15.3%² among lymph nodes aspirated from all sites. Although the histopathological examination is considered to be the gold standard in diagnosis especially in lymphomas, FNAC may be the more accessible tool for diagnosis and further management of the patients in some cases of metastatic malignancy because it is a quick and rapid procedure with low processing time. FNAC of lymphadenopathy is of particular importance given the high prevalence of tuberculosis in our country, atypical presentation of tuberculosis and because of the fact that AFB are seen mostly in purulent aspirate smears which do not show granulomas, necrosis or epithelioid cells and

* Corresponding author.

E-mail address: somyamayuri@hotmail.com (M. S. Tyagi).

which in the absence of Ziehl-Neelsen staining can be dismissed as acute suppurative lymphadenitis. This study was undertaken to study the Role of Fine Needle Aspiration Cytology in the diagnosis of Peripheral Lymph Node Lesions.

2. Materials and Methods

An observational study was carried out at pathology department of teaching hospital in Delhi NCR from March 2013 to April 2017, after obtaining Ethical clearance from the institution. A total of 3392 patients presented in the FNAC OPD of the hospital, out of which 1730 had lymphadenopathies. After taking consent, FNAC of the affected lymph node was performed with full aseptic precautions. Seventeen in adequate smears were excluded from the study, 1713 adequate smears were prepared. FNAC was performed using a 23-gauge needle. An average of two passes was performed, and minimum 4-5 slides were prepared. Two slides were air-dried and stained by Giemsa stain, and two slides were fixed in alcohol and then stained with PAP stain, one slide was reserved for ZN stain or any special stain if required. The aspiration smears from the enlarged lymph nodes were studied to arrive at a probable diagnosis. In all cases where the cytological features of a granulomatous disease or necrosis were observed, Ziehl-Neelsen staining was performed to see for acid-fast bacilli, periodic acid–Schiff for mucin were done whenever required. The cytological results were compared with histological findings, whenever possible.

A detailed history (i.e. age, sex, site and duration of involvement and other investigations performed, were recorded.) and clinical examination were documented. Statistical analysis done by using Microsoft Excel and appropriate statistical methods.

3. Results

Lymphadenopathy is one of the most common clinical presentation among the patients attending the cytology department in the NCR region in which the study was conducted.

Based on cytomorphological features, the cases were divided into eight categories:

1. Tubercular lymphadenitis - revealed necrotic material, epithelioid cells, lymphocytes and an occasional giant cell.
Cytologically the cases included as suggested by Das et al. were: Epithelioid granuloma without necrosis, Epithelioid granuloma with necrosis, necrosis without epithelioid granuloma with neutrophilic infiltrate.³
2. Reactive Lymph Nodes-The criteria by which a diagnosis of reactive hyperplasia was established included high cell density, polymorphic patterns of cells and a considerable number of tingible bodies

macrophages.

3. Metastatic Malignancies - showed malignant epithelial cells, usually arranged in groups or cluster, along with other lymphoid cells.
4. Lymphomas- Non-Hodgkin's lymphoma showed a monocellular pattern, consisting of lymphoblasts or lymphocytes.
5. Chronic Inflammatory Lymphadenitis- A large number of small lymphocytes are seen, along with high cell density.
6. Acute Suppurative Lymphadenopathy - Suppurative lymphadenitis cases showed predominantly polymorphonuclear leukocytes, necrotic debris and other lymphoid cells.
7. Non-Tubercular Granulomatous Lymphadenitis- presence of epithelioid cell granuloma with or without giant cells and with the absence of necrosis.
8. Hodgkin's Lymphoma - Showed a mix cell population with the characteristic Reed Sternberg giant cell.

Tubercular lymphadenitis is the most common presentation with 57.15% (979 cases) followed by Reactive Lymphadenitis with 30.58% (524 cases), metastatic malignancies 8.23% (141 cases) and lymphomas 1.8% (32) (Table 1).

Lymphomas comprised 1.8% of total cases with 29 cases of Non-Hodgkin's lymphoma and 3 cases of Hodgkin's lymphoma. All 3 cases were of nodular sclerosis type.

Table 1: Various types of Lymph node lesions (n=1713)

S. No.	Type of Lymphadenopathy	Number	Percentage
1	Tubercular Lymphadenitis	979	57.2
2	Reactive Lymph Nodes	524	30.6
3	Metastatic Malignancies	141	8.2
4	Lymphomas	29	1.7
5	Chronic Inflammatory Lymphadenitis	17	1.0
6	Acute Suppurative Lymphadenitis	14	0.8
7	Non-tubercular Granulomatous Lymphadenitis	6	0.4
8	Hodgkin's Lymphoma	3	0.2
Total		1713	100

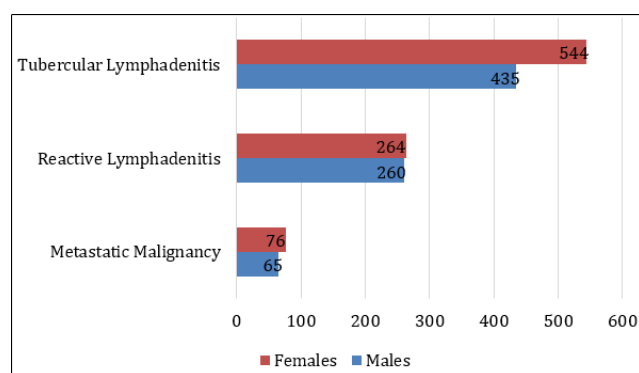
All age groups were involved. In the present study, reactive lymphadenitis was more prevalent in younger age groups (10 – 20 years). Tubercular cases were seen more commonly in the 50-60 and >60 age group (Table 2).

In a few cases, screening tests for HIV were performed according to suspicion of the clinician, 20 cases were screened positive. Eighteen of the affected cases also showed tubercular lymphadenitis. The remaining 2 cases showed reactive lymphadenopathy.

Table 2: The age wise distribution of tubercular lymphadenopathy (n=979).

S. No.	Age group	No. of TB cases	Percentage
1	0-10	51	5.2
2	10-20	58	5.9
3	20-30	110	11.2
4	30-40	124	12.7
5	40-50	133	13.6
6	50-60	325	33.2
7	60 and above	178	18.2
	Total	979	100

The cases were analysed based on the sex of the patient. Tubercular lymphadenitis was the most common diagnosis in both men and women. Male to female ratio in Tubercular Lymphadenitis was 1:1.25, and in Reactive Lymphadenitis was 1:1 (Figure 1). The cases were analysed based on site. Table 2 shows the various lymph node groups affected, cervical lymph nodes being the most common (86%).

**Fig. 1:** Incidence of reactive, tubercular and metastatic lymph node lesions in males and females**Table 3:** Common sites of lymphadenopathy

S. No.	Site	No. of cases	Percentage
1	Cervical	1473	86%
2	Axillary	171	10%
3	Inguinal	52	3%
4	Supraclavicular	17	1%
	Total	1713	100

Gross appearance of the aspirates was analysed. The maximum number of aspirates were blood mixed, 61% (1045 cases) followed by cheesy/caseous 25.3%, (433 cases). Purulent appearance aspirates were only 13.7% (235 cases). Size of lymph nodes varied from 0.8 cm to 4.6 cm. Majority of the nodes were in the 1 to 3 cm size range (74%) (Table 4).

Table 4: The size distribution of lymph nodes

S. No.	Size	No. of cases	Percentage
1	<1 cm	154	9
2	1-3 cm	1268	74
3	>3 cm	291	17
	Total	1713	100

4. Discussion

Fine needle aspiration cytology is a easy, safe, cost-effective, time saving and suggests diagnosis rapidly without the need for surgery or any other complicated procedure.

Lymphadenopathy, as a clinical manifestation of a disease, gives a unique path that might lead to the diagnosis of the underlying condition. Depending on the geographical condition and socio-economic setup, it can arise from benign or malignant causes.⁴ In the context of granulomatous disorders, the possible aetiology is vast, and the use of FNAC with other ancillary tests (microbiological, immuno-histochemical, radiological, biochemical and special staining techniques) is useful for obtaining a definitive diagnosis. Cytology of lymph nodes has become a highly utilised diagnostic tool for many diseases due to the early availability of results and minimal trauma with few complications. FNAC is cost-effective and accurate as a first-line investigative technique. The differential diagnoses include inflammatory conditions, granulomatous diseases and malignancy. In comparison with more costly surgical excision biopsies, FNAC has also been advocated as a useful method, especially in developing countries with limited financial and health care resources. Combined with clinical experience, the optimal material collection makes cytological discussion of high significance. From patient presentation alone, it is challenging to decide whether a diagnosis of reactive or neoplastic lymphadenopathy is more likely. The knowledge about the various patterns of lymphadenopathy is helpful to the clinician for solving the dilemma.⁵

In the present study cervical region was the most frequent site of lymphadenopathy (86%) followed by axillary (10%) and inguinal (3%). Cervical region was also seen as the most common site of involvement in other studies.^{6,7}

Reddy et al. studied the lymph nodes according to their size and site of presentation. They had concluded that size of more than 1.5 cms in the inguinal region, 1 cms in cervical and axillary region lymph node, and more than 0.5 cm at any other site are to be considered significant.⁸ In the current study although the lymph node lesions were considered according to size, no substantial conclusion could be made according to the size and site of presentation of lymphadenopathy.

Tubercular lymphadenitis (57.2%) was found to be the most common disorder, probably due to low socio-

economic strata of the population in the area. This was relevant to the previous Indian studies.^{9,10} The percentage was found to be higher than western studies, due to the extremely low prevalence of tuberculosis in developed countries.

Dudgeon and Patrick in 1927 first used FNAC in diagnosing TB lymphadenitis followed by Tempka and Kubiczek, Mahanta et al.¹¹ In our clinical setting, tubercular lymphadenitis constituted 57.2% of all lymph node aspirates and was the most common cause of lymphadenopathy. Studies conducted by Rajashekar et al., have shown that no age or gender group was exempted from tubercular lymphadenitis,¹² and we found a similar scenario in our study. This may be attributed to the prevalence of tuberculosis in India along with the low socio-economic status of the population being studied.

Das et al., have described three patterns of tubercular lymphadenitis depending on the cellular components as they represent a spectrum in natural history and progression of TB lymphadenitis.³

1. Epithelioid granuloma without necrosis with a considerable number of lymphocytes.
2. Epithelioid granuloma with necrosis with appreciable giant cells.
3. Necrosis without epithelioid granuloma with neutrophilic infiltrate and high AFB load.

The definite diagnosis of tuberculous lymphadenitis can be made when granulomas composed of epithelioid cells and Langhan's cells are seen along with caseous necrosis.

5. Conclusion

FNAC is a simple, reliable, quick and economical diagnostic tool for peripheral lymph node lesions, especially in peripheral hospitals and OPDs, Tubercular Lymphadenitis being the most common lesion. Reactive lymphadenitis is the second most common cause of lymphadenopathy. Cervical group of lymph nodes are most commonly affected lymph nodes in most of pathological lesions, followed by axillary lymph nodes. Supraclavicular group of lymph nodes are least affected group of lymph nodes in the present study. FNAC helps in the diagnosis of benign, neoplastic and metastatic lesions. It not only confirms the presence of metastatic diseases but also gives the clue regarding the origin of the primary tumor in most cases.

6. Source of Funding

No funding sources.

7. Conflict of Interest

None declared.

References

1. Bagwan IN, Kane SV, Chinoy RF. Cytologic evaluation of the enlarged neck node: FNAC utility in metastatic neck disease. *Int J Pathol.* 2007;6(2):1–7.
2. Alam K, Khan A, Siddiqui F, Jain A, Haider N, Maheshwari V. Fine needle aspiration cytology (FNAC), a handy tool for metastatic lymphadenopathy. *Int J Pathol.* 2010;10(2):1–7.
3. Das DK, Pant JN, Chachra KL, Murthy NS, Satyanarayan L, Thankamma TC. Tuberculous lymphadenitis: correlation of cellular components and necrosis in lymph-node aspirate with AFB positivity and bacillary count. *Ind J Pathol Microbiol.* 1990;33(1):1–10.
4. Qadri SK, Hamdani NH, Shah P, Lone MI, Baba KM. Profile of Lymphadenopathy in Kashmir Valley: a Cytological Study. *Asian Pac J Cancer Prev.* 2012;13(8):3621–5.
5. Das DK, Gupta SK. Fine needle aspiration cytodiagnosis of Hodgkin's disease and its subtypes. II. Subtyping by differential cell counts. *Acta Cytol.* 1990;34(3):337–41.
6. Nidhi P, Sapna T, Shalini M, Kumud G. FNAC in tuberculous lymphadenitis: experience from a tertiary level referral centre. *Indian J Tuberc.* 2011;58(3):102–7.
7. Pandit AA, Candes FP, Khubchandani SR. Fine needle aspiration cytology of lymph nodes. *J Postgrad Med.* 1987;33(3):134–6.
8. Reddy MP, Moorchung N, Chaudhary A. Clinico-pathological profile of pediatric lymphadenopathy. *Indian J Pediatr.* 2002;69(12):1047–51.
9. Malhotra A, Lahori M, Nigam A, Khajuria A. Profile of lymphadenopathy: An institutional based cytomorphological study. *Int J Appl Basic Med Res.* 2017;7(2):100–3.
10. Khajuria R, Goswami KC, Singh K, Dubey VK. Pattern of lymphadenopathy on fine needle aspiration cytology in Jammu. *JK Sci.* 2006;8:145–9.
11. Singh JP, Chaturvedi NK, Das A. Role of fine needle aspiration cytology in the diagnosis of tubercular lymphadenitis. *Ind J Pathol Microbiol.* 1989;32(2):100–4.
12. Rajasekaran S, Gunasekaran M, Jayakumar DD, Jeyaganesh D, Bhanumati V. Tuberculous cervical lymphadenitis in HIV positive and negative patients. *Ind J Tuberc.* 2001;48(4):201–4.

Author biography

Sanya Sohal Postgraduate Resident

Mayurika S Tyagi Assistant Professor

Swati Singh Assistant Professor

Subir Mitra Professor and Head

Priyanka Gulati Postgraduate Resident

Cite this article: Sohal S, Tyagi MS, Singh S, Mitra S, Gulati P. Fine needle aspiration cytology in assessment of lymph node lesions. *Santosh Univ J Health Sci* 2020;6(1):17–20.