



Case Report

Case report on dentigerous cyst in relation to permanent mandibular lateral incisor: A rare entity

Sanjeev Tomar^{1,*}, Upma Tomar²

¹Dept. of Oral and Maxillofacial Surgery, Santosh Dental College, Ghaziabad, Uttar Pradesh, India

²Dept. of Oral and Maxillofacial Pathology and Microbiology, Santosh Dental College, Ghaziabad, Uttar Pradesh, India



ARTICLE INFO

Article history:

Received 30-04-2020

Accepted 11-06-2020

Available online 31-07-2020

Keywords:

Dentigerous cyst
Odontogenic cyst
Lateral incisor
Marsupialization
Enucleation

ABSTRACT

Dentigerous cyst is normally associated with crown of an unerupted or developing tooth and is one of the most common odontogenic cyst. It is more commonly seen in association with mandibular third molar and maxillary canine. Dentigerous cyst generally occurs in second or third decades of life. Its association with incisors are rare entity. Dentigerous cyst usually includes a tooth which can not complete the eruption process and involves the crown by the fluid accumulation in between the layers of enamel organ. The treatment modalities for dentigerous cyst are marsupialization or enucleation and depends upon the involved structures.

Here we report a case of dentigerous cyst associated with permanent mandibular lateral incisor. It was enucleated along with the lingually erupted lateral incisor. There was no recurrence observed after one year follow up.

© 2020 Published by Innovative Publication. This is an open access article under the CC BY-NC license (<https://creativecommons.org/licenses/by-nc/4.0/>)

1. Introduction

Dentigerous cyst is commonest developmental odontogenic cyst and has a incidence rate between 20% and 24% among all the jaw cysts.¹ It is associated with the crowns of unerupted tooth or developing tooth bud, and is normally attached to the cervical margins of affected tooth. If the size of the cyst is larger than 2 cm in diameter then it may cause swelling, tooth mobility, tooth displacement and sensitivity.² Although permanent third molars are generally associated with this cyst but association with mandibular incisors are rarely seen. Predilection for males are reported and generally occurred in second or third decade of life.³

Dentigerous cyst are of two types: developmental and inflammatory. Developmental type is derived from reduced enamel epithelium, by accumulation of fluid between reduced enamel epithelium and enamel. Inflammatory type is developed, as a result from periapical infection in its Predecessor deciduous tooth, which spread upto permanent

tooth-bud.⁴ Dentigerous cysts are always associated with a missing tooth or failure of tooth eruption, and may be asymptomatic until they become enlarged enough.⁴

2. Case Report

A 28 year old male patient presented with painless swelling in mandibular right anterior region for last six months with a chief complaint of tooth present on lingual region. On general examination, patient was apparently well and did not give history of any systemic disease. On extra-oral examination, no deformity is seen. On intra-oral examination, Mandibular right lateral incisor was present lingually. On palpation, a swelling was felt in relation to this tooth (Figure 1).

We advised a panoramic radiograph, which revealed a single, unilocular, well-defined, radiolucent area enclosing the mandibular right lateral incisor (Figure 2).

CBCT was also performed for further evaluation of the content and the extent of the cyst and it showed a well-defined, expansile, radiolucency noted in anterior

* Corresponding author.

E-mail address: drstomar@yahoo.com (S. Tomar).

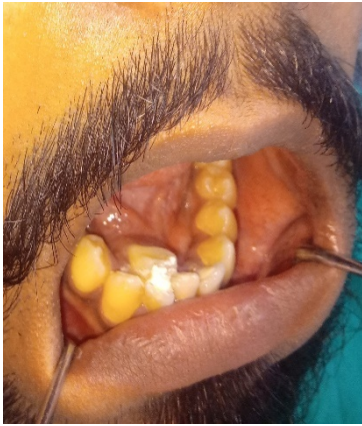

Fig. 1:

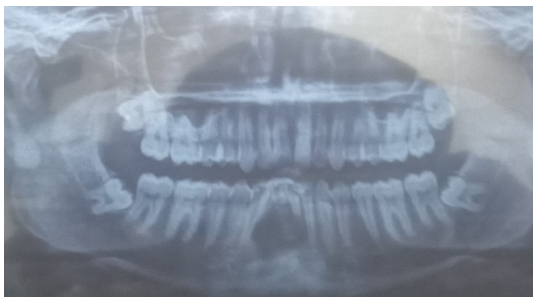

Fig. 2:




Fig. 4:

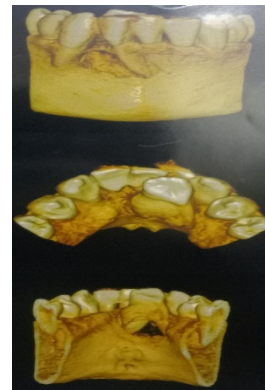


Fig. 5:

mandible region, extending from the mesial aspect of #32 region, crossing the midline, upto the mesial aspect of #43 region mesio-distally, and from the crest of the alveolus in #42 region. The lesion was 19.3 mm in height x 16.6 mm in mesio-distal width x 14.8 mm in labio-lingual in dimensions.

The lesion appeared to be associated with a lingually impacted tooth like structure in relation to #42 region. Coronally this structure resembles the mandibular lateral incisor. Internally, it showed a radiolucent invagination, lined by enamel. Marked internal resorption and expansion of root was also noted (Figures 3, 4 and 5).

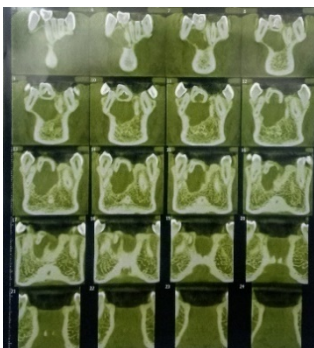

Fig. 3:

On the basis of radiographic and clinical findings, a provisional diagnosis of inflammatory dentigerous cyst was made. So a surgical enucleation was planned and routine blood-investigations were advised. The results of routine blood examinations were normal.

The flap was raised and the cyst was enucleated together with the retained tooth #42. Haemostasis was achieved and sutures were given to approximate the defect (Figures 6, 7, 8 and 9). Analgesics and antibiotics were prescribed and asked the patient for monthly follow-up.

The specimen was sent for histopathological examination, which showed a cyst wall lined by densely inflamed connective tissue surrounded by skeletal muscle. The epithelium was completely eroded. The inflammatory cells consist of lymphocytes, plasma cells, occasional few foamy macrophages. Although no atypia was present.

Histo-pathological examinations confirmed the provisional diagnosis of -'Inflammatory Dentigerous Cyst'.

Patient was recalled for regular follow-up and there was no recurrence observed after one year follow up.

3. Discussion

Dentigerous cyst accounts for more than 24% of jaw cysts and it is the most common developmental cyst of

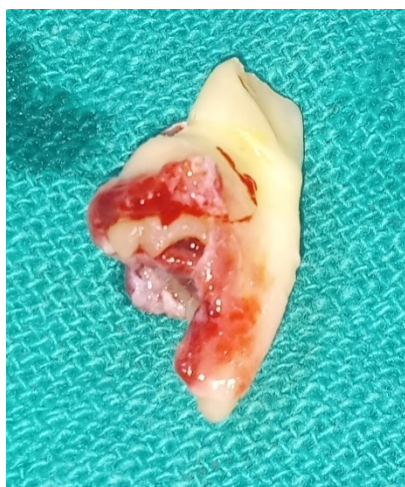

Fig. 9:

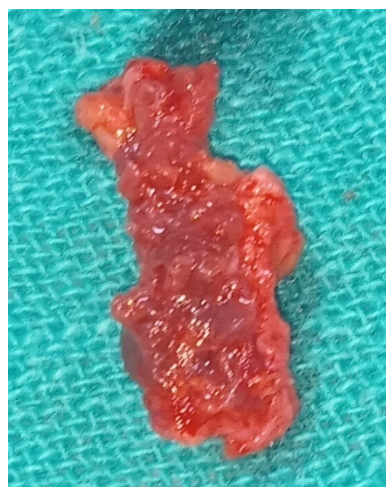

Fig. 8:

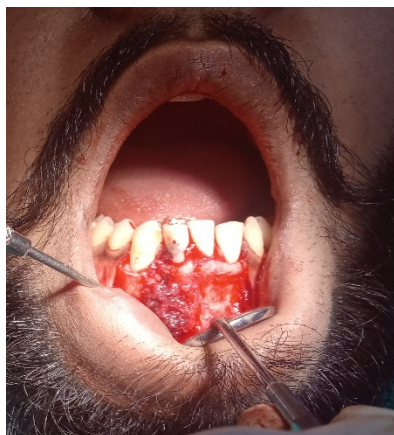

Fig. 6:

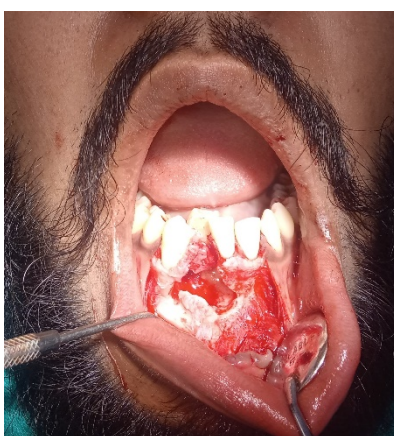

Fig. 7:

oral region. The dentigerous cyst occurs most commonly in second and third decade of life. Dentigerous cyst can be defined, which encloses the crown of an unerupted tooth and is attached at the cemento-enamel junction. Generally, impacted tooth may undergo dentigerous cyst transformation. So, in this case, the dentigerous cyst involving permanent lateral incisor is rare. The treatment options of a dentigerous cyst should be based on the size of the cyst, age of patient, location of the cyst, dentition affected, and relationship with the surrounding structures [Motamedi and Talesh, 2005].⁵ In this case, there are two treatment options: complete enucleation and marsupialization. Sometimes if dentigerous cysts left untreated, rarely but have potential to develop odontogenic tumor like ameloblastoma and malignancy like oral squamous cell carcinoma and mucoepidermoid carcinoma. If these cysts are associated with anterior teeth, it may cause failure of tooth eruption resulting in esthetic and orthodontic problems. Regular follow-ups are still necessary to evaluate healing of the cyst.

4. Conclusion

Inflammatory dentigerous cysts can occur in conjunction with impacted posterior teeth as well as anterior teeth also. Considering complications of a dentigerous cyst, early diagnosis is essential to prevent extensive treatment. After treatment, patients should be instructed to follow regular visits and radiographic follow-ups.

5. Source of Funding

Nil.

6. Conflicts of interest

There are no conflicts of interest.

References

1. Demiriz L, Misir AF, Gorur DI. Dentigerous cyst in a young child. *Eur J Dent.* 2015;09(04):599–602.
2. Kirtaniya BC, Sachdev V, Singla A, Sharma AK. Marsupialization: A conservative approach for treating dentigerous cyst in children in the mixed dentition. *J Indian Soc Pedodont Prev Dent.* 2010;28(3):203–8.
3. Desai RS, Vanaki SS, Puranik RS, Tegganamani AS. Dentigerous cyst associated with permanent central incisor: A rare entity. *J Indian Soc Pedodont Prev Dent.* 2005;23(1):49–50.
4. Yao L, Xu X, Ren M. Inflammatory dentigerous cyst of mandibular first premolar associated with endodontically treated primary first molar: a rare case report. *Euro J Paedia Dent.* 2015;16(3):201–4.
5. Motamedi MHK, Talesh KT. Management of extensive dentigerous cysts. *Br Dent J.* 2005;198(4):203–6.

Author biography

Sanjeev Tomar Senior Lecturer

Upma Tomar PG Student

Cite this article: Tomar S, Tomar U. Case report on dentigerous cyst in relation to permanent mandibular lateral incisor: A rare entity. *Santosh Univ J Health Sci* 2020;6(1):70-73.