



Original Research Article

Diagnostic accuracy of hysterosalpingography in comparison to laparoscopy to detect tubal occlusion in female infertility: An observational study

Subrata Das^{1,*}, Ajit R Bhattacharyya²

¹Dept. of Obstetrics & Gynaecology, ESI PGI MSR & ESIC Medical College and ESIC Hospital & ODC (EZ), Kolkata, West Bengal, India

²Dept. of Obstetrics & Gynaecology, R G Kar Medical College and Hospital, Kolkata, West Bengal, India



ARTICLE INFO

Article history:

Received 07-08-2020

Accepted 03-09-2020

Available online 29-12-2020

Keywords:

Infertility

Hysterosalpingography

Laparoscopy

Chromoperturbation

ABSTRACT

Background: An accurate diagnosis of tubal occlusion is a crucial part of infertility management of women for which Hysterosalpingography is an integral part for this purpose.

Objective: The study is designed to find out tubal occlusion by hysterosalpingography (HSG) and comparing the findings with diagnostic laparoscopy with chromoperturbation (laparoscopy) by determining validity and agreement of findings in the study group.

Materials and Methods: In this observational study, one hundred and ninety-seven women with infertility were recruited from an infertility clinic of a tertiary care hospital of West Bengal, in between April 2018 and March 2020, i.e. 24 months' period. Women, who were exposed to both of the investigations i.e. HSG and laparoscopy tests, were our study subjects. HSG findings were compared with the findings of laparoscopy to detect tubal occlusion by analyzing sensitivity, specificity, positive predictive value, negative predictive value and kappa.

Results: We found mean age of women with primary infertility (66%) was 27.23 years and with secondary infertility (34%) was 32.02 years. The sensitivity, specificity, positive predictive value, negative predictive value and accuracy of HSG in comparison to laparoscopy to detect tubal occlusion were 80.85%, 74%, 49.35%, 92.5% and 75.63% respectively. Findings showed statistically significant ($p < 0.05$) detection of tubal occlusion by HSG in comparison to findings of laparoscopy. Here tubal factor denotes any form of tubal obstruction i.e. unilateral or bilateral.

Conclusion: This study provides strong supportive evidence to utilise HSG as a screening test for diagnosing tubal occlusion in infertility work up with high accuracy, especially in low resourceful area of rural India.

© This is an open access article distributed under the terms of the Creative Commons Attribution License (<https://creativecommons.org/licenses/by/4.0/>) which permits unrestricted use, distribution, and reproduction in any medium, provided the original author and source are credited.

1. Introduction

Infertility is a disease of couples due to failure to achieve clinical pregnancy even after 12 months of regular unprotected intercourse.¹ It may be primary or secondary. In primary infertility clinical pregnancy was never documented and secondary infertility refer to a couple where there was documented clinical pregnancy but failed to conceive subsequently.

In the last decade, increasing trend of infertility^{2,3} was seen in global population,⁴ almost 10-15% couple^{4,5} needed infertility related advice. Increased trends of infertility mostly due to delayed marriage with delayed child bearing, increased prevalence of sexually transmitted disease and preponderance of pelvic endometriosis.

Other than anovulation, tubal factor is the major contributing factor (20-30%)³ for female infertility.^{2,6} Hysterosalpingography (HSG) was used as a screening test to detect infertility from tubal occlusion.⁵ The test is noninvasive, economical and less expertise is needed

* Corresponding author.

E-mail address: drsubrata02@gmail.com (S. Das).

but with the risk of exposure of patients to radiation and iodinated contrast medium. It is an outpatient department procedure;⁷ patients are less relaxed as sedation or anesthesia is not used during the procedure. Presence of ‘cornual spasm’ at the level of interstitial part of tube sometimes is evident as tubal occlusion, which could lead to false positive result.⁸

Laparoscopic chromopertubation is a gold standard test for confirmation of tubal blockage.^{3,8} Laparoscopy was carried out in cases of tubal occlusion detected by HSG and/or where patients failed to conceive even after reasonable period of six months wait following tubal patency confirmed by HSG. But laparoscopy is invasive, costly, associated with surgical risk and training required to perform and interpret. Hence, objective of our study to analyze validity and relation of findings of hysteroscopy with reference standard test e.g. laparoscopy⁹ is to detect tubal occlusions in women with infertility.

2. Materials and Methods

It is a retrospective observational study performed from April 2018 to March 2020. A total of one hundred and ninety-seven women who have infertility were enrolled from an infertility clinic of a tertiary care hospital. The Institutional Ethics Committee approved the study, and the study was performed in accordance with its recommendations and that of Helsinki Declaration of 1975 that was revised in 2000. All women participating in this study gave a written informed consent.

2.1. Inclusion criteria

Women in between 21 and 40 years’ age with either primary or secondary infertility and who were subjected to both investigation i.e. hysterosalpingography (HSG) and laparoscopy were selected for study. Every woman underwent detailed examination and investigations to detect the cause of infertility. Women with normal hormone profile i.e. thyroid stimulating hormone (TSH), follicle stimulating hormone (FSH) and anti-mullerian hormone (AMH) and normal semen analysis of husband were included as a study subject.

2.2. Exclusion criteria

Prior history of ectopic pregnancy, pelvic inflammatory disease or history of pelvic endometriosis or uterine anomalies were excluded from the study. Women who had uterine myoma of more than 5 cm or non-functional ovarian cyst, detected by pelvic ultrasonography during infertility work up, were also excluded from study. (Figure 1)

In this study, one hundred and ninety-seven women were evaluated by hysteroscopy and followed by laparoscopy. Hysterosalpingography was done in the proliferative phase in between 7th and 10th day of menstruation

in the department of radiology. Pregnancy test was performed in patients with grossly irregular menstrual cycle or amenorrhea before the procedures and such tests resulted in negative test result. Hysterosalpingography was performed in dorsal lithotomy position after taking antiseptic precautions. Water soluble radio opaque dye was introduced after holding cervix with tenaculum and cannula introduced just beyond the internal os. Under fluoroscopic guidance anterior-posterior skiagrams were obtained during the phase of uterine cavity filling and subsequently to watch for the tubal patency, tubal lumen and free spillage within the peritoneal cavity. Delayed skiagram was also obtained. Presence of spillage in peritoneal cavity on either or both sides, denotes as patent fallopian tube. Absence of spillage and presence of obstruction within uterine cavity or irrespective of site of obstruction within the fallopian tube was recorded as tubal block on respective sides. But for the purpose of study it is grouped as unilateral and bilateral tubal obstruction or patent tube. Any space occupying lesion detected within the uterine cavity or ballooning of tube due to hydro salpinx was recorded for treatment purpose but was not included as it was beyond the scope of the study.

Laparoscopy with chromopertubation was done on those women who did not conceive within six months after Hysterosalpingography or unilateral or bilateral tubal block was detected in Hysterosalpingography, were included in the study.

After pre-operative evaluation, patients were put under general anesthesia at operation theatre. A small 2-3 cm incision at supra umbilical and another 2 cm incision at right or left side of lower abdomen were given for introduction of 10 mm laparoscope and hand instrument respectively. Diluted Methylene blue solution of 15 ml was introduced slowly through cervix after placement of cannula beyond internal os. The Passage of blue coloured solution of methylene blue from the fimbriae end of fallopian tube was marked as patent fallopian tube. In absence of passage of Methylene blue solution in one or both tubal end was denoted as unilateral or bilateral tubal block. During laparoscopy, presence of endometriosis, peritubal adhesion and distorted pelvic anatomy was seen in few patients and documented for treatment purpose but such data was not included as it was beyond our scope of study.

Following prognostic factors, we considered during collection of data i.e. age and type of subfertility (i.e. Primary or secondary). We followed the guideline that was reported by Deville WL et al¹⁰ in their diagnostic trial of meta-analysis. Here we considered two outcomes by hysterosalpingography and by laparoscopy, i.e. unilateral and bilateral occlusion of tube as a single group of tubal occlusion is considered as positive findings and patency found in both the is tube considered as negative finding. Test error was defined whenever hysterosalpingography detect tubal occlusion (i.e. positive finding) but patency of

both tube (i.e. negative finding) was found by reference standard test i.e. laparoscopy, was considered as false negative result. False positive results were cases in which the hysterosalpingography results were positive for tubal occlusion but in the reference standard test (laparoscopy) result showed patency of both tube present (negative result).

For considering tubal obstruction of both i.e. unilateral and bilateral obstruction in a single group, we compared the group with patency of tube in between hysterosalpingography and Laparoscopic findings. Here we used two by two table for calculating sensitivity, specificity, positive predictive value and negative predictive value and accuracy. To compare the findings of hysterosalpingography with laparoscopy, 2x2 table was constructed and findings were measured at 95% confidence level and Pearson's Chi-Squared test was used to see the significance level where $p < 0.05$. For descriptive statistics and student T test was used for parametric data and Pearson's Chi-Squared test was used to measure for non-parametric data. For statistical analysis we used IBM SPSS v24 software.

3. Results

Out of one hundred and ninety-seven women with Infertility, one hundred thirties were presented with primary infertility and sixty-seven were presented with secondary infertility.

According to age both types of infertility were divided into four group of ages i.e. 21-25 years, 26-30 years, 31-35 years and 36-40 years. The age group of 21-25 years was the most common age group of presentation of primary infertility with mean age of 27.23 ± 4.26 years. The most common age of presentation for secondary infertility was 31-35 years with mean age of 32.03 ± 4.17 years. (Table 1)

The age distribution according to findings of hysterosalpingography and laparoscopy were found significant (p value < 0.05). (Tables 2 and 3)

Patent tube was found in one hundred and eleven women by both hysterosalpingography and laparoscopy (Table 4 Figure 2).

In hysterosalpingography findings, all types of tubal blockage were compared with findings of laparoscopy. Here tubal block was defined as both unilateral and bilateral tubal occlusions. In the analysis of study over all sensitivity, specificity, positive predictive value, negative predictive value and accuracy were 80.85%, 74%, 49.35%, 92.5% and 75.63% respectively and findings were significant (i.e. p value < 0.05). The weighted k-statistic was 0.45 (95% CI 0.32-0.57), which indicate moderate agreement beyond chance between the test result of Hysterosalpingography and laparoscopy. We found that the likelihood ratio of Hysterosalpingography for positive test result to detect tubal occlusion was 3.11 (95% CI 2.30 to 4.21) and negative likelihood ratio for negative test result was 0.26 (95% CI 0.14 to 0.47).

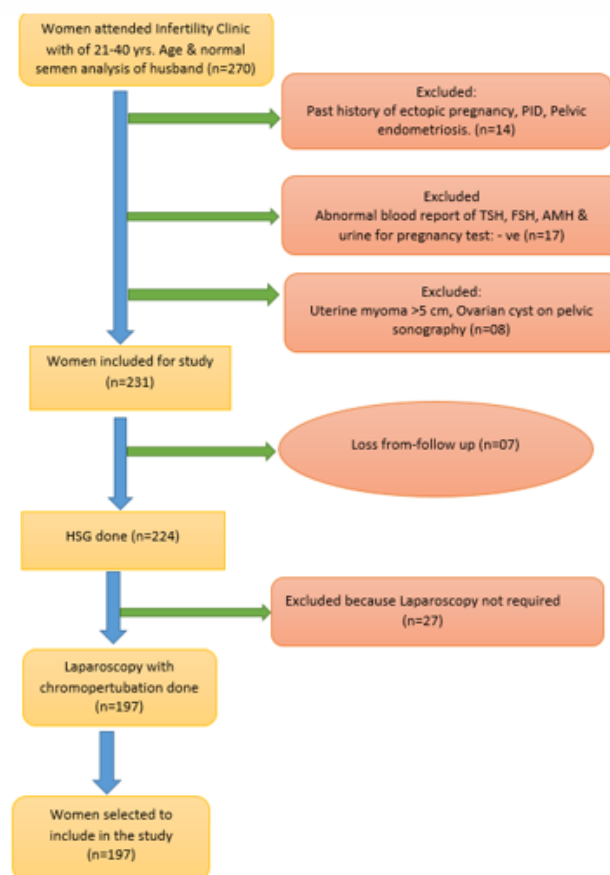


Fig. 1: Flow chart of cases included in the study.

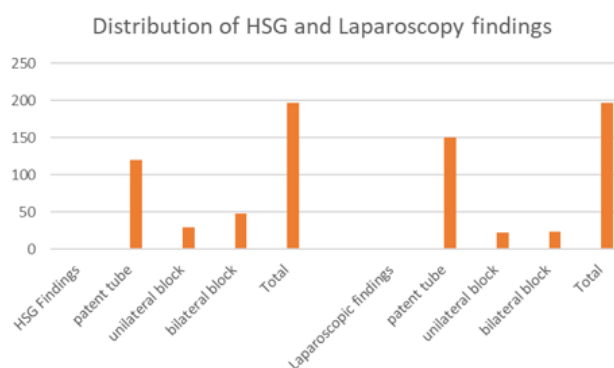


Fig. 2: Distribution of HSG and Laparoscopy findings.

Table 1: Distribution of women according to infertility type and age

Age groups	Primary Infertility			Secondary Infertility		
	No.	Percentage	Mean age	No.	Percentage	Mean±SD
21-25	63	32		4	2	
26-30	35	17.8		22	11.2	
31-35	21	10.6	27.23±4.26	24	12.2	32.03±4.17
36-40	11	5.6		17	8.6	
Total (n=197)	130	66		67	34	

Table 2: Distribution of women according to HSG test and Age group

HSG (Screening Diagnosis)	Patent Blocked (Unilateral + bilateral)	Age				Total
		21-25yrs	26-30yrs	31-35yrs	36-40yrs	
	Patent	49	33	23	15	120
	Blocked (Unilateral + bilateral)	18	24	22	13	77
	Total	67	57	45	28	197

$\chi^2 = 5.3769$, $df=1$, $p=0.0204$

Table 3: Distribution of women according to Laparoscopy and Age group

HSG (Screening Diagnosis)	Patent Blocked (Unilateral + bilateral)	Age				Total
		21-25yrs	26-30yrs	31-35yrs	36-40yrs	
	Patent	64	39	26	21	150
	Blocked (Unilateral + bilateral)	3	18	19	7	47
	Total	67	57	45	28	197

$\chi^2 = 12.0906$, $df=1$, $p= 0.0005$

Table 4: Tubal factor detected by HSG was compared to the tubal factor detected by Laparoscopy

Tubal status at HSG and Laparoscopy	No. of women with infertility
HSG patent, Laparoscopy patent	111
HSG unilateral block, Laparoscopy patent	18
HSG bilateral block, Laparoscopy patent	21
HSG patent, Laparoscopy unilateral block	6
HSG Unilateral block, Laparoscopy Unilateral block	7
HSG Bilateral block, Laparoscopy unilateral block	10
HSG Patent, Laparoscopy bilateral block	3
HSG Unilateral block, Laparoscopy bilateral block	4
HSG bilateral block, Laparoscopy bilateral block	17
Total patient (N)	197

Table 5: Accuracy of HSG in predicting Tubal factors of Infertility

HSG Findings of Fallopian tubes	Laparoscopy Findings of Fallopian tubes			Validity of HSG to diagnose Infertility from Tubal factor				
	Tubal block (Unilateral and bilateral)	Patent Tube	Total	Sensitivity	Specificity	Positive predictive value	Negative predictive value	Accuracy
Tubal block (Unilateral and bilateral)	38	39	77	80.85%	74%	49.35%	92.5%	75.63%
Patent Tube	9	111	120					
Total	47	150	197					

$\chi^2 = 10.564$, $df=1$, $p=0.0012$

Table 6: Comparison of findings of present study with study of others authors.

Principle Author	Year	Size of Sample	Types of Infertility	
			Primary	Secondary
Moghissi KS et al. ¹¹	1975	132	66%	34%
Ikechebelu JI et al. ¹²	2010	57	52.63%	47.37%
Khetmalas et al. ⁸	2016	114	58.8%	41.2%
Singh S. et al. ¹³	2019	100	68%	32%
In our study	2020	197	66%	34%

Table 7: Comparison of HSG finding of present study with the study by other authors.

Principle Author	Year	Sample size	HSG			
			Sensitivity	Specificity	PPV	NPV
Sakar MN et al. ¹⁴	2008	82	63%	89.3%	92%	55%
Gandotra et al. ¹⁵	2015	30	90.91%	77.78%	83.33%	87.50%
Rizvi SM et al. ²	2016	60	90.1	77.78	83.33	87.50
In our study	2020	197	80.85%	74%	49.35%	92.5%

4. Discussion

In this observational study, it was found that both investigations i.e. Hysterosalpingography and diagnostic laparoscopy could diagnose tubal occlusion effectively. But hysterosalpingography is less costly, devoid of any major risk and can be incorporated with other investigations of infertility in outdoor settings and is also free from surgical and anesthetic risks. Laparoscopy has higher degree of specificity and is considered as reference standard to confirm the diagnosis of tubal occlusion in the women with infertility.

As an investigator, we compared our study with the studies of other authors. In our study primary and secondary infertility were 66% and 34% respectably. Similar finding was found in the study performed by Moghissi KS et al.¹¹ and Singh S. et al.¹³ Their sample size was one hundred and thirty-two and one hundred respectively i.e. A little smaller than our sample size. (Table 6)

The study by Choudhary A et al.¹⁶ had reported that 26-30 years was the most common presenting age (38%) with mean age were 28.40 ± 6.73 at their study, and in our study mean age of primary and secondary infertility were 27.23 ± 4.26 and 32.03 ± 4.17 respectively.

In our study, most of the women (32%) was from 21-25 years. The most commonly (32%) affected age of primary infertility was 21-25 years. The women with secondary infertility was most common (12.2%) in 31-35 years' age followed by 11.2%, 8.6% and 2% of women with secondary infertility were in 26-30 years, 36-40 years and 21-25 years' age respectably in the study. Our findings were very close to the reported study of Choudhary A et al.⁵

The sensitivity, specificity, positive predictive value and negative predictive value were 80.85%, 74%, 49.35% and 92.5% respectably in the study to detect tubal

occlusion by hysterosalpingography. The compared findings were significant (i.e. p value <.05) to detect tubal occlusion by hysterosalpingography. Our findings of hysterosalpingography were compared with laparoscopic findings by Rizvi SM et al.² and Gandotra et al.¹⁵

Rizvi SM et al.² and Gandotra et al.¹⁵ in their study sensitivity, specificity, positive predictive value (PPV) and negative predictive value (NPV) reported as 90.1%, 77.78%, 83.33%, 87.50% and 90.91%, 77.78%, 83.33%, 87.50% respectively. The positive likelihood ratio for positive test was 3.11(95% CI 2.30-4.21) and negative likelihood ratio for negative test was 0.26 (95% CI 0.14-0.47). In my study sensitivity of hysterosalpingography was less, which might be due to stringent criteria adopted by radiologist and bigger sample size, but the other values were quite similar to our study. (Table 7)

In our study weighted k-static was 0.45 (95% CI 0.32-0.57), indicating moderate agreement beyond chances between hysterosalpingography and laparoscopy. In a similar study conducted by Mol BJM⁹ et al found weighted k-static value was 0.42 (95% CI 0.37-0.48), showed moderate agreement between hysterosalpingography and laparoscopy beyond chances. Their finding was closely similar with our findings. Study reported by Goynumer G. et al¹⁷ found sensitivity, specificity, positive predictive value, negative predictive value, positive likelihood ratio and negative likelihood ratio of hysterosalpingography were 0.80, 0.75, 0.91, 0.55, 3.21 and 0.26 respectively at 95% confidence level.

From hysterosalpingography and laparoscopy investigations, we tried to know the tubal occlusion of women with infertility. Some other additional important results may be gained from these diagnostic investigations, that was relevant to know the other aetiological factor

of infertility, but we did not tabulate such findings here, as it was beyond the scope of our study. Laparoscopy is an accurate predictor of intra-abdominal pathologies i.e. peritubular adhesions, endometriosis¹⁴ and pelvic inflammatory disease which cannot be detected by using hysterosalpingography alone. On the other side hysterosalpingography is more appropriate to detect intra uterine anatomy and intra luminal pathology, specially in low resource areas and rural population.

Limitation of our study includes, possibility of inter-observer variability of hysterosalpingography results, as more than one radiologist interpreted. The time gap of six months between hysterosalpingography and laparoscopy may have contributed some bias also. Reporting was not real-time hysterosalpingography and not observing dynamic nature of gradual filling and spillage of tube by radiopaque medium but was interpreted as time-shot from skiagram.

It can be concluded, that although there was some constrains in our study but reliability of hysterosalpingography as screening test has seen proved from our analysis. An inference can be drawn that hysterosalpingography can be a suitable alternative to reference standard test laparoscopy in the investigations for evaluation of infertility.

5. Conclusion

It can be concluded that hysterosalpingography is non-invasive, economical with high degree of sensitivity and can be incorporated as screening test during involution of infertility. Due to low specificity of hysterosalpingography, laparoscopy is needed for confirmation of tubal occlusion. Hysterosalpingography detect intraluminal disease and laparoscopy detect extra-luminal disease by the direct vision into pelvis. Both findings are required for appropriate therapy formulation. Hysterosalpingography and laparoscopy can be considered as complementary to one another rather than substitute.

6. Authors' contributions

The author exclusively contributed this work and have read and approved the final manuscript.

7. Source of Funding

No financial support was received for the work within this manuscript.

8. Conflict of Interest

The authors declare they have no conflict of interest.

References

- Gharekhanloo F, Rastegar F. Comparison of hysterosalpingography and laparoscopy in evaluation of female infertility. *Med Res Arch* . 2017;5(6):1–12. doi:10.18103/mra.v5i6.1297.
- Rizvi SM, Ajaz S, Gulshan G, Nikita N, Anjum S. Comparison of Hysterosalpingography and Laparoscopy in Diagnosis of Tubal Occlusion. *Ann Int Med Dent Res*. 2016;2(4):165–8. doi:10.21276/aimdr.2016.2.4.43.
- Jain P, Bansal D, Deodhar P. Re-emerging role of HSG Vs laparoscopy for infertility work -up at rural hospital set up. *J Res Med Dent Sci*. 2015;3(4):287–9. doi:10.5455/jrmds.2015349.
- Anuradha J, Arunakumari K, Sujatha A. Comparative study of tubal patency by hysterosalpingography, transvaginal sonosalpingography and laparoscopy. *Int Arch Integr Med*. 2016;3:126–9.
- Choudhary A, Tiwari S. Comparison between hysterosalpingography and laparoscopic chromopertubation for the assessment of tubal patency in infertile women. *Int J Reprod Contracept Obstet Gynecol* . 2017;6(11):4825–9. doi:10.18203/2320-1770.ijrcog20174626.
- Nahar S, Jahan D, Akter N, Das B. Laparoscopic evaluation of tuboperitoneal causes of infertility. *Bangladesh Med J Khulna*. 2014;46(1-2):16–20. doi:10.3329/bmj.v46i1-2.18234.
- Nigam A, Saxena P, Mishra A. Comparison of hysterosalpingography and combined laparohysteroscopy for the evaluation of primary infertility. *Kathmandu Univ Med J*. 2015;13:281–5.
- Khetmalas SM, Kathaley MH. A Study Evaluation of Tubal Factors of Infertility by Hysterosalpingography and Diagnostic Laparoscopy. *MVP J Med Sci*. 2016;3(1):11–7. doi:10.18311/mvpjms/2016/v3/i1/722.
- Mol BWJ, Collins JA, Burrows EA, Veen FCD, Bossuyt PMM. Comparison of hysterosalpingography and laparoscopy in predicting fertility outcome. *Hum Rep*. 1999;14:1237–42.
- Devillé WL, Buntinx F, Bouter LM, Montori VM, de Vet HC, van der Windt D, et al. Conducting systematic reviews of diagnostic studies: didactic guidelines. *BMC Med Res Methodol*. 2002;2(9):13. doi:10.1186/1471-2288-2-9.
- Moghissi KS, Sim GS. Correlation between Hysterosalpingography and Pelvic Endoscopy for the Evaluation of Tubal Factor**Presented at the Thirty-First Annual Meeting of The American Fertility Society, April 3 to 5, 1975, Los Angeles, Calif. *Fertil Steril* . 1975;26(12):1178–81. doi:10.1016/s0015-0282(16)41531-1.
- Ikechibelu JI, Eke NO, Eleje GU, Umeobika J. Comparison of the diagnostic accuracy of laparoscopy with dye test and hysterosalpingography in the evaluation of infertile women in Nnewi, Negeria. . *Trop J Laparoendosc*. 2010;1(1):39–44.
- Singh S, Das L, Das, Das S, Das PC. Combined diagnostic approach of HSG and diagnostic hysterosalpingography in evaluation of female Infertility. *Int J Adv Res*. 2019;7:623–30.
- Sakar MN, Gul T, Atay AE, Celik Y. Comparison of Hysterosalpingography and laparoscopy in the evaluation of infertile women. *Saudi Med J*. 2008;29:1315–8.
- Gandotra N, Sharma A, Rizvi SM. Comparison of Laparoscopy and Hysterosalpingography in Diagnosis of Tubal Occlusion. *J Med Sci Clin Res*. 2015;3(10):7985–9. doi:10.18535/jmscr/v3i10.46.
- Dubbewar A, Nath SK. Observational study of HSG with laparoscopic correlation in infertility patients. *Int J Reprod Contracept Obstet Gynecol*. 2018;7(5):1903–7. doi:10.18203/2320-1770.ijrcog20181926.
- Goynumer G, Yetim G, Gokcen O, Karaaslan I, Wetherilt L, Durukan B. *World J of Laparosc Surg*. 2008;1:23–29.

Author biography

Subrata Das, Associate Professor

Ajit R Bhattacharyya, Professor

Cite this article: Das S, Bhattacharyya AR. Diagnostic accuracy of hysterosalpingography in comparison to laparoscopy to detect tubal occlusion in female infertility: An observational study. *Panacea J Med Sci* 2020;10(3):276-281.