



Original Research Article

Patient demographics, causes, presentations and surgical management in chronic subdural haematoma patients

Bhavuk Kapoor¹, Mayank Kapoor², Parul Vaid^{3,*}, Sharda Kapoor⁴, Bharat B Kapoor⁵¹Dept. of Neurosurgery, Government Medical College and hospital, Jammu, Jammu and Kashmir, India²Dept. of Medicine, All India Institute of Medical Sciences, Rishikesh, Uttarakhand, India³Dept. of Obstetrics and Gynaecology, Shri Maharaja Gulab Singh Hospital, Jammu, Jammu and Kashmir, India⁴RBSK Jammu Division, Jammu and Kashmir, India⁵Dept. of Anaesthesia and ICU, Government Medical College, Jammu, Jammu and Kashmir, India

ARTICLE INFO

Article history:

Received 27-10-2020

Accepted 14-12-2020

Available online 29-04-2021

Keywords:

Chronic subdural haematoma

Causes

Patients demography

Clinical presentation

ABSTRACT

Background: Chronic SDH usually affects the elderly population. The common symptoms in chronic SDH patients are headache, altered sensorium, memory loss, weakness and lethargy. Timely surgical intervention is advisable wherever indicated.

Aims: To interpret the patient demographics, causes, presentations and surgical management in chronic subdural haematoma patients.

Settings and Design: Patients were analysed as per their demographic characteristics, clinical features and surgical management done.

Materials and Methods: Fifty patients of chronic SDH were analysed.

Statistical analysis: Statistical evaluation was done

Results: Most of the patients were in the 7th and 8th decade of life. Patients in our study were mostly of the urban areas (60%) than rural areas (40%). 66% of patients were males and 34% of patients were females. Trauma (52%) was most common cause for Chronic SDH formation. Headache was the most common (89%) presenting symptom in our study. Altered sensorium was the next common presentation. Most of the patients (76%) had GCS score of 13-15 at presentation. Burr hole evacuation was the preferred surgical treatment modality (90%).

Conclusion: Chronic SDH is a common neurosurgical entity mostly seen in elderly. Patients from urban areas have higher occurrence of Chronic SDH due to better diagnostic and health facilities. Headache is the one of the most common presenting symptom and trauma being one of the most common causes for its occurrence. Whenever in doubt especially in elderly CT scan head can be considered to rule out its occurrence. Burr hole evacuation is the preferred surgical treatment modality in most of the cases. Timely surgical intervention is advisable wherever indicated.

© This is an open access article distributed under the terms of the Creative Commons Attribution License (<https://creativecommons.org/licenses/by/4.0/>) which permits unrestricted use, distribution, and reproduction in any medium, provided the original author and source are credited.

1. Introduction

Chronic subdural hematoma is a common diagnosis among neurosurgery patients. Timely treatment is required, otherwise it may become fatal.

Elderly population is usually affected. Upto 90% of chronic subdural haematoma patients are elderly.¹

* Corresponding author.

E-mail address: kapoorbhavuk14@gmail.com (P. Vaid).

Trauma is the most common etiological factor for its occurrence with falls and motor vehicle accidents being the most common causes.²

It has also been suggested that CSDH is an isolated contributor to recurrent falls because of an altered mental state and neurological deficits.³

Brain contraction in elderly is also thought to be a contributing factor. In atrophied elderly brain there occurs increased tension on bridging vessels which then can easily

tear during minor trauma.⁴

The common symptoms in chronic SDH patients are headache, altered sensorium, memory loss, weakness and lethargy.

CT scan of head is the investigation of choice for its diagnosis.

Some cases of chronic SDH will resolve spontaneously. Medical management includes bed rest, mannitol but prolonged hospitalisation is usually required.

Surgical management is usually done for its management. Most commonly done procedure is burrholes evacuation with or without drainage. In some patients with membrane formation, small craniotomy or wide craniotomy with removal of the hematoma and membrane resection is warranted.⁵

2. Materials and Methods

Fifty patients were included in the study. Ct scan head was done in all the cases for diagnosing chronic SDH prior to surgery.

Patients were analysed as per their demographic characteristics, clinical features and surgical management done.

Statistical evaluation was done using SPSS software for windows.

3. Results

Most of the patients were in the 7th and 8th decade of life.

Unilateral Chronic SDH had a mean age of 59.47 years and bilateral chronic subdural haematoma had mean age of 75.6 years.

Patients in our study were mostly of the urban areas (60%) than rural areas (40%) [Table 1].

Table 1: Residence of patient

Residence	Frequency	Percentage (%)
Urban	30	60
Rural	20	40

66% of patients were males and 34% of patients were females.

Trauma (52%) was most common cause for Chronic SDH formation.

Headache was the most common (89%) presenting symptom in our study [Figure 1].

Altered sensorium was the next common presentation. Most of the patients (76%) had GCS score of 13-15 at presentation [Table 2].

Burr hole evacuation was the preferred surgical treatment modality (90%)

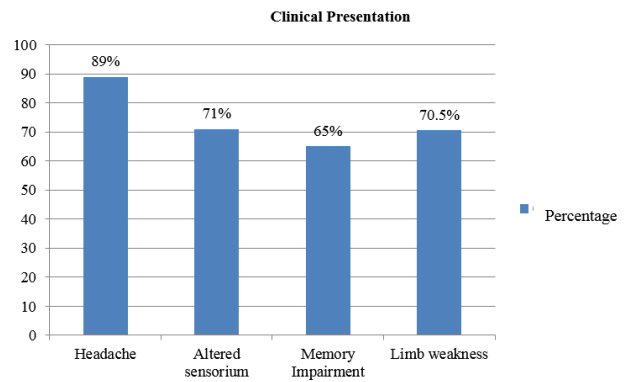


Fig. 1: Clinical Presentation of Chronic SDH

Table 2: GCS at admission

GCS at admission	Frequency	Percentage (%)
< 7	2	4
7-12	10	20
13-15	38	76

4. Discussion

Most of the patients were in the 7th and 8th decade of life. Kim G H et al found mean patient age 68.6 years.⁶ Ro HW et al. found mean age of 69 years in their study.⁷ These findings indicate that chronic subdural haematoma is common in elderly patients.

In our study, Unilateral Chronic SDH had a mean age of 59.47 years and bilateral chronic subdural haematoma had mean age of 75.6 years. In a study by Kitya et al., right side chronic subdural haematoma patients had mean age of 58.6 years, Left side chronic subdural haematoma patients had mean age of 59.4 years and bilateral chronic subdural haematoma patients had mean age of 66.9 years.⁸ So, in elderly patients with generalised brain atrophy, there is higher chance of bilateral chronic subdural haematoma occurrence.

Patients in our study were mostly of the urban areas (60%) than rural areas (40%). Urban preponderance is because of easy availability of CT scan and availability of specialist doctor in urban areas.

66% of patients were males and 34% of patients were females. Young-Joon Rho et al and Shameem A et al also found a predominance of male patient, 2.9 and 7.5 respectively to every female patient in Chronic SDH.^{9,10} Males are more in number as they are more prone to injuries.

Trauma was most common (52%) cause of chronic subdural haematoma formation in our study. Similar finding was observed in study by Mori K.¹¹ Rovlias et al. found traumatic brain injury in 51.01% of patients they studied.¹²

In some patients, there was no history of trauma or other etiological factor present. Chronic subdural haematoma might have developed in these patients as a delayed

complication of trivial trauma which went unnoticed.

Headache was the most common (89%) presenting symptom in our study.

These findings are in line with previous studies from Nigeria and Ghana.^{2,13}

Altered sensorium was the next common presentation. Most of the patients (76%) had GCS score of 13-15 at presentation in our study. In a study by Kitya et al., confusion as presenting symptom was present in 71.7% of patients and 66.2% of patients had GCS score of 13-15.⁸

In our study, burr hole drainage was the preferred surgical procedure (90%). In a study by H. Toi et al., 90.5% of the patients underwent burr hole drainage and irrigation.¹⁴

So, burr hole remains the procedure of choice for most of the cases of chronic SDH.

5. Conclusion

Chronic SDH is a common neurosurgical entity, mostly seen in elderly.

Patients from urban areas have higher occurrence of Chronic SDH due to better diagnostic and health facilities.

Headache is the one of the most common presenting symptom and trauma being one of the most common causes for its occurrence.

Whenever in doubt especially in elderly CT scan head can be considered to rule out its occurrence.

Burr hole evacuation is the preferred surgical treatment modality in most of the cases.

Timely surgical intervention is advisable wherever indicated.

6. Source of Funding

No financial support was received for the work within this manuscript.

7. Conflict of Interest

The authors declare they have no conflict of interest.

References

1. Kerabe S, Ozawa T, Watanabe T, Atoa T. Efficacy and safety of post-operative early mobilization for chronic subdural haematoma in elderly patients. *Acta Neurochir*. 2010;152:1171–4.
2. Mezue WC, Ohaebgulam SC, Chikani MC, Erechukwu AU. Changing trends in chronic subdural haematoma in Nigeria. *Afr J Med Med Sci*. 2011;40:373–6.
3. Adeolu AA, Rabiou TB, Adeleye AO. Post-operative day two versus day seven mobilization after burr-hole drainage of subacute and chronic subdural haematoma in Nigerians. *Br J Neurosurg*. 2012;26(5):743–6. doi:10.3109/02688697.2012.690912.
4. Adhiyaman V. Chronic subdural haematoma in the elderly. *Postgraduate Medical Journal*. 2002;78(916):71–75. Available from: <https://dx.doi.org/10.1136/pmj.78.916.71>. doi:10.1136/pmj.78.916.71.

5. Gelabert-González M, Iglesias-Pais M, García-Allut A, Martínez-Rumbo R. Chronic subdural haematoma: surgical treatment and outcome in 1000 cases. *Clin Neurol Neurosurg*. 2005;107(3):223–9. doi:10.1016/j.clineuro.2004.09.015.
6. Kim GH, Kim BT, Im SB, Hwang SC, Jeong JH, Shin DS, et al. Comparison of the Indications and Treatment Results of Burr-Hole Drainage at the Maximal Thickness Area versus Twist-Drill Craniostomy at the Pre-Coronal Point for the Evacuation of Symptomatic Chronic Subdural Hematomas. *J Korean Neurosurg Soc*. 2014;56(3):243–7.
7. Ro HW, Park SK, Jang DK, Yoon WS, Jang KS, Han YM, et al. Preoperative predictive factors for surgical and functional outcomes in chronic subdural hematoma. *Acta Neurochir (Wien)*. 2016;158:135–9.
8. Kitya D, Punchak M, Abdelgadir J, Obiga O, Harborne D, Haglund MM. Causes, clinical presentation, management, and outcomes of chronic subdural hematoma at Mbarara Regional Referral Hospital. *Neurosurg Focus*. 2018;45:7.
9. Young-Joon R, Choe WJ, Chun YI, Cho J, Moon CT, Chang SK, et al. Postoperative Lesion Side Down Posture in Patients with Chronic Subdural Hematoma: Its Impact on Hospital Stay and Recurrence Rate. *J Korean Neurotraumatol Soc*. 2011;7(2):99–102. doi:10.13004/jknts.2011.7.2.99.
10. Ahmed S, Agrawal D, Kale SS, Mahapatra AK. A comparative study of treatment of chronic subdural hematoma — burr hole drainage versus continuous closed drainage. *Indian J Neurotrauma*. 2011;8(1):17–24. doi:10.1016/s0973-0508(11)80019-5.
11. Mori K, Meda M. Surgical Treatment of Chronic Subdural Hematoma in 500 Consecutive Cases: Clinical Characteristics, Surgical Outcome, Complications, and Recurrence Rate. *Neurol Med Chir*. 2001;41(8):371–81. doi:10.2176/nmc.41.371.
12. Rovlias A, Theodoropoulos S, Papoutsakis D. Chronic subdural hematoma: Surgical management and outcome in 986 cases: A classification and regression tree approach. *Surg Neurol Int*. 2015;6(1):127. doi:10.4103/2152-7806.161788.
13. Dakurah TK, Idrissu M, Wepeba G, Nuamah I. Chronic subdural haematoma: review of 96 cases attending the Korle Bu Teaching Hospital, Accra. *West Afr J Med*. 2006;24(4):283–6. doi:10.4314/wajm.v24i4.28210.
14. Toi H, Kinoshita K, Hirai S, Takai H, Hara K, Matsushita N, et al. Present epidemiology of chronic subdural hematoma in Japan: analysis of 63,358 cases recorded in a national administrative database. *J Neurosurg*. 2018;128(1):222–8. doi:10.3171/2016.9.jns16623.

Author biography

Bhavuk Kapoor, Lecturer

Mayank Kapoor, Post Graduate

Parul Vaid, Senior Resident

Sharda Kapoor, Former Divisional Nodal Officer

Bharat B Kapoor, Former Professor and Head

Cite this article: Kapoor B, Kapoor M, Vaid P, Kapoor S, Kapoor BB. Patient demographics, causes, presentations and surgical management in chronic subdural haematoma patients. *Panacea J Med Sci* 2021;11(1):17-19.