



## Original Research Article

## To study ductal carcinoma breast with histopathological grades of Nottingham score

Pooja Agarwal<sup>1</sup>, Dupinder Kaur<sup>1,\*</sup><sup>1</sup>Dept. of Pathology,, Shri Ram Murti Smarak Institute of Medical Sciences, Bareilly, Uttar Pradesh, India

## ARTICLE INFO

## Article history:

Received 15-06-2020

Accepted 09-08-2020

Available online 29-04-2021

## Keywords:

Carcinoma Breast Histopathological &amp; Nottingham score

## ABSTRACT

**Background & Methods :** This case study was prospective and retrospective. Prospective cases were selected from the patients admitted for surgery of invasive ductal carcinoma breast in Medical College Hospital. As regards retrospective cases, they were obtained from the histopathological records obtained from Pathology department of SRMS-IMS, Bareilly.

**Result:** Out of 56 cases, 52 cases (92.85%) had undergone modified radical mastectomy under which whole breast tissue including axillary tail, nipple, surrounding skin were excised. In 2 cases (3.57%) radical mastectomy was done under which besides pectoralis muscles was also excised. In 2 cases (3.57%) core biopsies from breast were taken. The quick scoring of ER & PR is combination of proportion and intensity scoring. Out of 56 cases, 24 cases (42.85%) were ER negative & 22 cases (39.28%) were PR negative while both were negative in 18 cases (32.14%).

**Study Designed:** Observational Study

**Conclusion:** For all invasive carcinomas, hormone receptor status is also studied using immunoperoxidase method and Quick scoring was done. The Quick score for ER was 0 in 42.85% (24/56) cases and for PR was 0 in 39.28% (22/56) cases, indicating no hormone expression in majority.

© This is an open access article distributed under the terms of the Creative Commons Attribution License (<https://creativecommons.org/licenses/by/4.0/>) which permits unrestricted use, distribution, and reproduction in any medium, provided the original author and source are credited.

## 1. Introduction

Immunohistochemistry has a very important role in the assessment of prognostic and predictive factors in invasive breast cancer (IBC) today. Prognostic factors are defined as clinical, pathological & biological features associated with the innate aggressiveness of untreated invasive breast cancer and if adverse, usually result in the use of additional therapies following surgery.<sup>1</sup> Although a large number of potentially useful factors have been identified, only 3 are currently use in the clinical practice and their assessment is mandatory. These include estrogen receptor- $\alpha$  (ER- $\alpha$ ), the Progesterone receptor (PgR) & the HER-2/neu oncogene/onco protein. There is also a close correlation in breast carcinomas between the Ki-67 growth fraction and histopathological grades.<sup>2</sup>

It is a histological grading system for invasive duct carcinoma breast.<sup>3</sup> Percentage of tubule formation, nuclear pleomorphism and mitotic rate is each assigned 1, 2 or 3 points and scores added to grade tumor in grade I(score 3-5 well differentiated), grade II(6-7 moderately differentiated) and grade III (8-9 poorly differentiated).

HER-2/neu over expression is associated with poor prognosis and high grade of tumor, nodal metastasis and ER, PR negativity. The reduced hormone receptor expression might be one of the mechanisms by which HER-2/neu positive tumor show a decreased response to hormonal agents.<sup>4</sup>

## 2. Materials and Methods

The present study entitled “To Study ductal carcinoma breast with histopathological grades of Nottingham score” was conducted in Dept. of Pathology, at SRMSIMS, Bareilly.

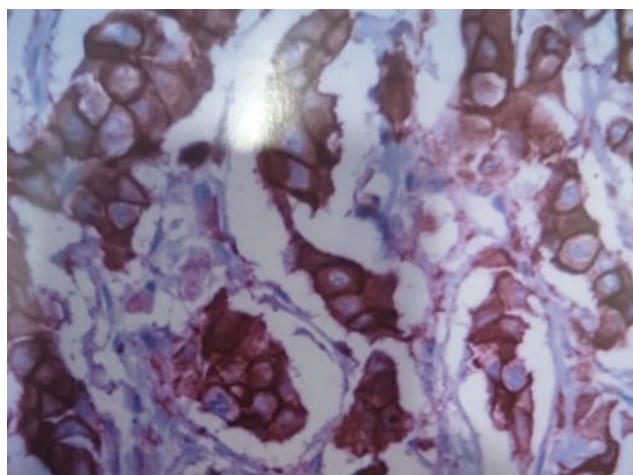
\* Corresponding author.

E-mail address: [dupindercaur@gmail.com](mailto:dupindercaur@gmail.com) (D. Kaur).

This case study was prospective and retrospective. Prospective cases were selected from the patients admitted for surgery of invasive ductal carcinoma breast in Medical College Hospital. As regards retrospective cases, they were obtained from the histopathological records obtained from Pathology department of SRMS-IMS, Bareilly.

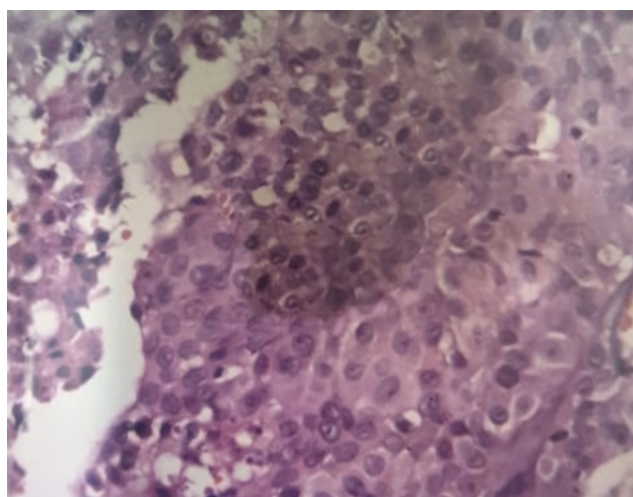
1. Biopsies and mastectomy specimens were fixed in 10% formalin.
2. Detailed history about age, family history, clinical diagnosis and chief complaints was enquired.
3. Tissue was fixed in buffered formalin for about 6 hour after adequate slicing.
4. Gross appearance of mastectomy specimen/biopsy was noted.
5. Paraffin blocks after thorough tissue processing were prepared.
6. Sections were cut 3-4 micron thick and subjected to following:
7. Routine haematoxylin and eosin staining was done for histological typing and grading of all cases.
8. Immunohistochemistry was done using labelled antibodies for hormone receptor status (Oestrogen receptor & Progesterone status), Her2/neu & proliferative index Ki-67.

Invasive ductal carcinomas and all other invasive tumours were graded based on an assessment of tubule/gland formations, nuclear pleomorphism, and mitotic counts as per criteria of Nottingham’s grading.



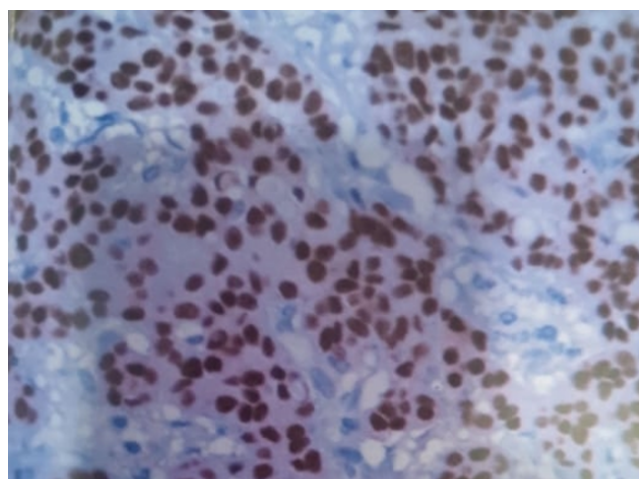
10-HER2 Positive

Fig. 2: HER2 Positive



3-H&E (40X)-Poorly differentiated invasive ductal carcinoma

Fig. 3: H&E (40X) Poorly Differentiated Invasive Ductal Carcinoma



9-Ki-67 Positive

Fig. 1: Ki-67 Positive

### 3. Results

Out of 56 cases, 52 cases (92.85%) had undergone modified radical mastectomy under which whole breast tissue including axillary tail, nipple, surrounding skin were

Table 1: Distribution of cases according to gross

Gross	Number of cases	Percentage
MRM	02	3.57%
Radical MRM	52	92.85%
Core Biopsy	02	3.57%

excised. In 2 cases (3.57%) radical mastectomy was done under which besides pectoralis muscles was also excised. In 2 cases (3.57%) core biopsies from breast were taken.

Table 2: Distribution according to metastatic lymph nodes

Metastasis	No. of cases (N=54)	Percentage
LYMPH node positive	54	100%
LYMPH node negative	-	-

As evident from study of 54 cases of MRM and Radical MRM all were positive for lymph node metastasis and in 2 cases of core biopsy no lymph node.

**Table 3:** Distribution of cases according to quick score

Quick Score	ER		PR	
	No. of cases	Percentage	No. of cases	Percentage
0	24	42.85	22	39.28
2	-	-	-	-
3	10	17.85%	08	14.28%
4	-	-	06	10.71%
5	06	10.71%	06	10.71%
6	07	12.50%	05	8.92%
7	04	7.14%	02	3.57%
8	05	8.92%	07	12.5%

The quick scoring of ER & PR is combination of proportion and intensity scoring. Out of 56 cases, 24 cases (42.85%) were ER negative & 22 cases (39.28%) were PR negative while both were negative in 18 cases (32.14%).

#### 4. Discussion

##### 4.1. Grading of ductal carcinoma is an estimate of differentiation

Histologic grading describe the microscopic growth pattern of invasive ductal carcinoma. The most widely used histologic grading systems are based on criteria established by Bloom & Richardson<sup>5</sup> & Elston & Ellis.<sup>6</sup> The parameters measured are:

1. The extent of tubule formation.
2. Nuclear hyperchromasia, pleomorphism & size.
3. Mitotic rate.

Each of the three elements is assigned a score on a scale of 1 to 3 & the final grade is determined from the sums of score.

Histological grade is traditionally expressed in three categories: score 3 to 5, well differentiated (grade I): scores 6 to 7, intermediate (Grade II) & scores 8 to 9 poorly differentiated (grade III).

Mitotic rate was reported to be the most important feature of Bloom Richardson grading system. The original Bloom Richardson grading system considered hyperchromatic nuclei to be mitotic, but Nottingham histologic grade excludes hyperchromatic nuclei when this is the only mitosis-related feature.<sup>7</sup>

Several variants of Bloom Richardson grading have been described. The system of Schauer & Weiss sub divided Bloom Richardson grade III in to two sub categories used by in total of four grades.<sup>8</sup> The modification of Bloom Richardson grading with more rigorous criteria for most parameters resulted in new staging i.e Nottingham grading.

Nottingham grading

Tubule formation

Score 1: > 75% of tumour has tubules

Score 2: 10-75% of tumour has tubules

Score 3 :< 10% of tumour has tubules

#### 5. Conclusion

For all invasive carcinomas, hormone receptor status is also studied using immunoperoxidase method and Quick scoring was done. The Quick score for ER was 0 in 42.85% (24/56) cases and for PR was 0 in 39.28% (22/56) cases, indicating no hormone expression in majority

#### 6. Source of Funding

No financial support was received for the work within this manuscript.

#### 7. Conflict of Interest

The authors declare they have no conflict of interest.

#### References

1. Song RX, Santen RJ. Membrane Initiated Estrogen Signaling in Breast Cancer1. *Biol Reprod.* 2006;75(1):9–16. doi:10.1095/biolreprod.105.050070.
2. Kuenen-Boumeester V, Kwast THVD, Laarhoven HAV, Henzen-Logmans SC. Ki-67 staining in histological subtypes of breast carcinoma and fine needle aspiration smears. *J Clin Pathol.* 1991;44(3):208–10. doi:10.1136/jcp.44.3.208.
3. Schiller AB, Clark WS, Cotsonis G, Lawson D, DeRose PB, Cohen C, et al. Image cytometric bcl-2:bax and bcl-2:bcl-x ratios in invasive breast carcinoma: Correlation with prognosis. *Cytometry.* 2002;50(4):203–9. doi:10.1002/cyto.10091.
4. Horwitz K, Kosiki Y, McGuire W. Estrogen Control of Progesterone Receptor in Human Breast Cancer: Role of Estradiol and Antiestrogen\*. *Endocrinology.* 1978;103(5):1742–51. doi:10.1210/endo-103-5-1742.
5. Bloom HJG, Richardson WW. Histological Grading and Prognosis in Breast Cancer. *Br J Cancer.* 1957;11(3):359–77. doi:10.1038/bjc.1957.43.
6. Elston CW, Ellis IO. Pathological prognostic factors in breast cancer. The value of histological grade in breast cancer: experience from a large study with long term follow up. *Histopathology.* 1991;19:403–10.
7. Jensen EV, Greene GL, Desombre E. The estrogenreceptor immunoassay in -the prognosis and treatment of breast cancer. *Lab Manag.* 1986;24:25–52.
8. Lal P, Tan LK, Chen B. Correlation of Her2/neu status with estrogen and progesterone receptors and histologic features in 3,655 Invasive Breast cancer. *Am J Clin Pathol.* 2005;123:541–6.

#### Author biography

Pooja Agarwal, Associate Professor

Dupinder Kaur, Resident

**Cite this article:** Agarwal P, Kaur D. To study ductal carcinoma breast with histopathological grades of Nottingham score. *Panacea J Med Sci* 2021;11(1):20-22.