



Original Research Article

Prophylactic Vancomycin-PMMA Strips are an Easy-to-Use and equally effective alternative to antibiotic beads in open fracture care

Bijay Kumar Lamay¹, Sikata Nanda², Ramakanta Mohanty³, Rabi Narayan Dhar^{1,*}, Priyaranjan Acharya⁴

¹Dept. of Orthopedic Surgery, VSS Institute of Medical Science and Research, Burla, Odisha, India

²Dept. of Community Medicine, SCB Medical College, Cuttack, Odisha, India

³Dept. of Surgery, FM Medical College, Balasore, Odisha, India

⁴Dept. of Orthopaedic, SCB Medical College, Cuttack, Odisha, India



ARTICLE INFO

Article history:

Received 26-08-2020

Accepted 28-11-2020

Available online 29-04-2021

Keywords:

Vancomycin

Polymethyl methacrylate

Beads

Strip

ABSTRACT

Objectives: Even under ideal conditions, infection remains a risk of surgery and can be harrowing after surgical repair of compound fractures. This study aimed to assess the efficacy and convenience of local antibiotic-impregnated polymethyl methacrylate (PMMA) strips to overcome infection and functional union within a specified time after primary definitive stabilization of compound fractures.

Design: We investigated patients who received PMMA-vancomycin strips during orthopedic surgical repair of open fractures.

Setting: From 2017 to 2019 in a tertiary medical center.

Patients: A total of 106 patients with open fractures type I through IIIC were included (age range, 24–62 years).

Intervention: Patients underwent profuse wound cleaning, methodical debridement, and definitive stabilization with PMMA-vancomycin strips.

Main Outcome Measurements: We measured the incidence of wound healing, fracture union, and infection rate. Patients were followed for two years with infection parameters and radiographs. The efficacy of the PMMA strips in our study with that of PMMA beads in similar procedures from published studies was compared.

Results: Of 106 patients, five (4.7%) had a subclinical infection until implant removal. We found no osteomyelitis or non-union in any patient. A literature search confirmed comparable outcomes in infection rates between the PMMA strips used in this study and antibiotic beads used in previous studies. However, the removal of PMMA vancomycin strips is generally more convenient compared with that of beads.

Conclusions: For the controversial challenge of determining the duration to keep or remove antibiotic beads, PMMA vancomycin strips present surgeons with an easy-to-use alternative with equivalent efficacy.

© This is an open access article distributed under the terms of the Creative Commons Attribution License (<https://creativecommons.org/licenses/by/4.0/>) which permits unrestricted use, distribution, and reproduction in any medium, provided the original author and source are credited.

1. Introduction

When Alexander Fleming used topical antibiotics for open wounds for the first time during World War I, he observed that local antibiotics markedly reduced the burden of bacteria.¹ Half a century later, Buchholz and Engelbrecht² first used antibiotic-loaded bone cement

as a prophylactic agent against deep-bone infections in orthopedic endoprosthetic surgery in human patients.² A high local concentration of antibiotics and low systemic side effects were the major outcomes.^{3,4} To penetrate biofilm, an antibiotic concentration of 10 to 100 times higher than normal is required and not safe for systemic use. The major factors affecting the maintenance of the local higher concentrations of antibiotics with PMMA are thermostability of the antibiotic, porosity of the antibiotic

* Corresponding author.

E-mail address: drbijaylamay@rediffmail.com (R. N. Dhar).

vehicle, and, most importantly, the surface area of the antibiotic PMMA construct for elution of the antibiotic.^{5,6}

This study sought to evaluate the efficacy of vancomycin-PMMA strips in contrast to data available for conventional antibiotic PMMA beads in open fractures. We have used PMMA vancomycin in strips for their optimal thermostability, availability in powder form, ease of mixing before adding liquid monomer, and less allergenic properties. Antibiotic beads have proven efficacy in open-fracture management, but their elution properties are reduced by limitations, such as impaired local anatomy, extensive scarring, elaborate hand preparation requirements in developing countries, and fibrosis around the beads.⁷ Strips are as efficient as beads at providing high-concentration local antibiotics but have the advantages of producing less fibrosis scar tissue and being easier to place and remove.

2. Patients and Methods

This study was undertaken in 106 open fractures between 2017 and 2019 at VSS Institute of Medical Science and Research Burla in western Odisha, India. Of these fractures, 89 were of the tibia, 4 were forearm, and 13 were femurs. They were further categorized as Gustilo and Anderson⁸ open fracture type I with high-velocity injury (17 total), type II (15), type IIIA (37), type IIIB (34), and type IIIC (6).

Inclusion criteria were open fractures within day 1 to 7 of presentation, age 20–65 years, and fit for anesthesia. Exclusion criteria included any comorbidity like diabetes mellitus or immune-compromised patients, known hypersensitivity to vancomycin, Prior underlying chronic infections or pathological fractures, and polytrauma with head or chest injuries.

2.1. Procedure

For type I, II, and IIIA, 69 patients received thorough cleaning of the wound with normal saline and povidine-iodine. On the same day, they underwent primary stabilization and application of vancomycin-impregnated PMMA strips. Systemic antibiotics (third generation cephalosporin, aminoglycoside, and metronidazole) were administered for five days.^{9,10}

In six tibia cases, the patients arrived one week after initial injury with severe contamination with soil and grass particles. They arrived late due to poverty, ignorance, and the lack of facility. Swab cultures were taken, wounds were cleaned thoroughly with normal saline and a povidine-iodine scrub, debridement was performed under anesthesia, and external fixation was applied.¹¹ After one week of daily debridement and cleaning, definitive stabilization was performed with implantation of vancomycin-impregnated PMMA strips. The wounds were closed using soft-tissue release and split-thickness skin grafts as needed. We

continued susceptible systemic antibiotics for five days post culture reports.

For types IIIB and IIIC fractures, debridement was performed with soft tissue and neurovascular repair and external fixation for one or a maximum of two weeks. Following internal fixation, vancomycin-impregnated PMMA strips were administered, and the wound was closed by soft tissue release, transposition flaps, or split-thickness skin grafting.

We discharged the patients on the fifth postoperative day and removed sutures between 2 and 3 weeks. Partial weight-bearing, range-of-movement, and isometric exercise began on the second postoperative day. The patients were followed monthly with infection parameters, including leukocyte count, serum protein, total lymphocyte count, and C-reactive protein. Follow-up radiographs were taken at 3, 6, 9, 12, and 24 months. At the end of two years, 5 (4.7%) of 106 patients had subclinical infections. All of the patient strips were removed within 60 to 90 days except in two cases, who presented two years afterward with sterile discharge and a strip exposed in one tibia patient. Nevertheless, the fractures were united, and the patients were relieved with implant and strip removal. No instances of non-union or osteomyelitis appeared in our series of patients.

2.2. Strip preparation

Strips were prepared in the operation theater by mixing 4 g vancomycin with 40 g PMMA polymer. After thoroughly mixing the vancomycin and polymer powder, 10 g liquid monomer was added and mixed. We used double-twisted 18 G stainless steel wires of the desired length to incorporate the cement vehicle. When cement is in a doughy stage it was incorporated into SS wire by rolling between the palms. These were placed on a flat surface and flattened into strips using a metal roller. Before the cement hardened, the strips were longitudinally cut to 1–2.5 cm wide. Between one and three strips were used per site of impregnation. The length of the strips covered at least the entire length of the size of the wound proximally and distally (Figure 1A–C).

3. Results

In all patients with grade I, II, or IIIA fractures, 69/69 (100%) wounds were healed and fractures were united. In grade IIIB fractures, 2/34 (5.88%) had subclinical infection, and 3/6 (50%) open IIIC fractures had sterile discharging sinus after suture removal. No special systemic antibiotics or debridement was performed for these; only soap water baths and expressing the wound twice daily, and they healed completely within three months. Figure 2 shows a 48-year-old male with a compound grade IIIB open fracture.

In this study group, the infection rate was 5/106 (4.7%). At two-year follow-up examinations, the union rate was

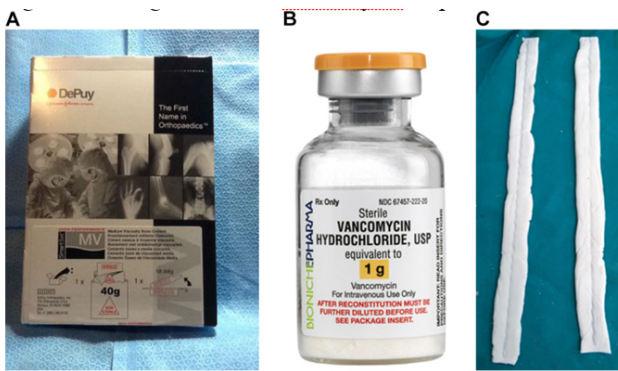


Fig. 1: A. 40-g PMMA; B: Vancomycin strips

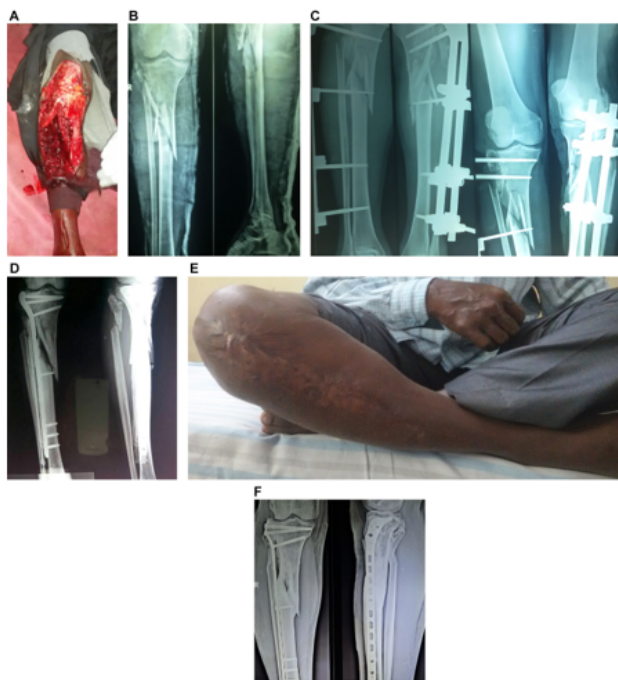

Fig. 2: A: Open Gr IIIB fracture; B: Radiological picture; C: with external fixation; D: Post operation with strips; E: Clinical outcome; F: follow-up at 24 months

100%. The time to union was 8–12 weeks in upper-limb open fractures and 12–36 weeks in lower-limb open fractures. PMMA vancomycin strips were removed 8–12 weeks postoperatively. Of 106 patients, two failed to follow up within two years. After two years, the patients returned with serous discharge and exposed strips at the distal tibia. (Figure 4a,b) These complications did not hamper a sound union within the specified time, however, and once the strips and implants were removed, the wound healed completely. No antibiotic- or implant-related local or systemic infection or acute wound infection was observed.

4. Discussion

Local vancomycin strips in the present study of open fractures with definitive fixation show comparable efficacy with antibiotic beads used for similar procedures in large studies. All of the patients in our study, irrespective of sex and socioeconomic status, had complete wound healing within similar timelines to those of previously reported open fracture repairs in which antibiotic beads were used. Ostermann et al.¹² reviewed 845 open fractures using copious irrigation, meticulous debridement, and local PMMA antibiotics, and they concluded that 3.7% of patients experienced postoperative infections. They observed a reduced infection rate for all fracture types that reached statistical significance in types IIIB and IIIC.¹² Henry et al.¹³ found that prophylactic antibiotic impregnation with systemic antibiotics has a significant effect on type III open fractures. Several authors^{9,11,14–16} found local PMMA antibiotics favorable for maintaining local concentrations without systemic manifestations. Calhoun et al.¹⁷ stated that the presence of bacteria around beads did not affect wound and fracture healing.

Zalavras et al.⁴ reported similar benefits of antibiotic beads. They raised the controversial issue of reoperation and removal of PMMA antibiotic beads. The sealing of a wound without a drain is essential to reduce fluid turnover, an important factor in maintaining local antibiotic concentrations. A bead left in situ develops resistant pathogens due to prolonged sub therapeutic antibiotic levels and behaves like a foreign body, predisposing the patient to a secondary infection. Bead removal is recommended at 6 to 6 weeks because beads enclosed in fibrous tissue or a callus reduce elution and complicate removal. Henry et al.⁹ observed that fibrosis soft tissue near joints limited movement, causing emotional and financial burden risks associated with beads. To answer these entire hypotheses, we introduced antibiotic PMMA strips to remove easily at 8 to 12 weeks even after 2 years maintaining desirable local antibiotic concentration.

The topical treatment of wounds has been applied since ancient times from Egypt to India. Several clinical researchers around the world have reported the efficacy of local antibiotic therapy for open wounds to maintain a higher local concentration of antibiotics to break biofilms¹⁶ and to avoid resistant pathogens and the morbidity of long-term intravenous antibiotics.¹⁷ Local PMMA antibiotic release is a two-stage process, with the highest concentration reached within hours to days, and high concentrations persisting for as long as five years.¹⁰ Multiple factors influence the elution of antibiotic PMMA, including matrix-like surface area, concentration, post-implantation time, and fluid turnover. Elution takes place through pores, voids, cracks, and passive diffusion of the matrix. Local, high concentrations of antibiotics alone are insufficient without adequate

debridement.^{15,18} Antibiotics at 10 to 100 times the normal concentration discourage resistance and suppress bacteria until regenerating tissue can destroy residual organisms.⁹ Efficient breakage of biofilm and use of the blood-bone barrier also protects against systemic toxicity.^{19,20} Walenkamp et al.²⁰ and Salvati et al.²¹ reported no renal toxicity and serum levels $\leq 0.5 \mu\text{g/mL}$ in such methods of delivering local high-concentration antibiotics. Furthermore, Springer et al.²² and Hsieh et al.²³ reported clinical safety at higher doses (10.5 g vancomycin; 12.5g gentamycin) than those in our study.

However, for all favorable outcomes reported by several authors, limitations subsist while evaluating the clinical role, the undefined extent of devitalized tissue after debridement, and removal or necessity to remove the antibiotic vehicle matrix. The major drawbacks of using beads include not being used as mechanical filler, risk of incomplete closure of the wound, and decrease of elution and complication of removal if the beads are incorporated into fibrous tissue or calluses. Incomplete wound closure increases the risk of secondary infections and maximizes local fluid turnover, which is an important factor for maintaining a high local concentration of antibiotics. Otherwise, a PMMA matrix with decreased elution may behave as a foreign body, and sub therapeutic concentrations of antibiotics develop resistant organisms. The introduction of PMMA strips rather than beads can overcome these complications. Antibiotic-loaded PMMA strips provide a solution to the controversial questions of what duration to keep the antibiotic vehicle, where to place it most effectively, and how to remove it safely. We easily and successfully removed all strips from all patients in the present study.

In our series and follow-up of two years, the clinical outcomes were comparable with those of open fracture cases using other antibiotics or other modes of antibiotic local PMMA impregnation. The major advantages to the strips are accommodation anywhere inside musculoskeletal compartments (Figure 3 A,B,C, Figure 4) in the limbs without creating difficulties in wound closure, a large surface area for antibiotic elution,²⁴ and simplicity of removal with a single stab incision.(Figure 5)

5. Conclusions

PMMA vancomycin-impregnated strips are equally effective as PMMA beads for compound fractures. Their efficacy in elution and maintaining local tissue concentration of antibiotics is comparable. Importantly, the strips can be easily accommodated in the Osteo-muscular plane, so that in cases of open tibia and forearm fractures, wound closure is not as difficult as it is with beads. The most important outcome of our study was the effortless removal of the strips with only a nick of a few centimeters in length. Further study is needed to evaluate the elution

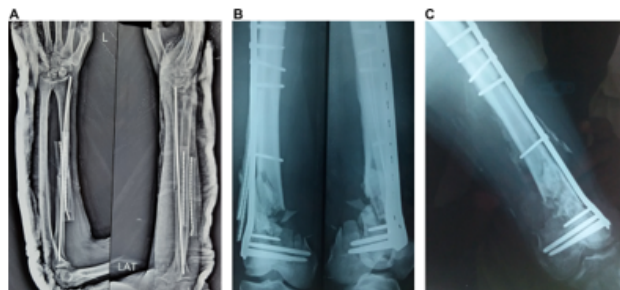


Fig. 3: A: strips in the forearm; B: strips in the thigh; C: union progression in same patient after strip removal.

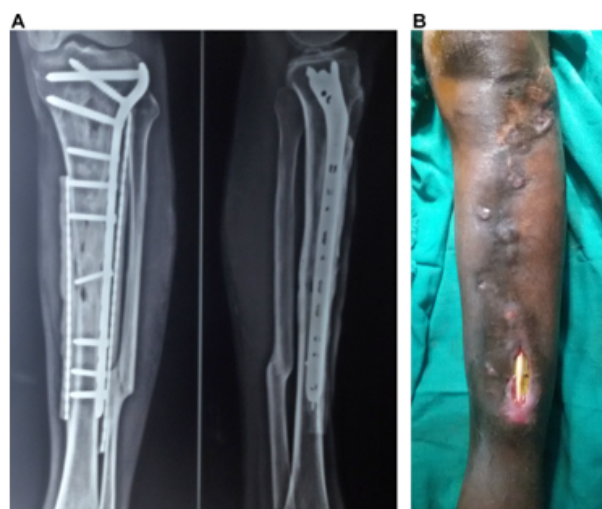

Fig. 4: Follow-up after 2 years. A: strips in united tibia; B: complicate to exposed at shin

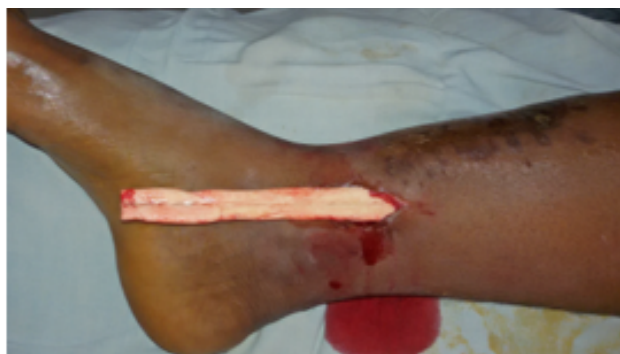

Fig. 5: Strip removal

efficacy and duration to maintain the desired level of local antibiotic concentrations by PMMA strips or whether an in situ reloading of antibiotics is feasible. Further data are needed for an ideal bioabsorbable vehicle to enhance delivery potential, to eliminate the complication of removal, and to achieve longer implantation times.

6. Source of Funding

No financial support was received for the work within this manuscript.

7. Conflict of Interest

The authors declare they have no conflict of interest.

References

- Fleming A. The action of chemical and physiological antiseptics in a septic wound. *Br J Surg.* 1919;7(25):99–129. doi:10.1002/bjs.1800072508.
- Buchholz HW, Engelbrecht H. Über die Depotwirkungeiniger Antibioticabei Vermischungmitdem Kunstharz Palacos. [Depot effects of various antibiotics mixed with Palacos resins]. *Chirurg.* 1970;41:511–5.
- Hauser CJ, Adams CA, Eachempati SR. Council of the Surgical Infection Society. Surgical Infection Society guideline: prophylactic antibiotic use in open fractures: an evidence-based guideline. *Surg Infect (Larchmt).* 2006;7:379–405.
- Zalavras CG, Patzakis MJ, Holtom P. Local Antibiotic Therapy in the Treatment of Open Fractures and Osteomyelitis. *Clin Orthop Relat Res.* 2004;427:86–93. doi:10.1097/01.blo.0000143571.18892.8d.
- Penner MJ, Masri BA, Duncan CP. Elution characteristics of vancomycin and tobramycin combined in acrylic bone—cement. *J Arthroplasty.* 1996;11(8):939–44. doi:10.1016/s0883-5403(96)80135-5.
- Gardner MJ, Mehta S, Barei DP, Nork SE. Treatment Protocol for Open AO/OTA Type C3 Pilon Fractures With Segmental Bone Loss. *J Orthop Trauma.* 2008;22(7):451–7. doi:10.1097/bot.0b013e318176b8d9.
- Nelson CL, Hickmon SG, Harrison BH. Elution characteristics of gentamicin-PMMA beads after implantation in humans. *Orthopedics.* 1994;17:415–6.
- Gustilo RB, Anderson JT. Prevention of infection in the treatment of 1025 open fractures of long bones: retrospective and prospective analyses. *J Bone Joint Surg Am.* 1976;58:453–8.
- Henry SL, Hood GA, Seligson D. Long-term implantation of gentamicin-polymethylmethacrylate antibiotic beads. *Clin Orthop Relat Res.* 1993;295:47–53. doi:10.1097/00003086-199310000-00009.
- Patzakis M, Mazur K, Wilkins J, Sherman R, Holtom P. Septopal Beads and Autogenous Bone Grafting for Bone Defects in Patients With Chronic Osteomyelitis. *Clin Orthop Relat Res.* 1993;295:112–8. doi:10.1097/00003086-199310000-00016.
- Wählig H, Dingeldein E, Bergmann R, Reuss K. The release of gentamicin from polymethylmethacrylate beads. An experimental and pharmacokinetic study. *J Bone Joint Surg.* 1978;60-B(2):270–5. doi:10.1302/0301-620x.60b2.659478.
- Ostermann PA, Seligson D, Henry SL. Local antibiotic therapy for severe open fractures. A review of 1085 consecutive cases. *J Bone and Joint Surg.* 1995;77-B(1):93–7. doi:10.1302/0301-620x.77b1.7822405.
- Henry S, Ostermann P, Seligson D. The Prophylactic Use of Antibiotic Impregnated Beads in Open Fractures. *J Trauma.* 1990;30(10):1231–8. doi:10.1097/00005373-199010000-00007.
- Klemm K. Gentamycin-PMMA-Kugeln in der BehandlungabszedierenderKnochen- und Weichteilinfektionen [Gentamicin-PMMA-beads in treating bone and soft tissue infections (author's transl)]. *Zentralbl Chir.* 1979;104:934–42.
- Evans R, Nelson C. Gentamicin-Impregnated Polymethylmethacrylate Beads Compared With Systemic Antibiotic Therapy in the Treatment of Chronic Osteomyelitis. *Clin Orthop Relat Res.* 1993;295:37–42. doi:10.1097/00003086-199310000-00007.
- van Vugt T, Arts JJ, Geurts JAP. Antibiotic-Loaded Polymethylmethacrylate Beads and Spacers in Treatment of Orthopedic Infections and the Role of Biofilm Formation. *Front Microbiol.* 2019;10:1626. doi:10.3389/fmicb.2019.01626.
- Calhoun J, Henry S, Anger D, Cobos JA, Mader JT. The Treatment of Infected Nonunions With Gentamicin-impregnated Polymethylmethacrylate Antibiotic Beads. *Clin Orthop Relat Res.* 1993;295:23–7. doi:10.1097/00003086-199310000-00005.
- Fitzgerald RH. Experimental osteomyelitis: description of a canine model and the role of depot administration of antibiotics in the prevention and treatment of sepsis. *J Bone Joint Surg.* 1983;65:371–80.
- Eckman J, Henry S, Mangino P, Seligson D. Wound and Serum Levels of Tobramycin With the Prophylactic Use of Tobramycin-Impregnated Polymethylmethacrylate Beads in Compound Fractures. *Clin Orthop Relat Res.* 1988;237:213–5. doi:10.1097/00003086-198812000-00031.
- Walenkamp GH, Vree TB, Rens TJV. Gentamicin-PMMA beads. Pharmacokinetic and nephrotoxicological study. *Clin Orthop Relat Res.* 1986;205:171–83.
- Salvati EA, Callaghan JJ, Brause BD. Reimplantation in infection. Elution of gentamicin from cement and beads. *Clin Orthop Relat Res.* 1986;207:83–93.
- Springer BD, Lee GC, Osmon D, Haidukewych GJ, Hanssen AD, Jacofsky DJ, et al. Systemic Safety of High-Dose Antibiotic-Loaded Cement Spacers after Resection of an Infected Total Knee Arthroplasty. *Clin Orthop Relat Res.* 2004;427:47–51. doi:10.1097/01.blo.0000144476.43661.10.
- Hsieh PH, Huang KC, Tai CL. Liquid gentamicin in bone cement spacers: in vivo antibiotic release and systemic safety in two-stage revision of infected hip arthroplasty. *J Trauma.* 2009;66:804–8.
- Holtom PD, Warren CA, Greene NW. Relation of surface area to in vitro elution characteristics of vancomycin-impregnated polymethylmethacrylate spacers. *Am J Orthop.* 1998;27:207–10.

Author biography

Bijay Kumar Lamay, Assistant Professor

Sikata Nanda, Associate Professor

Ramakanta Mohanty, Associate Professor

Rabi Narayan Dhar, Associate Professor

Priyaranjan Acharya, Post Graduate Student

Cite this article: Lamay BK, Nanda S, Mohanty R, Dhar RN, Acharya P. Prophylactic Vancomycin-PMMA Strips are an Easy-to-Use and equally effective alternative to antibiotic beads in open fracture care. *Panacea J Med Sci* 2021;11(1):45–49.