



Original Research Article

Comparative study of functional outcome of dynamic compression plating and interlocking nailing for fracture shaft of humerus in adults

K Ram Mohan¹, K Kishore Kumar^{1,*}, J Venkateshwarlu¹, T Ashwin kumar¹,
B Pranav Krishna¹

¹Dept. of Orthopaedics, MGM Hospital, Kakatiya Medical College, Warangal, Telangana, India



ARTICLE INFO

Article history:

Received 05-06-2020

Accepted 25-06-2020

Available online 29-04-2021

Keywords:

Dynamic compression plate

Fracture shaft of humerus

Internal fixation

Interlocking nail

Rommen's criteria

ABSTRACT

Introduction: Fractures of humeral shaft are commonly encountered by an orthopaedic surgeon, accounting for 1-2% of all fractures. Treatment of these injuries continues to evolve as advances are made both in operative and non-operative management. Most humerus fractures are managed non operatively with anticipated good to excellent results. Surgery is indicated in certain settings, nature of injury, fracture pattern and also patient's demand.

Objective: The aim of this study is to compare the functional outcomes of plating with nailing and also the results of this study with standard works reported in literature, in terms of rate of union in both fixations, the functional outcomes of the treatment and incidence of complications like non-union, infection, radial nerve palsy.

Setting: This study was conducted at the orthopedics department of a teaching hospital in India.

Design: This was 2 years prospective, longitudinal, hospital based, observational study, and its outcomes.

Participants: The study was done in 30 patients diagnosed as fractures of shaft of humerus of traumatic etiology meeting the inclusion & exclusion criteria, admitted at Mahatma Gandhi Memorial Hospital (attached to Kakatiya Medical College, Warangal), from December 2016 to November 2018. These patients were randomized into two groups in which 15 cases were treated by open reduction and internal fixation using the dynamic compression plate (DCP) and 15 cases were treated with closed reduction and internal fixation with intramedullary interlocking nail (ILN).

Results: A detailed analysis of the functional outcome of 30 patients treated in the present study was done based on Rommen's criteria, and out of 15 patients treated with dynamic compression plating, 13 had excellent results, 2 had good results.

In 15 patients treated with intramedullary interlocking nailing, 10 had excellent results and 3 had good results and 2 had poor result.

Conclusion: Based on our experience and results, we conclude that the transverse fractures of humerus shaft are better treated with ante grade intramedullary interlocking nail, and comminuted fracture shaft humerus and those fractures associated with neuro-vascular or soft tissue injuries are better treated with plating.

© This is an open access article distributed under the terms of the Creative Commons Attribution License (<https://creativecommons.org/licenses/by/4.0/>) which permits unrestricted use, distribution, and reproduction in any medium, provided the original author and source are credited.

1. Introduction

Fractures of shaft of Humerus accounts for nearly 1%-2% of all skeletal fractures and 14% of fractures involving the humerus.¹ Its incidence is bi-modal with a first peak in third

decade of life mostly men, due to high energy trauma and a second peak in women around sixth decade due to trivial trauma.

Most humeral fractures do not require surgery and are treated conservatively with a functional orthosis. Sarmiento showed consistent and rapid healing of fractures treated with use of pre-fabricated braces with resultant excellent

* Corresponding author.

E-mail address: orthodockishore@gmail.com (K. Kishore Kumar).

alignment, early restoration of joint function and minimal morbidity. Authors like Balfour,² Klenermann strongly recommend closed treatment of humeral shaft fractures unless specific indications for operative intervention exist.

Indications for surgery include unacceptable alignment with closed treatment, open fractures, unstable fractures (long/spiral), segmental fractures, fractures associated with neurovascular injuries, ipsilateral forearm bones fractures and pathological fractures.

In these situations the surgeon can choose from a variety of options which include external fixator, compression plating (ORIF / MIPPO) and use of intra-medullary nails (flexible/rigid, ante grade/retrograde nailing).

Open reduction & internal fixation with dynamic compression plate (DCP) gives following advantages:

1. This is a method of achieving a direct open reduction and stable fixation without violation of rotator cuff.
2. Facilitates identification, exploration and preservation of radial nerve.
3. As there is no need for C- arm the medical staff has no radiation hazards.
4. The limb can be mobilized early & joint stiffness as well as muscle contractures can be minimized.

Closed reduction and internal fixation with Intramedullary Inter Locking Nail (ILN) has following advantages:

1. Minimal surgical intervention (so less soft tissue damage, less infection and less radial nerve palsies)
2. Load sharing implant³
3. Biological fixation
4. Rotational and torsional stability
5. Early mobilization

2. Materials and Methods

The clinical material for the study of Surgical management of traumatic Diaphyseal fractures of humerus in adults consists of 30 patients, meeting the inclusion and exclusion criteria and treated by two fixation modes(DCP/ ILN), which were admitted in the department of Orthopaedics, MGM Hospital, Warangal, between December 2016 to November 2018.

All patients were informed about the study, and written consent was obtained for their inclusion in this study. Ethical approval was taken from the Institutional Ethics Committee.

2.1. Inclusion criteria

1. Patients of closed diaphyseal fractures of humerus in adults aged > 18years, involving both sexes.
2. Fresh fractures.
3. Patients with comminuted fractures.

2.2. Exclusion criteria

1. All grades of compound fractures of shaft of humerus.
2. Pathological fractures.
3. Proximal and Distal Humeral fractures having articular extensions.
4. Below the age of 18years
5. Infected fractures
6. Un-united fractures.
7. Medically unfit for surgery

2.3. Data Recording (Clinical and Radiological)

As soon as the patient is admitted, a detailed history was taken & a meticulous physical examination of the patient was done. The required information was recorded in the proforma. The radiographs of patient's affected arm were taken both in the Antero-Posterior & Lateral views. The diagnosis was established by clinical & radiological examination.

In this study, diaphyseal fracture of Humerus were classified according to L. Klenerman's⁴ classification (1966) of London, depending on the level of fracture.

1. Fractures of upper most third.
2. Fractures at the junction of uppermost and middle third.
3. Fractures of middle third of shaft.
4. Fractures at the junction of middle & lowest third.
5. Fractures of the lowest third of shaft.

2.4. Management protocol

In the meantime, the patient's injured arm is immobilized in a plaster of paris U- slab, analgesics are given to alleviate pain. All the patients were taken for elective surgery as soon as possible after necessary pre- operative work-up. Routine blood investigations like CBP, RBS, Blood Urea, Serum Creatinine, Serum Electrolytes, Blood grouping and typing, HIV, HBSAg; and ECG, chest X-ray were done.

The patient and his attendants were explained about the nature of injury & its possible complications, the med for the surgery & complications of surgery. Written & informed consent was obtained from the patient for surgery.

Medical evaluation of the patient is done after consulting the Physician and anesthetist is informed. Preparation of the part was done and painted with antiseptic.

Peroperative parenteral antibiotic (preferably Cephalosporins) is administered one hour before surgery.

2.5. Pre-operative planning regarding the use of implant

Depending on the level of fracture and nature of fracture, an appropriate implant, and surgical approach was selected.

In case of plating (Figures 1 and 2), the two types of plates 5 (Broad & Narrow of 4.5mm DCP), length of plate,

number of screws required (4.5mm) & the necessity of inter fragmentary screws (3.5mm /4.5 mm) are all approximately assessed.

In case of nailing (Figure 3), the length of nail (24cm, 26cm, 28cm & 30cm) and diameter of nail (6mm, 7mm & 8mm), the number of proximal and distal locking screws required, are all assessed.

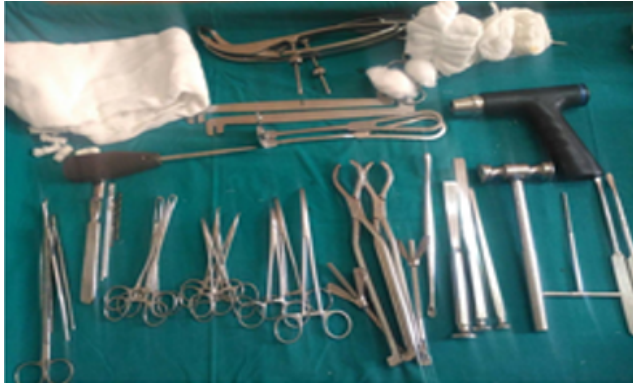

Fig. 1: Instruments required for plating



Fig. 2: Implants (DCPs and screws)

Anesthesia: All patients were taken up for surgery under General Anesthesia.

2.6. Operative technique of plating

Patient's Positioning: The patient is placed in lateral decubitus position with arm supported on a bolster/arm board for Posterior approach (for fractures distal third of the shaft and fractures associated with radial nerve deficit and Supine position for Anterior approach with arm on side board.

Draping: The arm with the axilla is scrubbed, painted with Betadine solution and well draped.

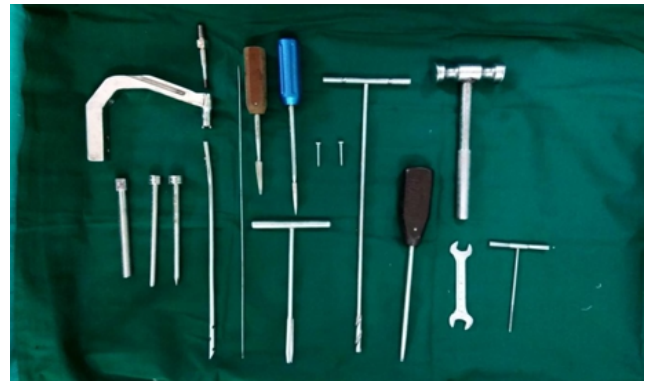

Fig. 3: Instruments and implants for nailing

2.7. Surgical approaches:⁴

Anterolateral approach (Henry) for upper and middle third fractures:

A longitudinal incision is made over the tip of coracoid process of scapula; it runs down distally and laterally in line of the delto-pectoral interval upto the insertion of deltoid muscle, on the lateral aspect of the humerus about half way down its shaft; continuing distally as far as necessary following the lateral border of biceps muscle. The soft tissue is dissected as per brachialis splitting approach and the fracture site is exposed.

2.8. Posterior approach (Triceps splitting approach)

The skin is incised in the midline on the back of the arm from the tip of the olecranon upwards and deepened through subcutaneous tissue to expose the muscle bellies of the triceps.

The interval is developed between the two heads of triceps by blunt dissection (retracting the lateral head laterally and the long head of the triceps medially). The medial head of the triceps is identified and isolated which lies below the other two heads and the fracture site is exposed. Care is taken not to injure the radial nerve throughout its course.

Following the exposure of fracture site, through either of the above approaches, the ends are freshened by curetting. The fracture fragments are reduced & a predetermined type and appropriate length of plate (minimum 7 holed) is placed on the surface of bone and held with bone clamps. Then the plate is fixed with 4.5mm cortical screws (ensuring purchase of 6-8 cortices in both the fragments) and if necessary interfragmentary screws are used. Hemostasis is secured and the wound is closed in layers over a suction drain. Aseptic sterile dressing is done and U-slab is applied.

2.9. Operative technique of nailing

Patient Positioning: Patient was kept supine with the head turned towards the contralateral side and a pillow was placed between the medial borders of scapulae; this increases the exposure of the shoulder. **Draping:** The arm with the axilla is scrubbed, painted with Betadine solution and well draped.

2.10. Antegrade technique

Reamed antegrade nailing was done in all cases under the control of image intensifier.

Small incision of 3 cm given over the skin from anterolateral edge of acromion. Deltoid muscle fibers are carefully dissected to avoid unnecessary damage to supraspinatus and the greater tuberosity was exposed.

Then with the help of a curved awl, entry point is created 0.5 cm posterior to the bicipital groove to avoid injury to the rotator cuff and in the sulcus between greater tuberosity and articular surface in AP view. A guide wire was passed into the proximal fragment and after achieving closed reduction, across the fracture site into the distal fragment. Sequential reaming was done taking care not to shatter the distal humeral canal which is narrow due to anatomic architecture.

The selected nail was then mounted on a jig and passed over the guide wire ensuring that the distal end of the nail was approximately 1-2 cms away from the olecranon fossa and the proximal end is countersunk (5-10mm) within the greater tuberosity. The proper position of the nail was confirmed with an image intensifier. After visualizing proper reduction at the fracture site, then a distal locking screw (3.5mm) was applied in antero-posterior direction by free hand technique. A nappropriately sized proximal interlocking screw was applied with the aid of a jig.

Entry site was properly irrigated with saline and wound was closed in layers. A sling was applied.

2.11. Post-operative management

1. The Blood pressure, Pulse rate, Temperature was recorded. Soakage of dressings if any is noted.
2. Once patient recovers from anesthesia the wrist & finger movements were examined for any iatrogenic radial nerve injury.
3. Broad spectrum antibiotics IV and analgesics IM/Oral are continued.
4. On the 2nd Post-operative day drain was removed, the condition of the wound is noted and sterile dressing done.
5. Check X-ray of the operated arm is taken both in Antero-Posterior & Lateral views.
6. From the 5th Post-operative day oral antibiotics were prescribed till the suture removal.
7. Sutures are removed on the 10th postop day.
8. The patient is discharged with the U-slab applied and arm supported in an arm pouch. Patient is instructed to

review after 3 weeks at OPD.

2.12. Follow-Up Protocol

1. On follow-up, U-slab is removed. Pendulum exercises for shoulder, ROM exercises for elbow, forearm & wrist are taught.
2. Regular OPD follow-ups were done on the 6th week, 3rd month, 6th month, 1 year, 18 months and 2 years.
3. At each visit, clinical examination (wound/scar, tenderness, movements of joints, NV status and radiological evaluation (evidence of union and status of the implant) was done & post-operative complications if any, noted. (Figures 4 and 5)
4. The functional results are usually graded as per ASES score (American Elbow and Shoulder Surgeons) which consists of 13 activities of daily living (ADL), requiring full shoulder and elbow movements. Each activity has a score of 4 points (0-3). It has two subscales, 50 points for each subscale. 1: patient reported pain scores (VAS) and 2: physician assessed functional scores/ADL. Calculation of ASES score is somewhat more arduous than other shoulder outcome measures. Hence we used a simplified grading system like Rommen's criteria.
5. Rommen's criteria⁵(Table 1). Shoulder and elbow functions were graded as excellent, moderate, or poor depending upon the loss of range of motion in joints in any direction, subjective complaints like pain were also taken into account.

Table 1: Functional Results (Rommen's criteria)

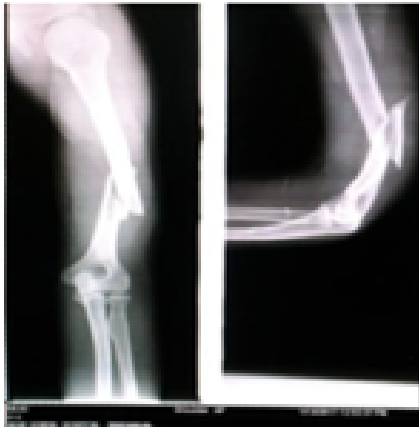Grade	Range of motion (ROM) Shoulder / elbow	Subjective complaints
Excellent	<10 ⁰ loss of ROM in any direction	None
Moderate	Loss of ROM between 10 ⁰ - 30 ⁰ in any direction	Mild
Poor	Loss of ROM >30 ⁰ in any direction	Moderate to Severe

3. Observation and Results

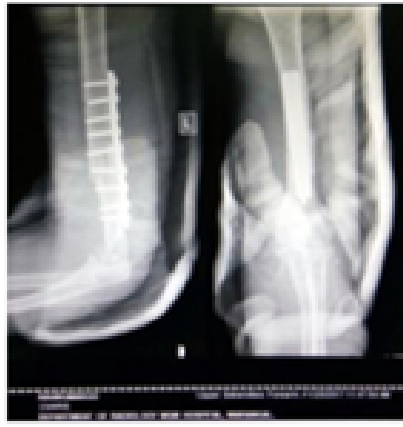In thirty patients diagnosed as closed fracture shaft of humerus, 15 were treated by open reduction and internal fixation with dynamic compression plate and another 15 were treated by closed reduction and internal fixation with intramedullary interlocking nail.

The following observations were made from the data collected during this study.

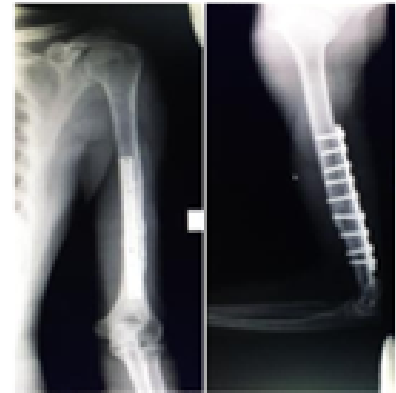There was a higher incidence of fractures shaft of humerus in 10 patients (33.33%) in the age group of 20-30 years, in this study.



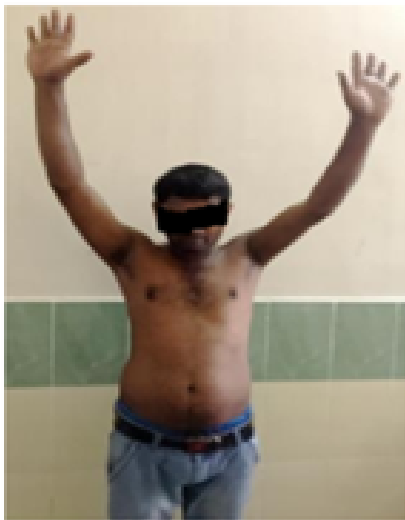Preoperative Xray of Left arm AP. & Lat. view



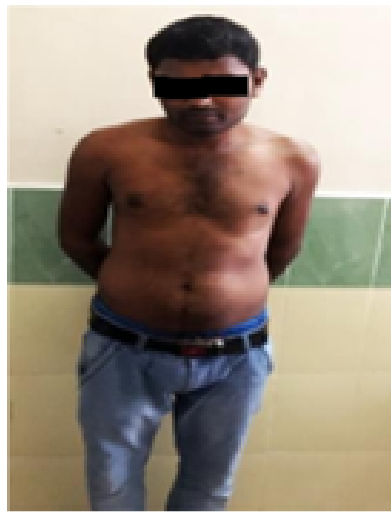Post operative Xray of Left arm AP. & Lat. view.



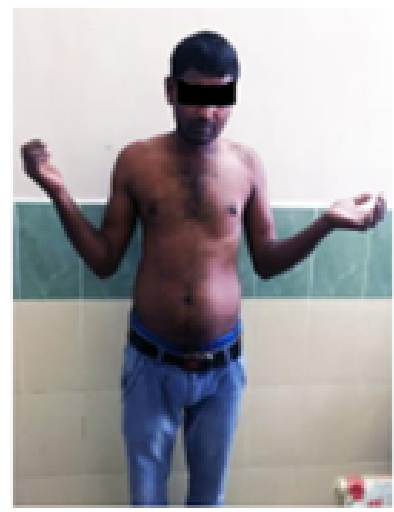Follow up Xray of Left arm AP. & Lat. view showing sound union.



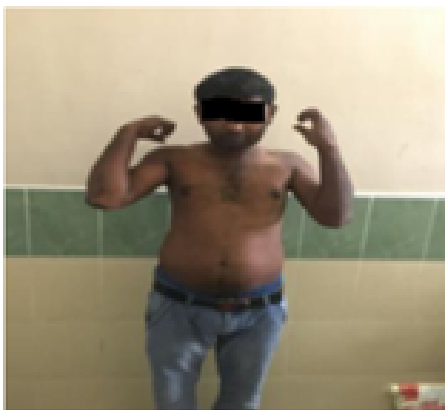Shoulder abduction



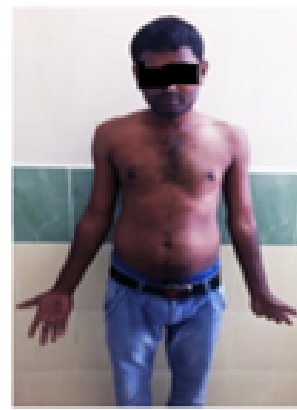Shoulder internal rotation



Shoulder external rotation



Elbow flexion



Elbow extension

Fig. 4: Serial images of a case of fracture shaft of humerus managed with dynamic compression plating (DCP)

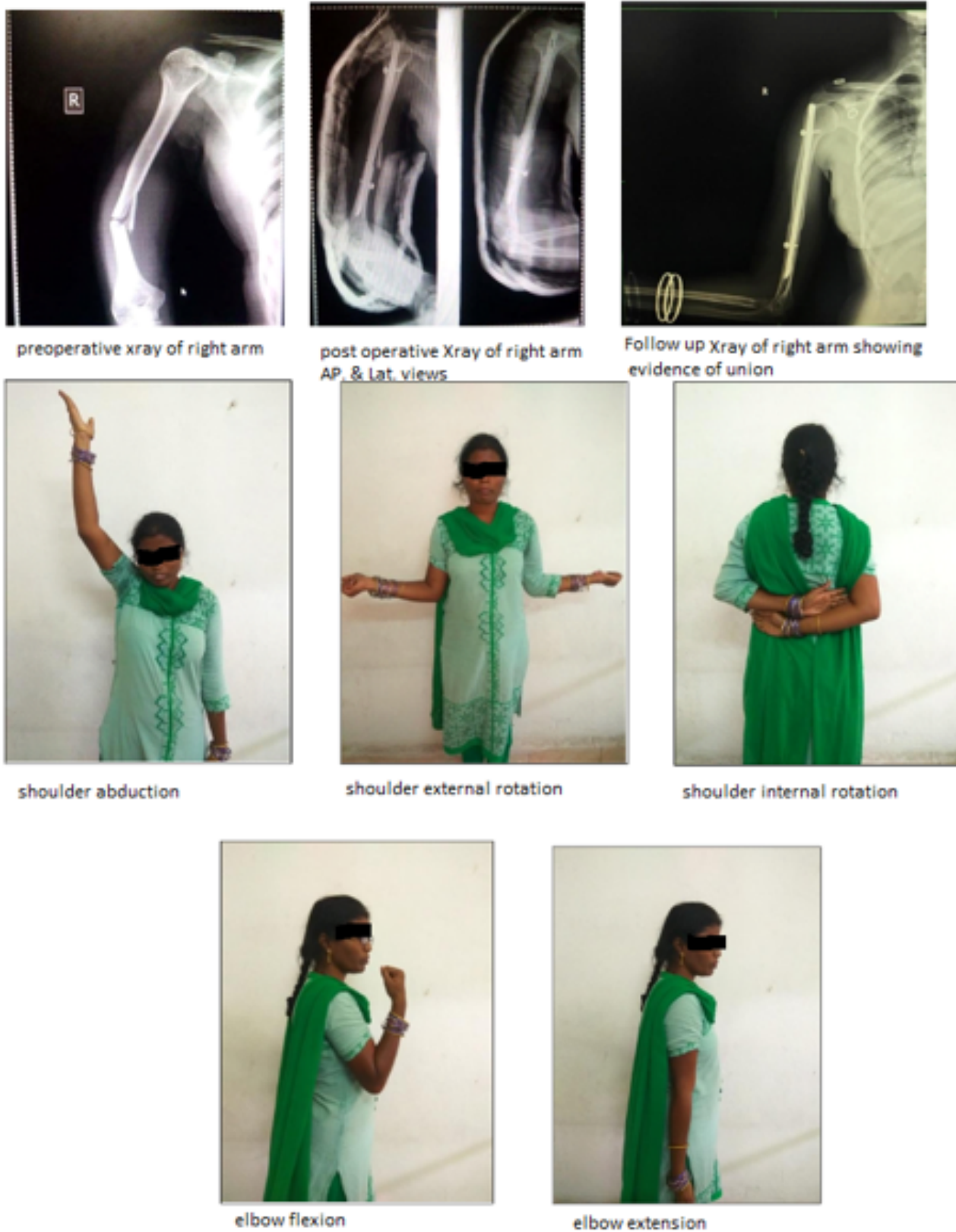


Fig. 5: Serial images of a case of fracture shaft of humerus managed with interlocking nail (ILN)

Table 2: Age Incidence

Age Group (years)	No. of Patients	Percentage
20-30	10	33.33%
31-40	7	23.33%
41-50	6	20.00%
51-60	5	16.66%
> 60	2	6.66%

Table 3: Sex Incidence

Sex	No. of Patients	Percentage
Male	20	66.66%
Female	10	33.33%

In this study, there is a male preponderance (66.66%) over females.

Table 4: Side Affected

Side Affected	No. of Patients	Percentage
Right	14	48.66%
Left	16	53.33%

In this study, the side affected most commonly is left (16; 53.33%).

Table 5: Mode of injury

Mode of Injury	No. of Patients	Percentage
RTA	23	76.66%
Accidental Fall	4	13.33%
Assault	3	10%

Out of 30 patients in this study, maximum number of fractures (23 cases) were due to RTAs.

Table 6: Level of Injury

Level of Injury	Klenerman's Type	No. of Patients	Percentage
Upper 1/3	Type-I	2	6.66%
Junction of Upper & Middle 1/3	Type-II	3	10.00%
Middle 1/3	Type-III	16	53.33%
Junction of middle & lower 1/3	Type-IV	9	30.00%

In this study, most of the cases are of type III level i.e. middle third fracture 16(53.33%).

In this study, most of the dynamic compression plating cases united within 10-15 weeks i.e., out of 15 cases, only 1 case took more than 15 weeks for union. And no non-unions were reported.

Out of 15 interlocking nailing cases, 13 cases united by 15 weeks and 2 cases took more than 15 weeks (comminuted fracture). No non-unions were reported

Table 7: Time taken for fracture union

No. of Weeks	Plating		Nailing	
	No. of Patients	Percentage	No. of Patients	Percentage
10 – 12 weeks	12	80.00%	10	66.66%
13 - 15 Weeks	2	13.33%	3	20.00%
16 – 18 Weeks	1	06.66%	2	13.33%
Non union	0	0.00%	0	0.00%

Table 8: Complications

Type of Complication	Plating		Nailing	
	No. of Patients	Percentage	No. of Patients	Percentage
Non union	0	0%	0	0%
Infection	2	6.66%	0	0%
Superficial				
Deep	0	0%	0	0%
Radial nerve injury	0	0%	0	0%
Shoulder stiffness	0	0%	3	20.00%
Elbow stiffness	0	0%	1	8.33%
Implant failure	0	0%	0	0%

In our study, 2 cases of superficial infection were noted in dynamic compression plating patients and the infection subsided with the use of antibiotics.

In patients treated with interlocking humerus, 3 developed shoulder stiffness and 1 of them developed elbow stiffness also.

Table 9: Functional outcomes according to Rommen's criteria

Grade	Plating		Nailing	
	No. of Patients	Percentage	No. of Patients	Percentage
Excellent	13	86.66%	10	66.66%
Good	2	13.33%	3	20.00%
Poor	0	0%	2	13.33%

4. Discussion

30 cases of fractures of the shaft of the humerus requiring surgical stabilization were prospectively randomized to undergo fixation by DCP (15) and intramedullary interlocking nail (15) over a period of two years in Mahatma Gandhi memorial hospital, Warangal. The purpose of this study was to compare the functional outcomes of both the methods of fixation in diaphyseal

fractures of humerus in these patients. They were followed up for an average period of 18 months.

We evaluated our results and compared them with those obtained by various standard studies. Our analysis is as follows:

Table 10: Age Distribution in various Studies

Study Series	Year	Total No. of Patients	Average Age
Robert J Foster et al ⁶	1985	84	39.5
Heim et al	1993	127	51.1
Mc Cormack et al ⁷	2000	44	49
Pratap Singh	2016	30	35.77
Present Study	2018	30	40.9

The average age in this series was 40.9 Years.

In 2016, in a study of 30 humeral fractures conducted by Pratap Singh⁸ in 2016, the average age was 35.77 years.

In another study of 127 fractures of the humeral shaft conducted by Heim et al,⁹ the average age was 51.1 years as compared to 40.9 years in our series.

Our study showed that the average age was similar to the reported studies when a smaller group of people were analyzed.

Table 11: Sex Incidence in Various Studies

Study series	Year	M : F Ratio	% of Males
Strong et al ¹⁰	1998	111 : 138	44.6%
Lin J ¹¹	1998	29 : 19	60%
Mc Cormack et al	2000	28 : 16	63.6%
Pratap Singh	2016	21:9	70%
Present Study	2018	20 : 10	66.6%

There were 20 male and 10 female patients, showing male preponderance in our study as comparable to the study done by Pratap Singh.

Table 12: Side Affected in various Studies

Study series	Year	Left	Right
Heim et al	1993	70	57
Lin J	1998	21	26
Strong et al	1998	139	110
Pratap Singh	2016	12	18
Present Study	2018	16	14

In our study, there was a slight preponderance towards the left side (16 cases) compared to the right side (14 cases), which was similar to Heim and Strong reported studies.

In our study, majority of the cases (23) sustained fractures from road traffic accidents. Most of the series reported that a high energy trauma was required to produce the fracture in younger patients and low energy trauma was the cause in elderly, who had osteoporotic bone.

Table 13: Mode of Injury in various Studies

Study series	Year	Total No. of Patients	Commonest Mode of Injury
Strong et al	1998	249	Falls
Tingstad et al ¹²	2000	44	RTA
MC Cormack RG	2000	44	RTA
Present Study	2018	30	RTA

Table 14: Site of fracture of various Studies

Study series	Year	Total No. of Patients	Commonest Site
L Klenerman et al	1966	98	M/3 rd
MI Bell et al ¹³	1985	38	U/3 rd & M/3 rd
J Lin	1998	48	M/3 rd
Strong et al	1998	249	M/3 rd
Present Study	2018	30	M/3 rd

In our series, in 16 cases (53.33%) the fractures were located in M/3rd of the shaft which was similar to most of the studies reported.

Table 15: Average time for union in various studies

Method	Study series	Year	Time
Plating	Robert J Foster	1985	14 weeks
	Pratap Singh	2016	12.22 weeks
	present study	2018	12 weeks
Nailing	Study	Year	Time
	Lin J	1998	8.6 weeks
Nailing	Pratap Singh	2016	11 weeks
	Present study	2018	12 weeks

The average time of union in the present study is 12 weeks both for plating and nailing.

In a study by Pratap Singh (2016) the average time of union for plating is 12.22 weeks and for nailing is 11 weeks which are close to the present study.

In our study of 30 cases, 1 case of plating showed delayed union but no non-unions were seen.

Cases of nailing have showed delayed union These were comminuted fractures treated with nailing.

But those comminuted cases treated with plating had showed good union without any delay in union. It indicates that comminuted cases are better treated with plating than nailing. Our study is closely comparable to the study by Pratap Singh (2016).

In our study, out of 15 patients treated with dynamic compression plate, 14 patients had good range of movements at the shoulder and elbow, but 1 patient developed stiffness of shoulder joint. In 15 patients treated with interlocking nail, 11 patients had good range of movements at shoulder and elbow, 4 patients had stiffness at shoulder and 1 of them

Table 16: Rate of Fracture union obtained in various Studies

	Study series	Year	Total No. of Patients	Delayed Union	Non-Union	Overall Result
Plating	Klenerman et al	1966	98	8	0	98
	RV Griend et al ¹⁴	1986	36	5	1	35
	Pratap Singh	2016	15	2	0	15
	Present Study	2018	15	1	0	15
	Study Series	Year	Total No. of Patients	Delayed Union	Non-Union	Overall Result
Nailing	Lin J	1998	48	3	0	48
	Rommens et al.	1995	39	2	1	38
	Pratap Singh	2016	15	3	0	15
	Present study	2018	15	3	0	15

Table 17: Range of Mobility of Elbow and Shoulder in various studies

	Study series	Year	Total No. of Patients	Good range of Mobility	Percentage
Plating	Bell MJ et al	1985	38	38	97%
	Mc Cormack et al	2000	44	44	100%
	Pratap Sigh	2016	15	15	100%
	Present Study	2018	15	14	93.33%
	Study series	Year	Total No. of Patients	Good range of Mobility	Percentage
Nailing	Lin J	1998	48	42	87.8%
	Pratap Singh	2016	15	10	66.67%
	Present study	2018	15	11	73.33%

Table 18: Overall results obtained in various Studies

	Study series	Year	Total No. of Patients	Method of Treatment	Excellent / Good Results
Plating	Heim et al	1993	127	DCP	83.4%
	Tingstad EM et al	2000	44	AO Plating	94%
	Pratap Singh	2016	15	DCP	96.86%
	Present Study	2018	15	DCP	99.99%
	Study series	Year	Total No. of Patients	Method of Treatment	Excellent / Good Results
Nailing	Lin J	1998	48	Nailing & plating	Nail>Plate 90%>86%
	Mc Cormack RG et al.	2000	44	Nailing and plating	Plate>Nail 97%>80%
	Pratap Singh	2016	15	Nailing	66.67%
	Present study	2018	15	Nailing	86.66%

had elbow stiffness also. In those 4 cases, 2 are comminuted fractures and we immobilized the patient's arm for longer duration than the other cases (due to delay in union)

Our results regarding range of mobility at shoulder and elbow joints are comparable with those of Bell's and Pratap Singh's study.

In our study, out of 15 patients treated with DCP, 13 patients (86.66%) had excellent results; 2 patients (13.33%) had good result.

Out of 15 patients treated with intramedullary interlocking nail, 10 patients (66.66%) had excellent results, 3 patients (20.00%) had good results and 2 patients

(13.33%) had poor result.

The present study is close to the outcomes of Lin's study.

5. Conclusion

We conclude that the transverse fractures of humerus shaft are better treated with antegrade intramedullary interlocking nail, and comminuted fractures shaft of humerus and also those cases with associated neuro-vascular or soft tissue injuries are better treated with plating. In acute diaphyseal fractures, no single fixation mode is superior in all circumstances and treatment of each case has to be

individualized. There appears to be no significant difference in radiological union, rate of union in both groups but, based on complications seen and functional outcomes noted, plating of humerus shaft fractures is a good fixation method.

Shortcomings in our studies include a small sample size and we have not taken retrograde nailing into consideration.

6. Source of Funding

No financial support was received for the work within this manuscript.

7. Conflict of Interest

The authors declare they have no conflict of interest.

References

1. Rockwood Green's – Fractures in Adults. In: and others, editor. 8th Edn.. vol. 1; 2015. p. 1087.
2. Balfour GW, Mooney V, Ashby ME. Diaphyseal fractures of the humerus treated with a ready-made fracture brace. *J Bone Joint Surg.* 1982;64(1):11–3. doi:10.2106/00004623-198264010-00002.
3. Schatzker J, Tile M. The rationale of operative fracture care . In: 3rd Edn.. vol. 15. Springer International;.
4. Hoppenfeld S, deBoer MP. Surgical exposures in Orthopaedics. In: 3rd Edn.; 2003. p. 68–84.
5. Rommens PM, Verbruggen J, Broos PL. Retrograde locked nailing of humeral shaft fractures. A review of 39 patients. *J Bone Joint Surg Br.* 1995;77-B(1):84–9. doi:10.1302/0301-620x.77b1.7822403.
6. Foster RJ, Foster GL, Dixon AW, Bach RW, Appleyard TM. Green-InternalFixation of Fractures & Non-Unions of the Humeral Shaft. *JBJS(Am).* 1985;67(6):857–64.
7. McCormack RG, Brien D, Buckley RE, Mckee MD, Powell J, of fractures of the shaft of the Humerus by Dynamic compression plate or Intramedullary nail J EHF, et al. Schemitsch-Fixation of fractures of the shaft of the Humerus by Dynamic compression plate or Intramedullary nail. *JBJS.* 2000;82:336–9.
8. Singh P, Gandhi V, Bansal D. Comparative Study of Compression Plating vs Interlocking Nail in Fracture Shaft of Humerus. *IJCMR.* 2016;3(11):3385–8.
9. Heim D, Herkert F, Hess P, Regazzoni P. Surgical treatment of humeral shaft fractures. *J Trauma.* 1993;35(2):226–32. doi:10.1097/00005373-199308000-00009.
10. Strong GT, Walls N, Queen MM. The epidemiology of humeral shaft fractures. *JBJS(Br).* 1998;80(2):249–53.
11. Lin J. Treatment of humeral shaft fractures with the humeral interlocked nail and comparison with plate fixation . *J Trauma .* 1998;44(5):854–9.
12. Tingstad EM, Wolinsky PR, Shyr Y, Johnson KD. Effect of Immediate Weightbearing on Plated Fractures of the Humeral Shaft. *J Trauma.* 2000;49(2):278–80. doi:10.1097/00005373-200008000-00014.
13. Bell MJ, Beauchamp CG, Kellam JK, McMurtry RY. The results of plating humeral shaft fractures in patients with multiple injuries. The Sunnybrook experience. *J Bone Joint Surg Bri.* 1985;67-B(2):293–6. doi:10.1302/0301-620x.67b2.3980544.
14. Vandergriend R, Tomasin J, Ward EF, Jackson M. Open Reduction & Internal Fixation of Humeral Shaft Fractures. *JBJS.* 1986;68(3):430–3.

Author biography

K Ram Mohan, Assistant Professor

K Kishore Kumar, Associate Professor

J Venkateshwarlu, Professor and Head

T Ashwin kumar, Post Graduate Student

B Pranav Krishna, Post Graduate Student

Cite this article: Mohan KR, Kishore Kumar K, Venkateshwarlu J, kumar TA, Krishna BP. Comparative study of functional outcome of dynamic compression plating and interlocking nailing for fracture shaft of humerus in adults. *Panacea J Med Sci* 2021;11(1):89-98.