



Original Research Article

The role of partial cystectomy in benign bladder conditions

Narendar Tiramdass^{1,*}, Sadhan Kumar¹, PVLN. Murthy¹, Vinay Kumar Reddy¹¹Dept. of Urology, Kamineni Institute of Medical Sciences, Narketpally, Nalgonda, Telangana, India

ARTICLE INFO

Article history:

Received 24-08-2020

Accepted 16-09-2020

Available online 29-04-2021

Keywords:

Partial cystectomy

Benign

Endometriosis

Bladder

Pheochromocytoma

ABSTRACT

Partial cystectomy is well known in the management of muscle invasive bladder cancer with specific indication. Partial cystectomy can be offered in the management of benign tumors like leiomyoma or pheochromocytoma. We report three rare benign conditions of bladder namely pheochromocytoma, endometriosis and ovarian dermoid eroding into the bladder. Very limited data was available indicating cystectomy for these benign diseases of bladder. The main objective of this report was its rarity and specific symptoms of these benign conditions. The second objective was to study the post-operative complications of the procedure for benign conditions and its impact on lower urinary tract symptoms in the long run. Partial cystectomy resulted in complete cure of these conditions and loss of bladder wall did not affect the lifestyle of these patients.

© This is an open access article distributed under the terms of the Creative Commons Attribution License (<https://creativecommons.org/licenses/by/4.0/>) which permits unrestricted use, distribution, and reproduction in any medium, provided the original author and source are credited.

1. Introduction

Cystectomy is most commonly used procedure for malignant bladder disorders since late 19th century. Partial cystectomy became a surgical option for selected cases of bladder cancer and for benign conditions like neurogenic bladder, interstitial cystitis, radiation cystitis.¹ Partial cystectomy can be an option for rare conditions like endometriosis of bladder, leiomyoma and pheochromocytoma.² Very few studies are available regarding the role of partial cystectomy for rare benign diseases. We report the role of cystectomy for 3 rare cases of benign diseases of bladder.

2. Case-I. Endometriosis of bladder

A 26-year-old female patient presented to the urology outpatient department with hematuria, suprapubic pain and dysuria of 3 months duration. She had a history of frequency, urgency, burning urination and suprapubic pain when the bladder was full. Her first child was delivered by cesarean section. Her second child died due to uterine rupture

for which she had undergone emergency hysterectomy after which she developed all these symptoms. On further evaluation her urine examination showed gross hematuria. Ultrasonography showed a mass lesion in the bladder. CECT abdomen showed an enhancing mass lesion of size of 5x4 cm in the dome of bladder which was deeply infiltrating (Figure 1). Cystoscopy was done and a nodular lesion was seen over the dome (Figure 2).

With the provisional diagnosis of endometriosis of bladder and medical management was given to the patient. Gonadotropin-releasing hormone (GnRH) analogues were given initially to control pain and hematuria for 6 weeks. But the mass did not regress. Then the patient had undergone partial cystectomy (Figure 3). Post-operative period was uneventful. Patient was symptomatically improved. Patient has been coming for follow-up since 2 years with no complaints.

Endometriosis of bladder is the presence of endometrial tissue outside the uterine cavity. Most commonly affected sites for endometriosis are the bladder (85%), ureter (9%), kidneys (4%), and urethra (2%).³ Partial cystectomy can be the treatment of choice for endometriosis based on severity of symptoms and extent of disease.⁴

* Corresponding author.

E-mail address: narendaruro@gmail.com (N. Tiramdass).

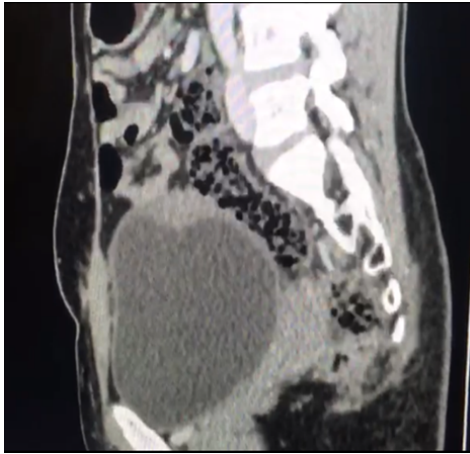


Fig. 1:

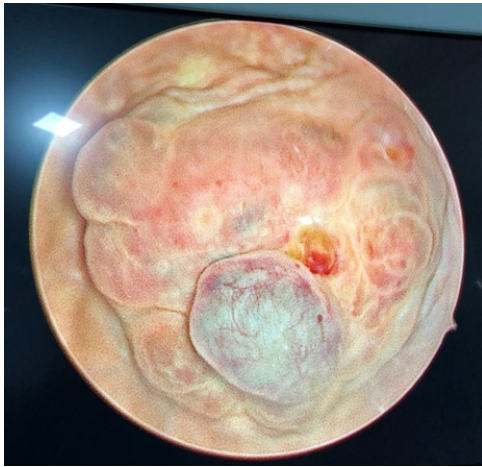


Fig. 2:

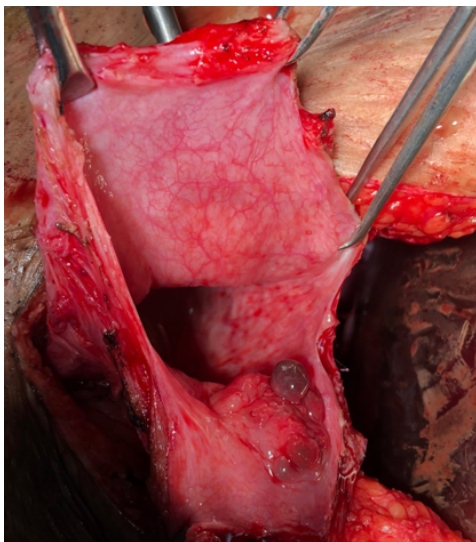


Fig. 3:

3. Case-II. Pheochromocytoma of bladder

Pheochromocytoma of bladder are exceedingly rare tumors accounting for less than 0.05% of all bladder tumors and less than 1% of all pheochromocytomas. In the genitourinary tract, urinary bladder is the most common site for pheochromocytomas (79.2%), followed by the urethra (12.7%), pelvis (4.9%), and ureter (3.2%).⁵

A 13yr old male child presented to the urology out patient with recurrent attacks of severe headache, palpitations, sweating after the act of micturition since 3 months. He also had Micturition Syncope (fainting at the end of the act of micturition). BP was 130/90. Past and perinatal history was insignificant. Investigations revealed a negative VMA, 24 hours urinary metanephrins were normal (129.72 microgms/day) and 24 hours urinary normetanephrins were elevated (1200mgms/day).

Ultrasonography showed a 2.4x1.1 cm sized hypoechoic well defined lesion with peripheral vascularity seen in the superior aspect of wall of urinary bladder. CECT abdomen showed crescentic shaped intensely enhancing hyperdense lesion closely abutting the anterosuperior aspect of the bladder, slightly towards right side of midline size of 1.2cmsx2.2cms x2.8cms (Figure 4). PET-CT done with 68Ga dotatate which is a specific tracer for neuroendocrine lesions showed tracer localization in the bladder wall lesion (Figure 5).

Cystoscopy showed nodular lesion in the bladder. Patient underwent partial cystectomy with provisional diagnosis of pheochromocytoma. Biopsy and immunohistochemistry markers (IHC and Chromogranin) confirmed the diagnosis (Figure 6). Post op period was uneventful. Patient has been in follow up since 5 years and doing well without any complications.

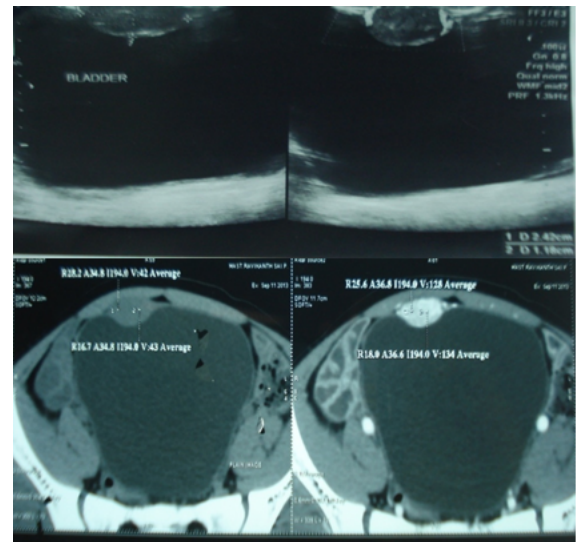


Fig. 4:

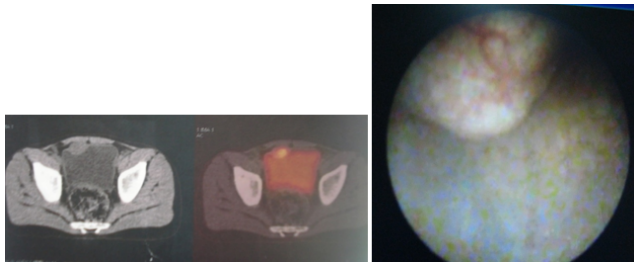
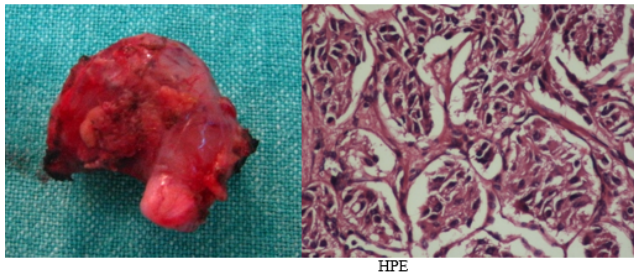
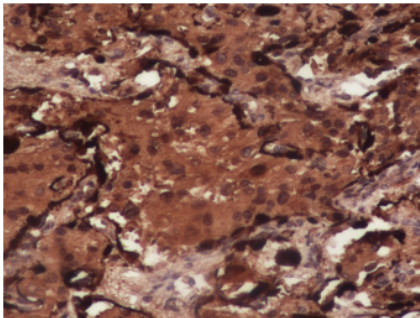


Fig. 5:



HPE



S100

Fig. 6:

4. Case-III. Ovarian dermoid eroding into bladder

A 21 years old female patient came to urology department with suprapubic pain, frequency, dysuria and urgency since 6 months. She had history of passing hair in the urine, occasionally since 6 months. On further evaluation, urine culture showed E.coli and treated for UTI. Ultrasonography showed right ovarian mass with vesical calculus. CECT Abdomen showed a 6*5 cm ovarian dermoid eroding into the bladder (Figure 7). On surgical exploration a dermoid cyst arising from right ovary adherent and eroding the bladder dome was noticed and partial cystectomy was done (Figure 8). The ovarian dermoid cyst showed a tuft of hair and a calculus adherent. The same was confirmed on histopathology. Post-operative period was uneventful. She was in follow up without any complaints last 3 years.

Ovarian dermoid cysts are germ cell tumours of ovary with malignant potential of 1-3%. Majority of them are asymptomatic and discovered incidentally. Due to complications like torsion, spontaneous rupture and chemical peritonitis, surgical removal of ovarian dermoid

cyst is advised.⁶

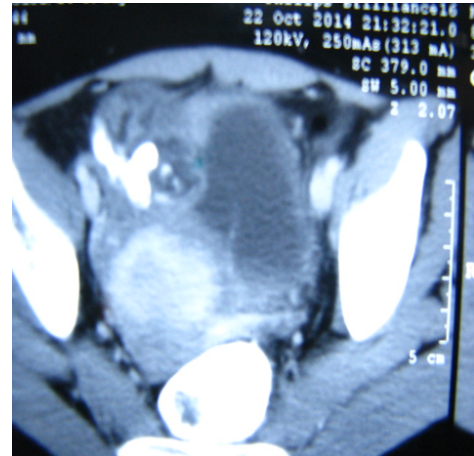


Fig. 7:

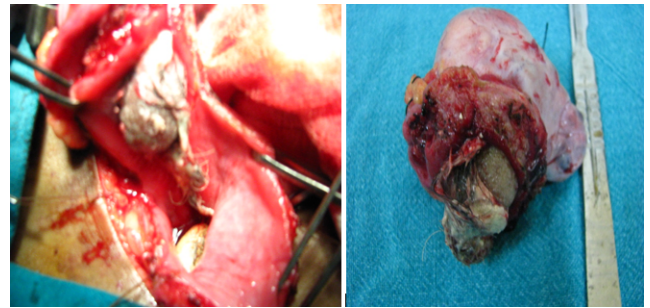


Fig. 8:

4.1. Complications of partial cystectomy for benign conditions

Patients undergoing partial cystectomy for benign bladder conditions will face as many complications as patients undergoing partial cystectomy for muscle invasive bladder cancer. Cohn et al found 73% complication rate following cystectomy in benign conditions in first 30 days duration. Most common complications of this procedure is urinary tract infection (23%) and wound infections (23%).⁷ A very limited data available regarding the complications of partial cystectomy for benign diseases.⁸ Rowley et al found a 39% late complication rate in 23 patients who underwent partial cystectomy for benign bladder conditions.⁹ In our study we did not find any postoperative complications. All 3 patients were recovered well with any complications till now.

5. Conclusion

All the benign conditions reported in this manuscript had distinct clinical features from which a proper diagnosis can

be made-micturition syncope in pheochromocytoma, history of hysterectomy and hematuria in endometriosis and passing hair in urine dermoid eroding the bladder.

Partial cystectomy resulted in complete cure and so is eminently suitable in the management of these benign conditions. We observed no complications of this procedure either early or late.

6. Acknowledgment

The author thankful to Department of Urology for providing all the facilities to carry out this work.

7. Source of Funding

No financial support was received for the work within this manuscript.

8. Conflict of Interest

The authors declare they have no conflict of interest.

References

- Osborn DJ, Dmochowski RR, Kaufman MR, Milam DF, Mock S, Reynolds WS, et al. Cystectomy With Urinary Diversion for Benign Disease: Indications and Outcomes. *Urology*. 2014;83(6):1433–7. doi:10.1016/j.urology.2014.02.030.
- Nagele U, Karl-Dietrich S, Merseburger AS, Anastasiadis AG, Stenzl A. Urinary Diversion Following Cystectomy. *EAU Update Ser*. 2005;3(3):138–46. doi:10.1016/j.euus.2005.07.003.
- Maggiore ULR, Ferrero S, Candiani M, Somigliana E, Viganò P, Vercellini P, et al. Bladder Endometriosis: A Systematic Review of Pathogenesis, Diagnosis, Treatment, Impact on Fertility, and Risk of Malignant Transformation. *Eur Urol*. 2017;71(5):790–807. doi:10.1016/j.eururo.2016.12.015.
- Sener A, Chew BH, Duvdevani M, Brock GB, Vilos GA, Pautler SE, et al. Combined transurethral and laparoscopic partial cystectomy and robot-assisted bladder repair for the treatment of bladder endometrioma. *J Minim Invasive Gynecol*. 2006;13(3):245–88. doi:10.1016/j.jmig.2006.01.014.
- Kozlowski PM, Mihm F, Winfield HN. Laparoscopic management of bladder pheochromocytoma. *Urology*. 2001;57(2):365–7. doi:10.1016/s0090-4295(00)00899-2.
- Nezhat RC, Kalyoncu S, Nezhat CH, Johnson E, Berlanda N, Nezhat F, et al. Laparoscopic Management of Ovarian Dermoid Cysts: Ten Years' Experience. *JSL*. 1999;3(3):179–84.
- Cohn JA, Large MC, Richards KA, Steinberg GD, Bales GT. Cystectomy and urinary diversion as management of treatment-refractory benign disease: The impact of preoperative urological conditions on perioperative outcomes. *Int J Urol*. 2014;21(4):382–6. doi:10.1111/iju.12284.
- Aisen CM, Lipsky MJ, Tran H, Chung DE. Understanding Simple Cystectomy for Benign Disease: A Unique Patient Cohort With Significant Risks. *Urology*. 2017;110:239–43. doi:10.1016/j.urology.2017.07.002.
- and WMR. Simple Cystectomy: Outcomes of a New Operative Technique. *Urology*. 2011;78(4):942–5.

Author biography

Narendar Tiramdas, Assistant Professor

Sadhan Kumar, Post Graduate

PVLN. Murthy, Professor

Vinay Kumar Reddy, Assistant Professor,

Cite this article: Tiramdas N, Kumar S, Murthy PVLN, Reddy VK. The role of partial cystectomy in benign bladder conditions. *Panacea J Med Sci* 2021;11(1):154-157.