



Case Report

Vanishing traumatic pneumocephalus – An alarm bell for the surgeon

Roopak Dubey^{1,*}, Kamal Kumar Sen¹, Mayank Goyal¹, D Sindhu Reddy¹,
Suma M K¹

¹Dept. of Radiodiagnosis, Kalinga Institute of Medical Sciences, Bhubaneswar, Odisha, India



ARTICLE INFO

Article history:

Received 20-10-2020

Accepted 29-10-2020

Available online 29-04-2021

Keywords:

Pneumocephalus

CSF rhinorrhea

Subdural haemorrhage

Sphenoid roof fracture

ABSTRACT

Pneumocephalus usually occurs because of a bony defect between the intracranial compartments and the paranasal sinus. We present a case of traumatic non tension pneumocephalus with accompanying subdural haemorrhage (SDH) and fractures of the roof of sphenoid sinus. We noticed complete resolution of pneumocephalus with in a day on repeat CT head done on the next day. Significant resolution of SDH was also noted. This was unexpected as usually it takes 2-3 weeks for the complete resolution of non tension pneumocephalus. We assume that fracture in the roof of sphenoid sinus lead to CSF and haemorrhagic leakage through the sphenothmoidal recess located within the superior meatus. This was unusual as CSF leakage is itself a cause of development of pneumocephalus when intracranial pressure is expected to increase, according to Ball Valve theory. So, the resolution of pneumocephalus was before the development of sufficient intracranial pressure to cause Ball valve effect. Hence, a complete resolution of a significant pneumocephalus and prompt regression of SDH in head injuries, with in few hours, should raise an alarm to exclude the possible association of CSF rhinorrhoea.

© This is an open access article distributed under the terms of the Creative Commons Attribution License (<https://creativecommons.org/licenses/by/4.0/>) which permits unrestricted use, distribution, and reproduction in any medium, provided the original author and source are credited.

1. Introduction

Pneumocephalus is a collection of air within the intracranial cavity and is a common finding following traumatic skull fractures and neurosurgical procedures with head trauma accounting for approx 80% of all the cases.^{1,2} Generally, it occurs when there is communication between intracranial compartment and cranial sinuses through a bony defect. The term 'Tension pneumocephalus' is used when pneumocephalus progresses up to a level where it starts creating intracranial hypertension leading to mass effect and neurological deficit.³ Mount Fuji sign develops when tension pneumocephalus leads to the frontal hemispheres compression, accompanied by interhemispheric space widening, giving a peaked appearance caused by intact bridging veins and this phenomenon is considered as a neurosurgical emergency.^{4,5} Early recognition of pneumocephalus by radiologists and emergency physicians,

with prompt neurosurgical consult and consideration of antibiotics prevent further complications. Usually, with proper conservative management, reabsorption of non-tension pneumocephalus was observed in 85% of cases in 2–3 weeks.⁶

However, in our study, complete resolution of a large pneumocephalus and subdural haemorrhage (SDH), in a patient with severe head injury, within a day was paradoxical and warranted a further exploration.

2. Case Report

A 64 years old male patient presented to the emergency department with a history of fall from height (Approx -6 ft) on to the hard surface with direct impact over shoulder and forehead. He was vomiting and bleeding from nose. There was no evidence of major open wound, although smaller bruises and scratches were noted mainly over face and forehead region. Patient was irritable and disoriented with a GCS score of E₂V₂M₄ at the time of admission. There

* Corresponding author.

E-mail address: roopak21dubey@gmail.com (R. Dubey).

was no history Hypertension or Diabetes.

Axial images of the brain on a Computed Tomographic scan (CT) showed acute subdural hemorrhage (SDH) of maximum thickness 16 mm along the right fronto-temporal convexity, with multiple air foci within it and mass effect was noted in the form of mild compression of right lateral ventricle and midline shift of 6 mm to the left. In addition acute subarachnoid hemorrhage (SAH) was noted along cortical sulci of bilateral frontal, right temporal and left occipital regions. Extensive pneumocephalus was seen along bilateral fronto-temporal convexity, falx, bilateral sylvian fissures, along peri-mesencephalic, ambient and quadrigeminal cisterns. Undisplaced longitudinal fracture of left temporal bone along with fracture of roof of bilateral sphenoid sinuses was seen with hemosinus within.

The patient was managed conservatively in neurosurgery ICU with proper bed rest and placing the patient in 30 degrees Fowler position. High flow oxygen therapy was given through a non-rebreather mask with absolute avoidance of positive pressure. Endotracheal tube suction revealed presence of blood in the collected fluid. Patient was advised to avoid valsalva maneuver like nose blowing, coughing and sneezing. He improved dramatically in his neurological status. A follow up CT scan was undertaken after 16 hours of the first scan. There was considerable reduction in the thickness of SDH (11mm) and decreased midline shift (3mm). There was complete resolution of pneumocephalus (Figure 1).

The patient was managed conservatively for SDH and SAH and was discharged in a neuro and hemodynamically stable state after 3 weeks.

3. Discussion

During head injury or after cranial surgeries, dura may be opened or torn with or without injury to arachnoid leading to the entry of air inside the cranial cavity. The two possible mechanisms for pneumocephalus development have been described in the literature.⁷ One is the ball valve effect characterised by the unidirectional movement of air from the outside environment into the cranial cavity. In this, entry of air occurs from the extra cranial space via CSF leakage. Consequent increase in intracranial pressure, the brain and the dura block the fistulous tract and hence prevents air from going out, leading to accumulation of air within intracranial cavity. Another theory is known as the inverted soda bottle effect. According to this theory, excessive loss of CSF leads to low intracranial pressure and trapping of air in the vacuum created inside the cranium. Air enters as bubbles due to negative pressure, replacing the CSF and balancing the pressure in the two cavities. Rarely associated infection by gas forming bacteria leads to production of gas in situ.⁸

After skull base injury the chances of tension pneumocephalus increases with sneezing, cough, vomiting

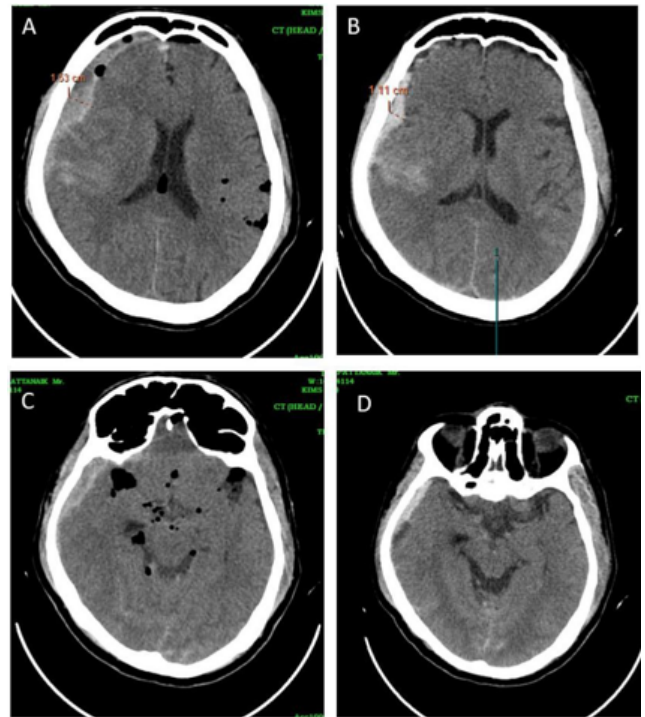


Fig. 1: A: Mild resolution of SDH complete resolution of foci of pneumocephalus in a follow up scan; B: done after 16 hours; C and D: Complete resolution of scan seen in repeated scan; D: After 16 hours

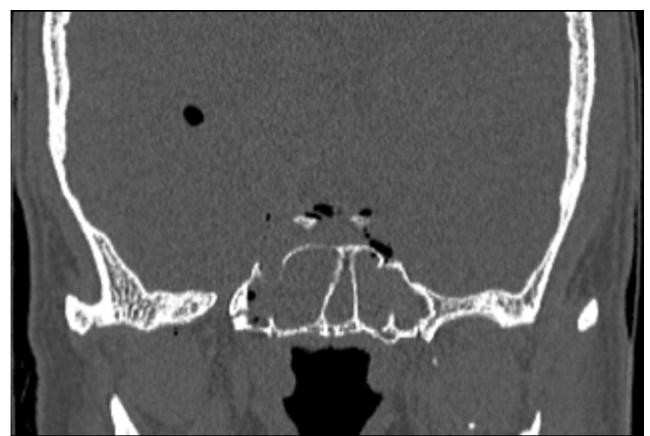


Fig. 2: CT head coronal section shows fractures in the roof of sphenoid sinus

which create pressure changes that allows air to enter the intracranial cavity from outside through a defect. Tension pneumocephalus can be differentiated from simple pneumocephalus as former usually presents in the form of headache, convulsions, anxiety, delirium, reflex & cognitive abnormalities and brain stem herniation in serious cases.⁹ Therefore, it is necessary to differentiate a tension pneumocephalus from a non-tension pneumocephalus as decompressive surgery is not needed in latter.

CT-scan is considered as the gold standard imaging modality for pneumocephalus which detects the presence of air due to the density differences between air, fluid, tissue and bone. CT-scan detects the amount and location of air and fluid, presence of a fractures and the effect of pneumocephalus on the brain.¹⁰

In this patient, reduction in size of SDH and complete resolution of pneumocephalus in 16 hours was puzzling. Rapid and complete resolution of pneumocephalus was unexpected and since we were dealing with a non-tension pneumocephalus the usual expected time for recovery after proper conservative management would have been 2 to 3 weeks but ,interestingly, in this case it was just a day. A possibility of associated CSF Rhinorrhoea was raised for further specific management. The haemorrhagic fluid sucked through ET tube was in all probability mixed with CSF. We assumed that In this case the cause of entry of air into the cranial cavity was the fracture in the roof of sphenoid sinus leading to CSF and haemorrhagic leakage through the sphenoidal recess located within the superior meatus (Figure 2). Usually CSF leakage is itself a cause of development of pneumocephalus when intracranial pressure is expected to increase, according to Ball Valve theory. But in this case there was a rapid exit of air from the cranial cavity. We assume that such a fast exit of air could be due to severe CSF rhinorrhea and could only be possible if that happened before the development of sufficient intracranial pressure to cause Ball Valve effect. Thus, such a rapid resolution of pneumocephalus should raise the possibility of severe CSF rhinorrhea and may require further ENT guidance and modification in usual management of pneumocephalus. These patients may require trans-cranial or endoscopic guided surgical procedures for CSF leakage repair as the chances of severe rhinorrhea in such cases of rapidly resolving pneumocephalus remains very high.

4. Conclusion

A complete resolution of a significant pneumocephalus and prompt regression of SDH in head injuries, with in few hours, should raise an alarm to exclude the possible association of CSF rhinorrhoea. Typically, patients will notice the problem when bending forwards. Thus, the condition is invariably missed since the patient would be disoriented or comatose and lying in a supine position. Hence, rapidly resolving pneumocephalus can act as an

“Alarm bell” for surgeons guiding towards severe CSF rhinorrhea thus early and prompt management of the same. An early follow up CT Scan in such condition could be a valuable indicator.

5. Consent

Written informed consent was obtained from the patient for publication of this case report and accompanying images. A copy of the written consent is available for review by the Editor-in-Chief of this journal.

6. Source of Funding

No financial support was received for the work within this manuscript.


7. Conflict of Interest

The authors declare they have no conflict of interest.

References

1. Toung TJK, Mcpherson RW, Ahn H. Pneumocephalus: effects of patient position on the incidence and location of aerocele after posterior fossa and upper cervical cord surgery. *Anesth Analg.* 1986;65:65–70.
2. Tintinalli JE. Emergency Medicine: A Comprehensive Study Guide. In: Specific head injuries. vol. 14. McGraw-Hill Education; p. 1701–4.
3. Dowd GC, Molony TB, Voorhies RM. Spontaneous otogenic pneumocephalus. Case report and review of the literature. *J Neurosurg.* 1998;89:1036–9.
4. Heckmann J, Ganslandt O. The Mount Fuji sign. *New Engl J Med.* 2004;350:1881.
5. Gokmen IE, Keskin S, Kırsi D, Erdoğan H. Mount Fuji sign following surgical drainage of spinal epidural abscess: Figure 1. *QJM-Int J Med.* 2015;108(10):835–6. doi:10.1093/qjmed/hcv078.
6. Karavelioglu E, Eser O, Haktanir A. Pneumocephalus and Pneumorrhachis after Spinal Surgery: Case Report and Review of the Literature. *Neurol Med Chir.* 2014;54(5):405–7. doi:10.2176/nmc.cr2013-0118.
7. Dandy WE. Pneumocephalus. Pneumocephalus (intracranial pneumatocele or aerocele). *Arch Surg.* 1926;132:949–82.
8. Penrose-Stevens A, Albrahim, Redfern R. Localized pneumocephalus caused by Clostridium perfringens meningitis. *Br J Neurosurg.* 1999;13:85–6.
9. Sadler DJ, Doyle GJ, Hall K. Cranio-cervical bone pneumatization. *Neuroradiology.* 1996;38:330–2.
10. Webber-Jones JE. Tension Pneumocephalus. *J Neurosci Nurs.* 2005;37(5):272–6. doi:10.1097/01376517-200510000-00007.

Author biography

Roopak Dubey, Post Graduate Resident  <https://orcid.org/0000-0002-2185-6639>

Kamal Kumar Sen, Professor and HOD

Mayank Goyal, Post Graduate Resident

D Sindhu Reddy, Post Graduate Resident

Suma M K, Post Graduate Resident

Cite this article: Dubey R, Sen KK, Goyal M, Reddy DS, Suma M K. Vanishing traumatic pneumocephalus – An alarm bell for the surgeon. *Panacea J Med Sci* 2021;11(1):161-164.