

Adenoid Cystic Carcinoma: A Case Report

Monisha Batra^{1*}, Seema Sharma², Parul Jhamb³, Kanika Bhalla Prabhat⁴, Geeta Sharma⁵, Manu Gupta⁶

Department of Oral and Maxillofacial Pathology & Microbiology, Santosh Dental College, Santosh University Ghaziabad

*Corresponding author:

Email: monishabatra14@gmail.com

ABSTRACT

Adenoid cystic carcinoma (ACC) is a diagnostic challenge owing to its rarity of occurrence. It is considered as one of the intermediate grades of salivary gland neoplasms. ACC is characterized by slow growth, which causes extensive invasion and aggressive ability for early metastatic deposits. This article describes a case of adenoid cystic carcinoma involving the right side of the hard palate.

Key Words: Adenoid Cystic Carcinoma, Palatal Tumors, Salivary Gland Neoplasm

INTRODUCTION

Adenoid cystic carcinoma is a relatively rare malignant salivary gland neoplasm comprising less than 1% of all malignancies of head and neck. It is the 5th most common malignancy of salivary glands^{1,2}. More than 55% of the adenoid cystic carcinoma cases have been reported in the parotid gland and submandibular gland. The palate is the most common site of occurrence in 50% cases of adenoid cystic carcinoma involving minor salivary glands. The adenoid cystic carcinoma accounts for 8.3% of minor salivary gland tumours and 17.7% of malignant salivary gland tumors of the palate. The other sites of occurrence are lower lip, retromolar area, tonsillar pillar area, sublingual gland, the floor of the mouth and buccal mucosa².

Adenoid cystic carcinoma is common in middle-aged adults and is rare in people younger than 20 years of age. There is a fairly equal sex distribution, although some studies have shown a slight female predilection³. Clinically the tumor is often deceptive due to its small size and benign growth having extensive subclinical invasion and a marked tendency for early metastasis which has an unpredictable prognosis⁴. Patients often complain of a constant, low-grade, dull ache, which gradually increases in intensity. Facial nerve paralysis may develop with parotid variants. Tumours involving the palate can be smooth surfaced or ulcerated³.

Histologically, adenoid cystic carcinoma has three main patterns; cribriform type, solid type, and tubular type. The cribriform type is the most common while solid is the least common. Szanto et al graded adenoid cystic carcinoma as cribriform or tubular (grade I), less than 30% solid (grade II) or greater than 30% solid (grade III)⁵. The main reason for this histological typing is to assess the prognostic difference between histologic types. The tubular pattern is believed to have the best prognosis compared to the cribriform pattern and solid pattern⁶.

Histopathology and Grading of the Tumour⁷

Growth patterns and cytological details in ACC establish the diagnostic criteria and grading for this neoplasm. These primary three growth patterns are seen in adenoid cystic carcinoma:

- a. **Cribriform variant:** Characterized by islands of basaloid epithelial cells that contain multiple cylindrical, cyst like spaces resembling Swiss cheese. These spaces often contain a mildly basophilic mucoid material, a hyalinized eosinophilic product, or a combined mucoid hyalinized appearance. Sometimes the hyalinized material also surrounds these cribriform islands, or small strands of tumor are found embedded within this "hyalinised" stroma. These cells are fairly uniform in appearance, and mitotic activity is rarely seen.
- b. **Tubular variant:** Tumour cells occur as multiple small ducts or tubules within a hyalinised stroma. The tubular lumina can be lined by one to several layers of cells and sometimes, both ductal cells and myoepithelial cells may be seen.
- c. **Solid variant:** Consists of large islands or sheets of tumor cells that demonstrate little tendency towards duct or cyst formation. Cellular pleomorphism, focal necrosis and mitotic activity can be seen in this variant.

Grading of the Tumour⁸

- a. **Grade I:** The tumour consisting only of the cribriform and tubular pattern.
- b. **Grade II:** A mixture of cribriform, tubular and solid growth patterns, but solid growth pattern less than 30% of the tumour.
- c. **Grade III:** Tumours with predominantly solid growth pattern. (>30% or more of the tumour). The

most important prognostic factors include primary lesion size (T), anatomical localization, presence or absence of metastasis (M) at diagnosis time, invasion of the facial nerve and the histopathology grade (G).

CASE REPORT

A 25-year-old male patient reported to the Department of Oral and Maxillofacial Pathology, Santosh Dental College and Hospital, Ghaziabad, with a chief complaint of swelling on the palate for the past 5-6 months.

The nature of pain was constant, dull aching, with a feeling of numbness on the palatal mucosa. Medical, dental or personal history was recorded and nothing abnormal was seen.

Patient was conscious, cooperative, average in built and all the vital signs were within normal limits on the day of the presentation.

On intraoral inspection, a swelling was seen on the hard palate extending from the mid-palatine raphe to the third molar region posteriorly on the right side of the mouth measuring about 2X 1.5 cm in size. The overlying mucosa was ulcerated. On palpation, the swelling was firm in consistency and fixed to the underlying structures (Fig. 1).

Radiographic examination revealed an expansile mass associated with bony destruction noted in the alveolar process of the right maxilla.

A differential diagnosis of central giant cell granuloma, mucoepidermoid carcinoma and pleomorphic adenoma was made.

An excisional biopsy was performed and the tissue was sent to the Department of Oral pathology for histopathological evaluation.

The H & E stained section showed basaloid epithelial cells arranged in islands that contain multiple cyst like spaces filled with basophilic mucoid material resembling the "Swiss Cheese" pattern. This kind of appearance resembles the "Cribriform Pattern" of adenoid cystic carcinoma (Fig. 3). At certain foci, the tumor cells were arranged in the shape of tubules lined by one or several layers of ductal and myoepithelial cells resembling the "Tubular Pattern" (Fig. 4). Also certain foci showed the tumor cells arranged in sheets depicting the "Solid Pattern" (Fig. 2). On the whole, the cribriform pattern was predominant. The connective tissue stroma was fibrous with spindle shaped cells and flattened nucleus depicting the fibroblasts cells. Adipose cells were also appreciated in the stroma consisting of basophilic nuclei pushed towards the periphery and clear cytoplasm. Few lymphocytes were also appreciated which were round with intensely basophilic nuclei covering the cytoplasm. Few blood vessels lined by flat endothelial cells were also appreciated with infiltrating red blood cells.

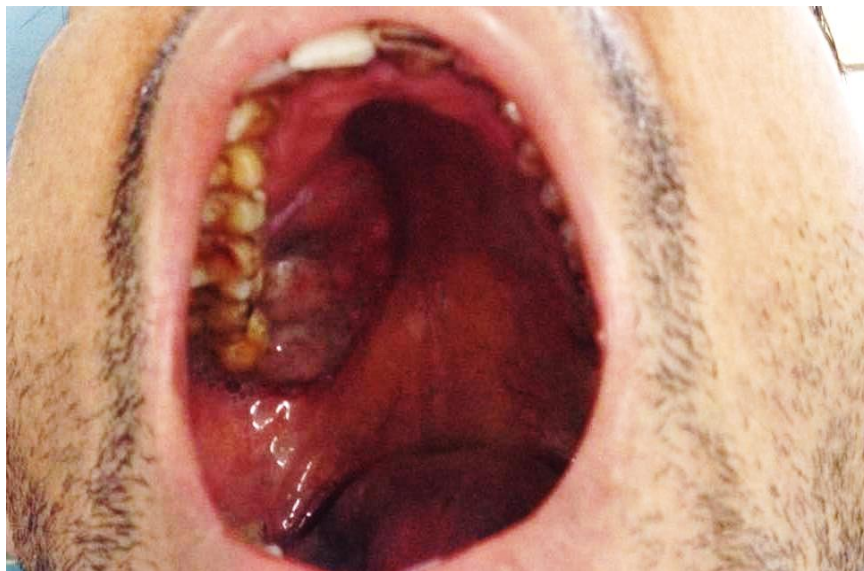

Fig. 1: Palatal swelling on the right side extending posteriorly

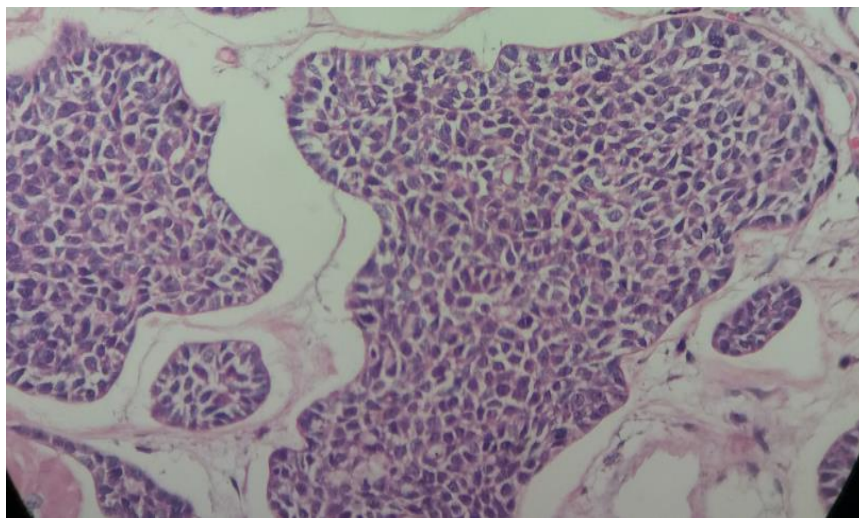


Fig. 2: Solid Pattern showing sheets of tumor cells (40X)

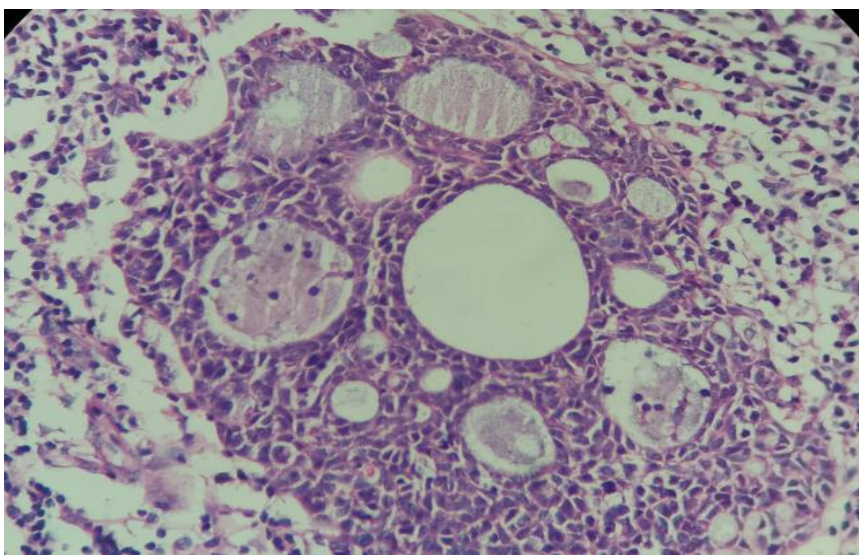


Fig. 3: Cribriform Pattern tumor cells showing the "Swiss Cheese" pattern(40x)

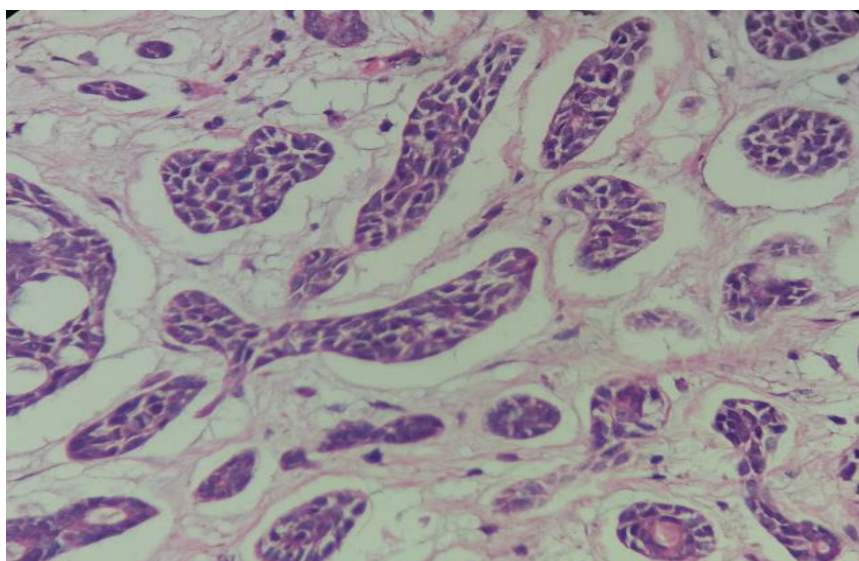


Fig. 4: Tubular Pattern cells showing multiple small ducts or tubules in connective tissue stroma

DISCUSSION

ACC was first described by Billroth in 1859 as a malignant salivary gland tumour⁹. He described it as cylindroma due to the cribriform appearance of tumor cells. The term adenoid cystic carcinoma was introduced by Ewing (Foote and Frazell) in 1954³.

Adenoid cystic carcinoma most often presents as a diagnostic and treatment challenge owing to the rarity of occurrence. Most findings reported in the literature about adenoid cystic carcinoma are actually based on studies of a small number of patients and therefore, further extensive studies are required regarding its clinical behavior, treatment modalities and prognosis¹⁰.

ACC can occur in any salivary gland but, approximately 50-60% develops within minor salivary glands. The palate being the most common site for minor salivary gland tumors. The other tumours sites are parotid and submandibular glands with fairly even distribution in these two sites³. The tumour affects men and women equally and usually occurs in the fifth decade of life¹¹, but in the present case, the patient was 25 years old.

The minor salivary glands of the palate in greater palatine foramen area are the most predicted site of occurrence for adenoid cystic carcinoma. The present case has its presentation on the right maxilla. The most common malignant salivary neoplasm of minor salivary glands is mucoepidermoid carcinoma (21.8%), followed by polymorphous low-grade adenocarcinoma (7.1%) and adenoid cystic carcinoma (6.3%) being the third most common^{12,13}.

The differential diagnosis of adenoid cystic carcinoma includes polymorphous low-grade adenocarcinoma, basal cell adenoma, mixed tumor and basaloid squamous cell carcinoma. The cribriform pattern seen in adenoid cystic carcinoma can be seen in basal cell adenoma, mixed tumor, and polymorphous low-grade adenocarcinoma.

Ki-67 index is reported to be 10 times higher in adenoid cystic carcinoma as compared to polymorphous low-grade adenocarcinoma. Smooth muscle markers of myoepithelial differentiation are positive in adenoid cystic carcinoma but negative in polymorphous low-grade adenocarcinoma¹⁴. The expression of E-cadherin is used as a prognostic marker for adenoid cystic carcinoma while the degree of metastasis is determined by the count of high argyrophilic nucleolar organizing regions (AgNOR).

The prognosis of adenoid cystic carcinoma is predicted by the location of the lesion, primary lesion size, metastasis present or not, perineural invasion and histological variant¹⁵. Distant metastasis is reported to occur in 25-50% of the cases; most common site being the lung with a survival rate of 5 years is 75%.

In our case, the clinical presentation of the tumor was deceptive and was considered as a pleomorphic adenoma. Tubular pattern is believed to

have the best prognosis as compared to cribriform and solid pattern⁶. In our case; all three histopathologic variants were seen with a predominant cribriform pattern making the prognosis questionable.

BIBLIOGRAPHY

1. Matsuba HM, Spector GJ, Thawley SE, Simpson JR, Mauney M, Pikul FJ. Adenoid cystic salivary gland carcinoma. A histomorphologic review of treatment failure patterns. *Cancer*.1986;67:519-24.
2. Spiro RH, Huvos AG, Strong EW. Adenoid cystic carcinoma: factors influencing survival. *Am J Clin Pathol*.1979;138:579-83.
3. Neville, Damm, Allen, Bouquot; Oral and Maxillofacial Pathology, second edition, page: 427.
4. Marx RE, Stern D. Chicago: Quintessence; 2002. Oral and Maxillofacial Pathology, A rational for diagnosis and management: 482-6.
5. Szanto PA, Luna MA, Tortoledo ME, White RA. Histologic grading of adenoid cystic carcinoma of the salivary glands. *Cancer*. 1984;54:1062-9.
6. Gnepp DR, Henley JD, Roderick HW, Simpson, Eveson J. Salivary and lacrimal glands. In: Gnepp Douglas R., editor. *Diagnostic surgical pathology of the Head and Neck*. 2nd ed. Philadelphia: Saunders; 2009. pp. 482-6.
7. Neville, Damm, Allen, Bouquot; Oral and Maxillofacial Pathology, Second Edition, page: 496. Batsakis JG, Luna MA, el-Naggar A, Histopathologic grading of salivary gland neoplasms: III. Adenoid cystic carcinomas. *Ann OtolRhinolLaryngol*. 1990;99(12):1007-9.
8. Lucas RB. 4th ed. London: Churchill Livingstone; 1998. Pathology of tumors of the oral tissues; pp. 330-5.
9. Grahne B, Lauren C, Holsti LR. Clinical and histological malignancy of adenoid cystic carcinoma. *J Laryngol Otol*. 1977;91:743-9.
10. Bradley , J. C. A case of cy: indroma of the mandible. *British Journal of Oral Surgery* 1968;5:186-193.
11. Buchner A, Merrell PW, Carpenter WM. Relative frequency of intra oral minor salivary gland tumors: A study from northern California and comparison to reports from other parts of the world. *J Oral Pathol Med*. 2007;36:207-14.
12. Hashemi Pour MS, Zarei MR, Chamani G, Rad M. Malignant salivary glands tumors in Kerman province: A Retrospective Study. *Dent Res J*. 2007;4:4-10.
13. Prasad AR, Savera AT, Gown AM. The myoepithelial immunophenotype in 135 benign and malignant salivary gland tumors other than pleomorphic adenoma. *Arch Pathol Lab Med*. 1999;123:801-6.
14. Barrett A, Speight P. The controversial adenoid cystic carcinoma. The implications of histological grade and perineural invasion. In: McGurk M, Renehan A, editors. *Controversies in the management of salivary gland disease*. Oxford: Oxford University Press; 2002. pp. 211-7.