



## Original Research Article

# Trans-nasal endoscopic repair without stenting in bilateral congenital bony choanal atresia: Our technique

Deepa Shivnani<sup>1,\*</sup>, E V Raman<sup>2</sup>, Dnyansh Amle<sup>3</sup>

<sup>1</sup>Dept. of Pediatric Otorhinolaryngology, Manipal Hospital, Bangalore, Karnataka, India

<sup>2</sup>Dept. of Otorhinolaryngology, Manipal Hospital, Bangalore, Karnataka, India

<sup>3</sup>Dept. of Biochemistry, All India Institute of Medical Sciences, Nagpur, Maharashtra, India



## ARTICLE INFO

## Article history:

Received 18-05-2021

Accepted 11-06-2021

Available online 14-07-2021

## Keywords:

Bony choanal atresia

Trans-nasal endoscopic approach

Stenting in choanal atresia.

## ABSTRACT

**Background:** Choanal atresia is a commonly observed congenital nasal abnormality. Incidence of choanal atresia is 1 in 7,000 live births. There are various techniques which has been described for the choanal atresia repair. Here we are sharing step by step trans-nasal technique to get good results post-operatively.

**Aim:** The aim of this study to explain and share the technique to treat a bony choanal atresia without any stenting in the nasal cavity of a neonate. The purpose of this study to analyse the surgical outcome of single stage bony choanal atresia repair in terms of restenosis and revision surgery.

**Technique:** We have described the step by step approach for the repair of bony choanal atresia without using any stent in the nasal cavity. Pre surgery evaluation and surgical steps have been explained with photograph to understand this technique better.

**Conclusion:** Bony choanal atresia can be treated without any stent placement which was the most common method for the repair of congenital choanal atresia in neonates. Clinical significance: This technique will reduce the chances of complication which arises because of stenting in the nasal cavity. This technique is simple and easily reproducible in the practise.

© This is an open access article distributed under the terms of the Creative Commons Attribution License (<https://creativecommons.org/licenses/by/4.0/>) which permits unrestricted use, distribution, and reproduction in any medium, provided the original author and source are credited.

## 1. Background

Infants with bilateral Choanal Atresia (CA) can present as an airway emergency at birth. The goal of initial treatment is to maintain an adequate airway.<sup>1</sup> Incidence of choanal atresia is around 1 in 7,000 live births<sup>2</sup> It is a potential life threatening condition in neonates because this condition is predominantly in first 6 weeks of births<sup>3</sup>. 65–75 % of patients with choanal atresia are unilateral, and the rest are bilateral<sup>4</sup> There are five different approaches described for surgical treatment of CA: (1) trans-nasal, (2) trans-palatal, (3) trans-antral, (4) trans-septal and (5) sublabial–transnasal.<sup>5,6</sup> Our objective is to report our experience in Trans-nasal Endoscopic Minimal Invasive Technique without stenting for the surgical management of CA.

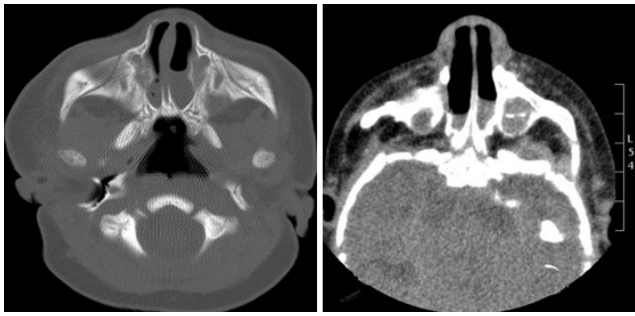
## Technique

1. This case series includes 6 children who presented or referred to our Hospital with congenital bilateral CA between October 2015 to July 2017. Institutional Review Board approval was taken. We used a Trans-nasal Endoscopic Minimal Invasive Technique without stent placement. It is based on the following steps

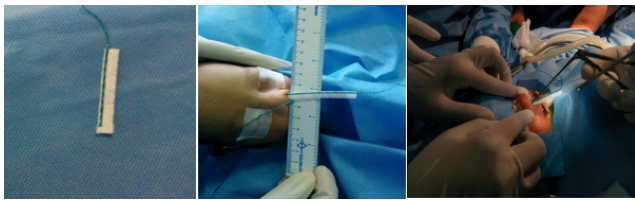
2. Stents and nasal packs were not placed in any case. No topical mitomycin or corticosteroids were applied. Postop care: Antibiotic Therapy, Nasal Saline Spray at least twice a day for several weeks were recommended. Patients underwent a regular follow-up to wash away crusts and secretions and verify choanal patency. All patients were followed up at-least for 18 months.

\* Corresponding author.

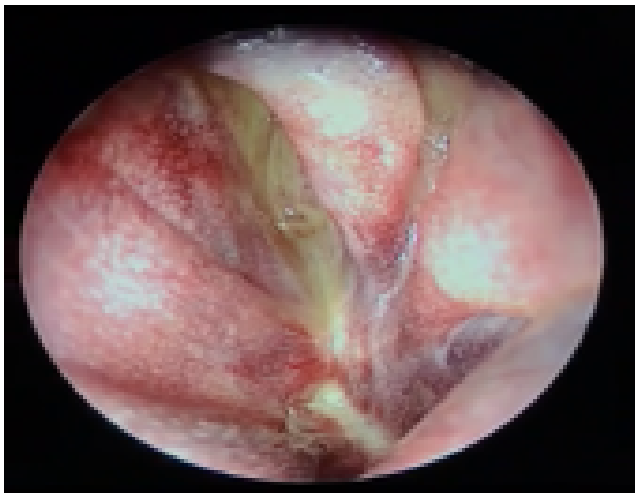
E-mail address: [deepa.shivnani14@gmail.com](mailto:deepa.shivnani14@gmail.com) (D. Shivnani).



**Fig. 1:** Step 1: CT scan images were evaluated to assess the thickness of atretic plate.



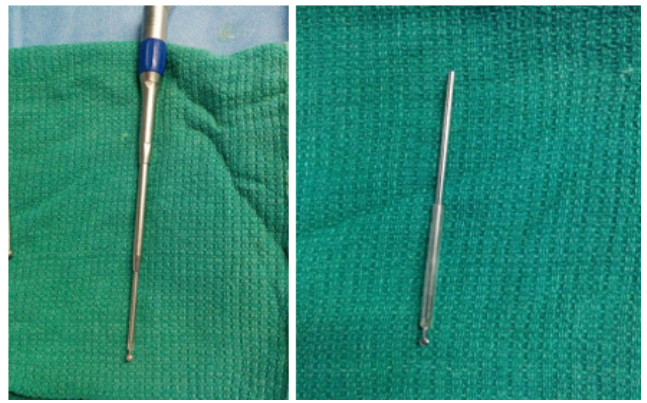
**Fig. 2:** Step 2: After the positioning and draping, the nose is topically decongested with vertically cut neuro-patty soaked in decongestant solution (1 ampoule adrenaline, 30 cc saline with 10 drops of .025% oxymetazoline)



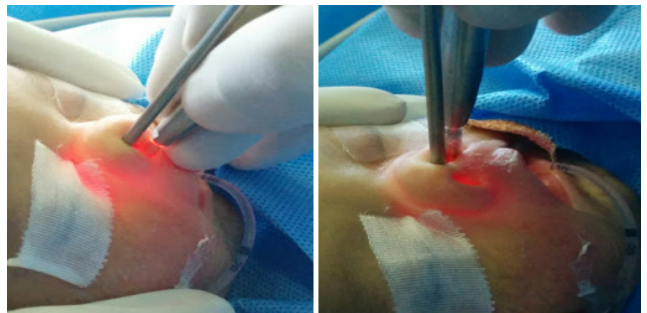
**Fig. 3:** Step 3: Nasal Endoscopy performed with 2.7mm karl storz endoscope. Bilateral CA was confirmed.

**2. Discussion**

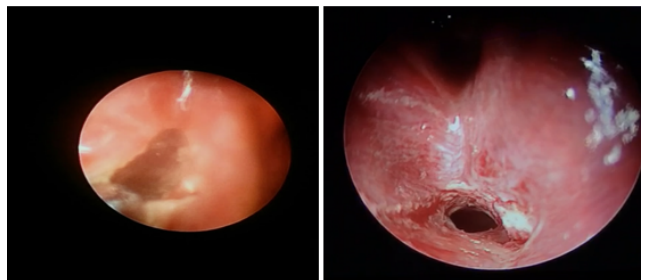
1. Four patients were male and two were female. Only 1/6 patient needed revision surgery for restenosis. Mean Procedure time = 90 min (range = 60-120 min) Mean Hospital stay = 4.3days (range = 3 to 9 days) No intra- and/or early postoperative complications such as epistaxis, infection noticed.
2. Erosion of the nares or intranasal synechiae occurred. All patients underwent postoperative follow-up with



**Fig. 4:** Step 4: 2mm diamond drill with contra-angle hand piece used. Catheter sleeve placed over Drill bit to prevent alar thermal injuries.



**Fig. 5:** Step 5 : Both microdrill and endoscope used via Transnasal route.



**Fig. 6:** Step 6: Inferomedial portion of atretic plate drilled out enough to let 4mm karl storz endoscope to pass through.

clinical evaluation. One patient developed naso palatine fistula due to drilling choanal part as this patient was having high arched palate. No significant regurgitation noticed through the fistula.

**3. Conclusion**

Repair without stenting avoids the potential for stent-related complications, such as discomfort, localized infection and ulceration, circumferential scar or granulation tissue formation. A combination of close post-operative follow-

**Table 1:**

Patient Name	Age	Sex	Investigation done	Other comorbidities	Hospitalisation	Follow up
Baby of A	6 Days	M	Endoscopy	None	4 Days	No Restenosis
Baby of R	6 Days	M	CT Scan	None	3 Days	No Restenosis
Baby Of Z	18 Days	F	CT Scan	Charge Syndrome	9 Days	Partial Stenosis
Baby of N	7 Days	F	CT Scan	None	3 Days	No Restenosis
Baby of Ar	4 Days	M	CT Scan	High Arched Palate	3 Days	No Restenosis, Naso palatine fistula developed due to high arched palate
Baby of S	5 Days	M	CT Scan		4 Days	No Restenosis

up, revision endoscopy to remove nasal crusting 1 week after the primary repair, and frequent nasal saline irrigation was the key to successful management of CA without stenting. However, due to the number of patients included, these findings cannot be generalized and a larger sample is necessary to obtain statistically significant conclusions.

### 3.1. Clinical significance

We suggest this Trans-nasal Endoscopic Surgery because it follows the basic requirements of a minimally-invasive corrective approach: the creation of patent posterior nasal choana sufficient for nasal breathing, minimization of endonasal scar tissue formation, absence of secretion accumulation, and prevention of abnormal craniofacial growth in children who have not reached their full growth yet.

### 4. Source of Funding

None.

### 5. Conflict of Interest

None.

### References

1. Sinha V, More Y. Choanal atresia: surgery by puncture, dilatation and stenting. *J Rhinol.* 2006;13(2):124–7.
2. Gleeson M, George G, Burton MJ, Clarke R, John H, Nicholas S, et al. Scott Brown's otolaryngology head and neck surgery. *Ann R Coll Surg Engl.* 2008;93(7):559. doi:10.1308/147870811X598605b.
3. Panda NK, Simhadri S, Ghosh S. Bilateral choanal atresia in an adult: is it compatible with life? *J Laryngology Otol.* 2004;118(3):244–5. doi:10.1258/002221504322928099.
4. Dobrowski JM, Grundfast KM, Rosenbaum KN, Zajtchuk JT. Otorhinolaryngic Manifestations of CHARGE Association. *Otolaryngol Head Neck Surg.* 1985;93(6):798–803. doi:10.1177/019459988509300619.
5. Freng A. Growth in Width of the Dental Arches After Partial Extirpation of the Mid-Palatal Suture in Man. *Scand J Plast Reconstr Surg.* 1978;12(3):267–72. doi:10.3109/02844317809013003.
6. Friedman NR, Mitchell RB, Bailey CM, Albert DM, Leighton SEJ. Management and outcome of choanal atresia correction. *Int J Pediatr Otorhinolaryngol.* 2000;52(1):45–51. doi:10.1016/s0165-5876(99)00298-0.

### Author biography

**Deepa Shivnani**, Assistant Consultant

**E V Raman**, Consultant

**Dnyansh Amle**, Assistant Professor

**Cite this article:** Shivnani D, Raman EV, Amle D. Trans-nasal endoscopic repair without stenting in bilateral congenital bony choanal atresia: Our technique. *IP J Paediatr Nurs Sci* 2021;4(2):70-72.