



Original Research Article

Deciphering the diagnostic dilemma of abdominopelvic tuberculosis and advanced ovarian cancer

Anitha Gandhi^{1,*}, Sundaram Shanmugasundaram¹, Deepa Shunmugam¹¹Dept. of Surgical Oncology, Tirunelveli Medical College Hospital, Tirunelveli, Tamil Nadu, India

ARTICLE INFO

Article history:

Received 08-09-2020

Accepted 15-02-2021

Available online 25-08-2021

Keywords:

peritoneal tuberculosis

ascites

CA 125

abdominopelvic tuberculosis

ABSTRACT

Background: Abdominopelvic tuberculosis often poses a diagnostic challenge due to its bizarre clinical features and inconclusive imaging features. Most such patients were categorized under advanced ovarian cancer and undergo radical cytoreductive surgery with its associated morbidity, which would otherwise resolve spontaneously with medical management.

Materials and Methods: This is a retrospective study of ten patients referred to the Department of Surgical Oncology between November 2015 to October 2018 in a tertiary care centre at south Tamil Nadu, India as advanced ovarian cancer and later diagnosed to have tuberculosis.

Results: In 10 patients, the mean age was 34 years; mean CA125 was 496.6 IU/ml. abdominal pain and distension, loss of weight were seen in 70% of cases, respectively. Only one patient had a prior history of tuberculosis. The imaging findings were complex adnexal mass in 9 patients (90%), ascites in 6 patients (60%) and omental stranding in 6 patients (60%). Abdominal paracentesis was done in 6 patients (60%) and all had lymphocyte rich effusion. The diagnosis is established by laparotomy and biopsy in seven patients (70%), diagnostic laparoscopy in two patients (20%) and image-guided trucut biopsy in one patient (10%) with histopathology revealing caseating granulomas.

Conclusion: With our patients' experience, a high index of suspicion is always needed whenever we encounter young women presenting with ascites, adnexal mass and elevated serum CA125 even when the routine investigations for tuberculosis reveal negative findings. The biopsy is the gold standard for establishing the diagnosis and to commence therapy.

This is an Open Access (OA) journal, and articles are distributed under the terms of the [Creative Commons Attribution-NonCommercial-ShareAlike 4.0 License](https://creativecommons.org/licenses/by-nc-sa/4.0/), which allows others to remix, tweak, and build upon the work non-commercially, as long as appropriate credit is given and the new creations are licensed under the identical terms.

For reprints contact: reprint@ipinnovative.com

1. Introduction

Tuberculosis (TB) is a major public health issue worldwide. In 2017, 10 million people had tuberculosis and two-thirds of the cases were from eight countries, among which India ranks first (27%). Abdominal tuberculosis involving peritoneum, Gastrointestinal tract, Genitourinary tract, lymph nodes and viscera accounts for 12% of extrapulmonary tuberculosis.¹ Abdominopelvic tuberculosis often presents with non-specific features, leading to a delay in diagnosis and therapy commencement.

It is essential to differentiate between the two entities as the management and prognosis are diverse with increased morbidity and mortality and reduced 5-year survival in advanced ovarian cancer at one end and good outcomes with medical therapy alone at the other end in patients with abdominopelvic tuberculosis.

Though immunocompromised status is a common risk factor for abdominopelvic tuberculosis, 12% of patients do not have any risk factors, thus increasing the diagnostic dilemma. The clinical symptoms and signs of abdominopelvic tuberculosis include pain in the abdomen, abdominal fullness, loss of appetite and weight, imaging revealing adnexal masses with or without peritoneal

* Corresponding author.

E-mail address: chenduronco2014@gmail.com (A. Gandhi).

nodules, and ascites omental nodules, and elevated serum CA125 levels^{2,3} often lead to an alarming diagnosis of advanced ovarian cancer.

Only 10-15% of ovarian cancers occur in premenopausal women with a peak incidence of ovarian cancers occurring between 65-75 years. Whereas abdominopelvic tuberculosis is more common in women of 20-40 years of age, as depicted in many studies in the literature, our study is also similar.⁴ Early diagnosis is mandatory as a study by Chow et al.⁵ reported a mortality rate of 53% due to delay in obtaining mycobacterial culture reports. Our study aims to highlight the importance of diagnosing abdominopelvic tuberculosis and to differentiate it from advanced ovarian cancer to avoid patients undergoing radical surgery with increased morbidity

2. Materials and Methods

This is a case series of ten patients analyzed retrospectively at the Department of Surgical Oncology, Regional Cancer Centre, Tirunelveli Medical College, Tirunelveli, Tamil Nadu, India. The study sample included all patients who presented with an adnexal mass, ascites and elevated serum CA125 and diagnosed as advanced cancer ovary elsewhere between November 2016 to October 2018. Ethical clearance was obtained from the Institutional Review Board. After obtaining consent from the patients included in the study, the patients' demographic details, clinical presentations, laboratory parameters including ascitic fluid analysis and serum CA125 levels, imaging findings, diagnostic procedure, and pathology reports were analyzed. The diagnosis was established by histopathological examination of the biopsy specimen. All patients completed antituberculous therapy and are on followup. Follow up included clinical examination and imaging if symptomatic.

3. Results

The patients' age range was 27 to 45 years (mean 34 years). All patients in our study are parous women. None of them was immunocompromised. One patient had a previous history of tuberculosis. All patients had elevated serum CA125 except one patient ranging from 30.1 to 1101 IU/ml (mean 496.6 IU/ml) [Normal value being less than 35 IU/ml].

The clinical symptoms and signs with which patients presented to us include abdominal distension due to ascites in 7 patients (70%), abdominal pain in 7 patients (70%), loss of weight in 7 patients (70%), loss of appetite in 5 patients (50%), mass abdomen in 4 patients (40%), fever in 1 patient (10%), vomiting in 1 patient (10%) and umbilical sinus with an ulcer in 1 patient (10%). (Figure 1)

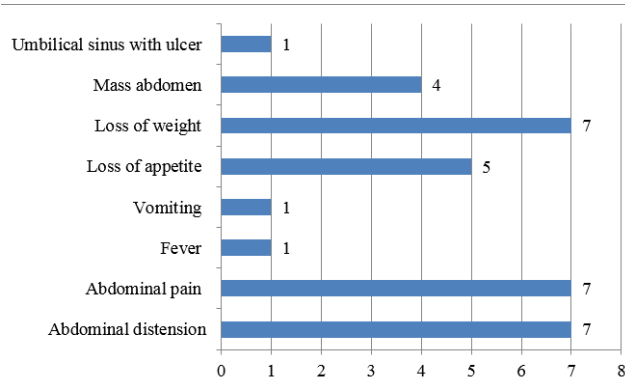


Fig. 1: Clinical symptoms and signs

The contrast-enhanced CT scan findings were complex adnexal mass in 9 patients (90%), ascites in 6 patients (60%), omental stranding in 6 patients (60%), peritoneal nodules in 4 patients (40%), loculated ascites in 1 patient (10%), mass in the rectovaginal plane in 1 patient (10%). Abdominal paracentesis was done in 6 patients (60%) and all had lymphocyte rich effusion. (Figure 2)

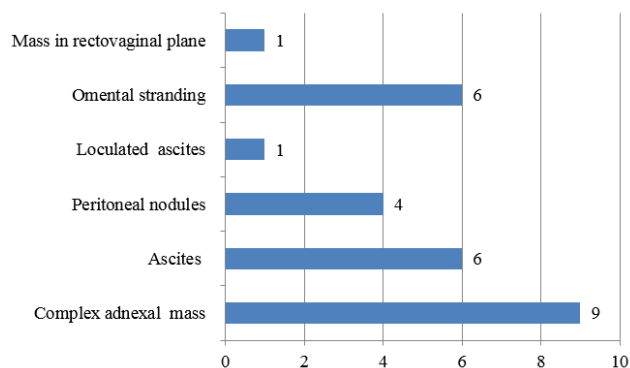


Fig. 2: CT scan findings

Chest X-ray was normal in 90% of patients. One patient had fibrotic change involving the right lung. Contrast-enhanced CT chest of the same patient revealed bronchiectasis changes in the right middle lobe and left upper lobe and fibrotic changes involving the right lung. Her sputum was negative for AFB. None of our patients had contact history.

Six patients underwent laparotomy and biopsy since it was not possible to clinch the diagnosis with the investigations. Repeated ascitic fluid cytology and ultrasound-guided fine-needle aspiration cytology were inconclusive and laparoscopy was deferred because of dense adhesions. The laparotomy findings were diffuse peritoneal thickening, dense adhesions of omentum and small intestines to the parietal wall, tubercles involving parietal and visceral peritoneum, nodules in the mesentery

of the small intestine, abdominal cocoon appearance, bilateral hydrosalpinx, loculated ascites, enlarged ovaries studded with tubercles, ovarian mass, omental caking

One patient underwent complete staging laparotomy and primary cytoreduction as she had complex adnexal mass with normal serum CA 125; two patients underwent diagnostic laparoscopy of which one was converted to mini-laparotomy and biopsy, due to dense adhesions where even entry via Palmer's point was not possible. One patient underwent image-guided trucut biopsy from mass in the rectovaginal plane. All patients had histological evidence of granulomatous inflammation or caseating granulomas in some patients and were started on ATT as per the guidelines. All had symptomatic improvement and are disease-free presently.

4. Discussion

Despite advances in the diagnostic and therapeutic armamentarium, tuberculosis is still on the rise in developing countries due to the increased incidence of HIV and the lack of appropriate implementation of health resources. The common predisposing factors to abdominopelvic tuberculosis include diabetes, HIV, cirrhosis, peritoneal dialysis, underlying malignancy, use of systemic steroids.^{5,6} About 12% of cases have no risk factors. The most common route of spread is by reactivation of latent tuberculous foci in peritoneum reached by hematogenous spread from the pulmonary source. Other routes include transmural spread from the infected small intestine or retrograde spread from tuberculous salpingitis. There is also a possibility of transmission by sexual intercourse with male partners infected with tuberculosis.

Peritoneal tuberculosis occurs in three forms: wet type with ascites, encysted type with localized abdominal swelling, and fibrotic type with abdominal masses composed of mesenteric and omental thickening. Diagnosis is often difficult due to the lack of effective diagnostic tests and usually, abdominopelvic tuberculosis is a diagnosis of exclusion. Patients presenting with complex adnexal mass and limited peritoneal disease confined to pelvis diagnosed as advanced ovarian cancer have to undergo staging laparotomy and cytoreductive surgery associated with some morbidity. It is better avoided when a preoperative clinching diagnosis is made

The present study is an addition to the existing literature on the experience of misdiagnosis of abdominopelvic tuberculosis as advanced ovarian cancers. Only 10% -15% of ovarian cancer occurs in premenopausal women, whereas abdominopelvic tuberculosis is common in women between 20 and 40. Most of the patients in our study were between 20-40 years and none of the patients was nulliparous, which is often a risk factor for ovarian cancer. Although the prior history of tuberculosis or tuberculosis history for a family member helps pinpoint the diagnosis, only < 30% will have

a positive history.⁵ In our study, only one patient had a prior history of tuberculosis.

The clinical features include ascites (93%) and abdominal pain (73%), fever (58%). In our patients also, 70% had ascites and 70% had abdominal pain as illustrated in other studies. Because of insidious onset and non-specific clinical features, it requires a high index of suspicion. Moreover, Laboratory investigations are also not helpful to clinch the diagnosis of abdominopelvic tuberculosis.

Patients who presented with ascites should have the ascitic fluid analysis for cell count, AFB staining & mycobacterial cultures. All 7 patients had exudative effusion. There was lymphocytic rich effusion in 6 out of 10 patients and none of them stained positive for 'AFB in accord with data from Sanai et al. in their systematic review.⁷ Moreover, the AFB smear's sensitivity is <2% and mycobacterial culture is <20% in ascitic fluid.⁸⁻¹⁰ The utility of ascitic fluid PCR to diagnose peritoneal tuberculosis has not been well studied. Out of 7 patients who had ascites, 5 patients with low serum ascites albumin gradient and 3 patients had elevated adenosine deaminase levels of 35, 39, and 40 IU/L. Many authors have illustrated the usefulness of serum ascites albumin gradient of <1.1g/d revealing high sensitivity but with low specificity because of underlying liver or renal disease. Similarly, though adenosine deaminase levels in the ascitic fluid have a sensitivity and specificity of >90% using cut off values from 36-40 IU/L in the diagnosis of abdominopelvic tuberculosis, this further warrants confirmation.¹¹

Elevated serum CA 125 is non-specific in differentiating between benign and malignant conditions especially in premenopausal women since elevated levels are seen in many benign conditions, including endometriosis and pelvic inflammatory disease, fibroid uterus and diseases involving peritoneum like tuberculosis. Serum CA 125 values of even up to 1000 IU/ml can be detected in these benign conditions, especially in endometriosis and abdominopelvic tuberculosis. One of the patients in our study had serum CA-125 value of 1101 IU/ml.¹²

Although CT abdomen and pelvis provide information like mesenteric stranding, omental and peritoneal nodules, loculated ascites, hydrosalpinx, mesenteric lymphadenopathy, they are not pathognomonic. Rather they are useful for directing the biopsy rather than confirming the diagnosis.

To establish the diagnosis in patients with negative ascitic fluid analysis should undergo biopsy by either invasive or non-invasive technique. It is always preferable to do image-guided core needle biopsy whenever possible as it avoids unnecessary surgery and related morbidity in such patients.

Laparoscopy and biopsy are useful for establishing the diagnosis in abdominopelvic tuberculosis by visualization and biopsy for histopathological confirmation.^{10,13-18}

Presently, laparoscopy is becoming the choice method for differentiating tuberculosis from advanced ovarian cancer. But laparoscopy maybe sometimes difficult due to dense adhesions of the small intestine and omentum with parietal peritoneum. In such instances, mini-laparotomy has to be done. The preferable biopsy sites include enlarged mesenteric nodes, nodules in parietal or visceral peritoneum and omental nodules. Moreover, port site TB's risk is also a concern, though only case reports exist in the literature favouring port site TB.

Histopathological examination revealed caseating granulomas in all of our patients. The diagnostic criteria for abdominal tuberculosis as suggested by Paustian include histology showing tubercles with caseating necrosis, suggestive operative findings, consistent histology from mesenteric lymph nodes, animal inoculation, or culture growth of Mycobacterium tuberculosis, or histology showing acid-fast bacilli in the lesion.¹⁹ But the applicability of these criteria is difficult for all cases. Our study patients were started antituberculous therapy based on operative findings and histopathology evidence of granulomas. All patients completed the antituberculous regimen as per the guidelines and are disease-free presently, as evidenced by negative imaging and clinical improvement.

5. Conclusion

It is mandatory to have a high index of suspicion in young females presenting with ascites, adnexal mass and elevated serum CA 125. It is better to establish the diagnosis by non-invasive methods like core needle biopsy under image guidance whenever possible. Early diagnosis and commencement of therapy will avoid unnecessary morbidities associated with misdiagnosis.

6. Conflict of Interest

The authors declare that there are no conflicts of interest in this paper.

7. Source of Funding

None.

References

1. Wu CH, Changchien CC, Tseng CW, Chang HY, Ou YC, Lin H, et al. Disseminated peritoneal tuberculosis simulating advanced ovarian cancer: a retrospective study of 17 cases. *Taiwan J Obstet Gynecol.* 2011;50(3):292–6. doi:10.1016/j.tjog.2011.07.006.
2. Wu DC, Averbukh LD, Wu GY. Diagnostic and Therapeutic Strategies for Peritoneal Tuberculosis: A Review. *J Clin Transl Hepatol.* 2019;7(2):140–8. doi:10.14218/JCTH.2018.00062.
3. Elmore RG, Li AJ. Peritoneal tuberculosis mimicking advanced-stage epithelial ovarian cancer. *Obstet Gynecol.* 2007;110(6):1417–9. doi:10.1097/01.AOG.0000295653.32975.4a.
4. Djuwantono T, Permadi W, Septiani L, Faried A, Halim D, Parwati I, et al. Female genital tuberculosis and infertility: serial cases report in Bandung, Indonesia and literature review. *BMC Res Notes.* 2017;10(1):683. doi:10.1186/s13104-017-3057-z.

5. Chow K, Chow V, Hung L, Wong S, Szeto C. Tuberculous Peritonitis-Associated Mortality Is High among Patients Waiting for the Results of Mycobacterial Cultures of Ascitic Fluid Samples. *Clin Infect Dis.* 2002;35(4):409–13.
6. Mehta JB, Dutt A, Harvill L, Mathews KM. Epidemiology of extrapulmonary tuberculosis. A comparative analysis with pre-AIDS era. *Chest.* 1991;99(5):1134–8. doi:10.1378/chest.99.5.1134.
7. Sanai FM, Bzeizi KI. Systematic review: tuberculous peritonitis presenting features diagnostic strategies and treatment. *Aliment Pharmacol Ther.* 2005;22(2):685–700. doi:10.1111/j.1365-2036.2005.02645.x.
8. Debi U, Ravisankar V, Prasad KK. Abdominal tuberculosis of the gastrointestinal tract: revisited. *World J Gastroenterol.* 2014;20(40):14831–40. doi:10.3748/wjg.v20.i40.14831.
9. Marshall JB. Tuberculosis of the gastrointestinal tract and peritoneum. *Am J Gastroenterol.* 1993;88(7):989–99.
10. Hillebrand DJ, Runyon BA, Yasmineh WG, Rynders GP. Ascitic fluid adenosine deaminase insensitivity in detecting tuberculous peritonitis in the United States. *Hepatology.* 1996;24(6):1408–12. doi:10.1002/hep.510240617.
11. Riquelme A, Calvo M, Salech F, Valderrama S, Pattillo A, Arellano M, et al. Value of adenosine deaminase (ADA) in ascitic fluid for the diagnosis of tuberculous peritonitis: a meta-analysis. *J Clin Gastroenterol.* 2006;40(8):705–10. doi:10.1097/00004836-200609000-00009.
12. Bast RC, Badgwell D, Lu Z, Marquez R, Rosen D, Liu J, et al. New tumor markers: CA125 and beyond. *Int J Gynecol Cancer.* 2005;15(3):274–81.
13. Chow KM, Chow VC, Hung LC. Tuberculous peritonitis-associated mortality is high among patients waiting for the results of mycobacterial cultures of ascitic fluid samples. *Clin Infect Dis.* 2002;35(4):409–13. doi:10.1086/341898.
14. Manohar A, Simjee AE, Haffeejee AA, Pettengell KE. Symptoms and investigative findings in 145 patients with tuberculous peritonitis diagnosed by peritoneoscopy and biopsy over a five year period. *Gut.* 1990;31(10):1130–2. doi:10.1136/gut.31.10.1130.
15. Bhargava DK, Shrinivas, Chopra P. Peritoneal tuberculosis: laparoscopic patterns and its diagnostic accuracy. *Am J Gastroenterol.* 1992;87(1):109–12.
16. Tandon RK, Sarin SK, Bose SL. A clinico-radiological reappraisal of intestinal tuberculosis—changing profile? *Gastroenterol Jpn.* 1986;21(1):17–22. doi:10.1007/BF02775935.
17. Singh MM, Bhargava AN, Jain KP. Tuberculous peritonitis. An evaluation of pathogenetic mechanisms, diagnostic procedures and therapeutic measures. *N Engl J Med.* 1969;281(20):1091–4. doi:10.1056/NEJM19691132812003.
18. Ribera E, Vásquez JMM, Ocaña I, Ruiz I, Jiménez JG, Encabo G, et al. Diagnostic value of ascites gamma interferon levels in tuberculous peritonitis. Comparison with adenosine deaminase activity. *Tubercle.* 1991;72(3):193–7. doi:10.1016/0041-3879(91)90007-f.
19. Harshal S, Mandavdhare H, Singh. Vishal Sharma Recent advances in the diagnosis and management of abdominal tuberculosis. *EMJ Gastroenterol.* 2017;6(1):52–60.

Author biography

Anitha Gandhi, Assistant Professor

Sundaram Shanmugasundaram, Professor and Head

Deepa Shunmugam, Assistant Professor

Cite this article: Gandhi A, Shanmugasundaram S, Shunmugam D. Deciphering the diagnostic dilemma of abdominopelvic tuberculosis and advanced ovarian cancer. *Panacea J Med Sci* 2021;11(2):305-308.