



## Original Research Article

## Study of soft tissue cover in compound lower limb trauma

M. Chandralekha<sup>1</sup>, Puli Ashwin Kishore<sup>1,\*</sup><sup>1</sup>Dept. of Plastic Surgery, Osmania Medical College/ Osmania General Hospital, Hyderabad, Telangana, India

## ARTICLE INFO

## Article history:

Received 19-03-2021

Accepted 24-05-2021

Available online 30-04-2022

## Keywords:

Open fracture

Flap cover

Delayed flap cover

## ABSTRACT

**Introduction:** Early vascularized soft tissue closure has long been recognized to be essential in achieving eventual infection free union. The question of whether muscle or fasciocutaneous tissue is superior in terms of promoting fracture healing remains unresolved.

**Aims:** To study options of different flaps in compound lower limb trauma and to know the pattern of providing flap cover in our setup.

**Materials and Methods:** This was prospective observational study conducted in all the cases admitted under orthopaedics department who are hemodynamically stabilised, later referred to our department of plastic surgery for the flap cover. Isolated compound lower limb injuries with or without fractures were included in study.

**Results:** Among 45 cases one patient (2.2%) had defect in the thigh, two patients had defect around knee (6.6%), nine cases had defect in upper third leg (20%), thirteen patients had defect in middle third leg (28.8%), seventeen patients have defect in lower third leg (37.7%) and three patients had in the foot (6.6%). Cross leg flap were used in 11 cases (24.4%) Gastrocnemius myo-cutaneous flap were used in 9 cases (20%). Fascio-cutaneous flaps superiorly based were used in three cases (6.6%) and Inferiorly based Fasciocutaneous flaps were used in 6 cases (13.3%), Reverse sural artery flap were used in six cases (13.3%) and Lateral premalleolar flap were used in 8 cases (17.7) and Advancement flap done in one case over defect of the thigh (2.2%). In a case with defect over thigh (2.2%). Complications like total flap loss was noted in one case (2.2%) marginal necrosis noted in five cases (11.1%) and pin track infection in three cases (6.6%).

**Conclusion:** In Grade IIIB fractures external fixator was the choice of skeletal stabilisation. Delayed flap cover gave good results but it increases duration of hospital stay.

This is an Open Access (OA) journal, and articles are distributed under the terms of the [Creative Commons Attribution-NonCommercial-ShareAlike 4.0 License](https://creativecommons.org/licenses/by-nc-sa/4.0/), which allows others to remix, tweak, and build upon the work non-commercially, as long as appropriate credit is given and the new creations are licensed under the identical terms.

For reprints contact: [reprint@ipinnovative.com](mailto:reprint@ipinnovative.com)

## 1. Introduction

An open fracture with extensive soft tissue defect still remains one of the most delicate and challenging problems in trauma surgery. An open fracture is defined as one in which a break in the skin and underlying soft tissue leads directly into or communicates with the fracture and its hematoma. Severe bone and soft tissue injuries produced by high velocity trauma have become one of the common

causes of morbidity and mortality all over the world. When the wound occurs on the fractured limb, the fracture must be considered open until proved otherwise (Technically compound fracture).<sup>1</sup>

Open injuries expose many tissues like bone, tendon, nerves and vessels which all tend to die when left exposed. Hence it is important to give wound cover as early as possible. Here distinction must be made between wound cover and the wound closure. While early coverage is advantageous, imprudent closure can result in disasters. Attempts at tight closure in swollen limb or in a limb with

\* Corresponding author.

E-mail address: [drpuliashwinkishaore@gmail.com](mailto:drpuliashwinkishaore@gmail.com) (P. A. Kishore).

potential for swelling in the 48 hours of post operative period can lead to many complications like skin necrosis, compartmental syndromes and increase in infection rate. Primary flap cover may be given if initial debridement is adequate. It would be advisable here that the need for plastic surgeon to get involved on day 1 itself is important so that early cover can be provided.

The goal in the management of leg trauma is to preserve the limb that is more functional than an amputated limb with prosthesis. Achieving this goal requires the current and timely management of both bone and soft tissue defects. The plastic surgeon has an array of soft tissue reconstructive techniques for use in the leg injuries. These range from simple skin grafting to complex micro-vascular techniques. The soft tissue is chosen that will maximize the functional and cosmetic results.

Compound fractures involve injuries to bone and soft tissues. Here the healing of each component is dependent on the effective treatment of the other. Bone stability is the foundation for reconstruction of soft tissue, whereas soft tissue cover is foundation for bone healing. One cannot wait for the other and if the golden opportunity of primary reconstruction of both is lost and they may result in complications and end in disasters. Here the sequence of surgery and proper planning is essential for the reconstruction options.

External fixator is a useful and versatile device and has gained popularity especially over the last few years by virtue of its advantages in the open fractures of the leg. It has found clinical application in the management of the difficult diaphyseal fractures of long bones, particularly when there is an associated severe soft tissue injury. A unique feature inherent to the device is the ability to stabilize the fracture both at the time of application of the frame and during the course of the healing. External fixator provides stable fixation of the fracture while avoiding large metal implants at the site which would impede the healing and by stabilization of the limb, prevents secondary vascular injury in the distal parts. The risk of infection is negligible with proper care. Complications of skin and soft tissue injuries present fewer problems. Joint motion in the fractured limb is almost unimpeded and the management of patients with multiple injuries is easier.<sup>2</sup>

Amongst the flap covers, fascio-cutaneous flaps are better off and when chosen correctly provide solution to the challenging soft tissue problem in leg injuries, without need of complicated equipment. Usually for thigh injuries grafting is sufficient. For upper upper  $1/3^{rd}$  of leg with open fractures, muscle flaps are the choice. For the middle  $1/3^{rd}$  of leg with open fractures, fascio-cutaneous flaps are options and for the open fractures in the lower  $1/3^{rd}$  of leg, the options are cross-leg flaps, distal Sural neuro-cutaneous flaps and micro-vascular flaps. Most of the defects of foot too, are better addressed by the flaps from the leg, or by free

flaps rather than the flaps from the leg per-se, though flaps like Flexor Hallucis Brevis muscle flap, Abductor Digiti Minimi muscle flap and medial plantar flap are described and whose anatomy has been discussed in the following pages. The main aim of treatment of open fractures is to restore the anatomy to near normal and its function as early and as fully as possible.

## 2. Materials and Methods

This was prospective observational study conducted in Gandhi medical college/ Gandhi hospital, Secunderabad from September 2013 to March 2016. All the cases are initially admitted under orthopaedics department who are hemodynamically stabilised then later referred to department of plastic surgery for the flap cover.

### 2.1. Inclusion criteria

Isolated compound lower limb injuries with or without fractures.

### 2.2. Exclusion criteria

1. Patients with poly-trauma
2. Patients of <10 years of age and >60 years of age
3. Patients with significant medical disorders.

Detailed systemic and local examination of the wounds were done. Radiological examination of the limb was carried out. Along with classification of fractures, other details such as nature of the fracture and type of the wound were noted. Patients were put on broad spectrum antibiotics initially and later according to culture sensitivity report. Appropriate flap cover was planned accordingly with a life boat.

Once the patient was found fit for surgery after induction of anaesthesia, wounds were cleaned once again and thorough debridement was carried out and flap cover was given.

Post-operatively wounds and pin tracks were dressed regularly to prevent infection. Antibiotics were administered in all cases and changes were made according to the culture and sensitivity reports. High protein diet was given in all cases to improve general condition and nourishment. Early active movements of the joints were encouraged and crutch ambulation was started when the general condition of the patient improved.

All the cases were regularly followed up and status of soft tissue cover was noted.

## 3. Results

In our study 45 patients were included. Males predominated the study.

Among 45 cases one patient (2.2%) had defect in the thigh, two patients had defect around knee (6.6%), nine cases had defect in upper third leg (20%), thirteen patients

**Table 1:** Demographic distribution in present study

Sex	Number of Patients (N=45)	Percentages
Males	39	86.7%
Females	6	13.3%
<b>Age</b>		
12-20	7	15.5%
21-30	14	31.2%
31-40	8	17.8%
41-50	7	15.5%
50-60	9	20%
<b>Site of defect</b>		
Thigh	1	2.2%
Around knee	2	4.4%
Upper third leg	9	20%
Middle third leg	13	28.8%
Lower third leg	17	37.7%
Foot	3	6.6%

had defect in middle third leg (28.8%), seventeen patients have defect in lower third leg (37.7%) and three patients had in the foot (6.6%)

**Table 2:** Type of flap cover in different areas

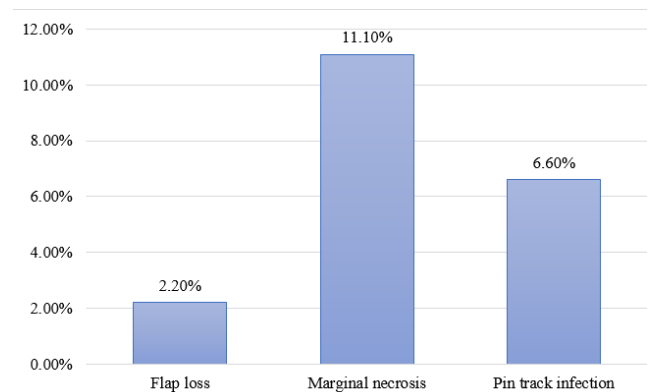
Flap Cover	Number of Patients (N=45)
Cross leg flap	11 (24.4%)
Gastrocnemius myocutaneous flap	9 (20%)
Superiorly based fasciocutaneous flap	3 (6.6%)
Inferiorly based fasciocutaneous flap	6 (13.3%)
Reverse sural artery flap	6 (13.3%)
Lateral pre malleolar flap	9 (20%)
Advancement flap	1 (2.2%)
<b>Defect Around Knee</b>	
Gastrocnemius myocutaneous flap	2 (100%)
<b>Upper Third Defects</b>	
Gastrocnemius myocutaneous flap	6 (66.7%)
Fasciocutaneous flap	3 (33.3%)
<b>Middle Third Leg Defects</b>	
Cross leg flap	7 (53.8%)
Reverse sural artery flap	1 (7.7%)
Gastrocnemius myocutaneous flap	1 (7.7%)
Fasciocutaneous flap	4 (30.8%)
<b>Lower Third Leg Defects-Flap Cover</b>	
Cross leg	3 (17.6%)
Reverse sural artery flap	4 (23.5%)
Lateral Premalleolar flap	8 (47%)
Fasciocutaneous flap	2 (11.8%)
<b>Reverse sural artery flap</b>	
Cross leg	1 (33.3%)
Reverse sural artery flap	1 (33.3%)
Lateral Premalleolar flap	1 (33.3%)

Cross leg flap were used in 11 cases (24.4%) Gastrocnemius myo-cutaneous flap were used in 9 cases

(20%). Fascio-cutaneous flaps superiorly based were used in three cases (6.6%) and Inferiorly based Fasciocutaneous flaps were used in 6 cases (13.3%), Reverse sural artery flap were used in six cases (13.3%) and Lateral premalleolar flap were used in 8 cases (17.7%) and Advancement flap done in one case over defect of the thigh (2.2%). In a case with defect over thigh (2.2%) Advancement flap cover was given.

In two cases with defect around the knee total of two cases (4.4%) Gastrocnemius myocutaneous flap cover were given.

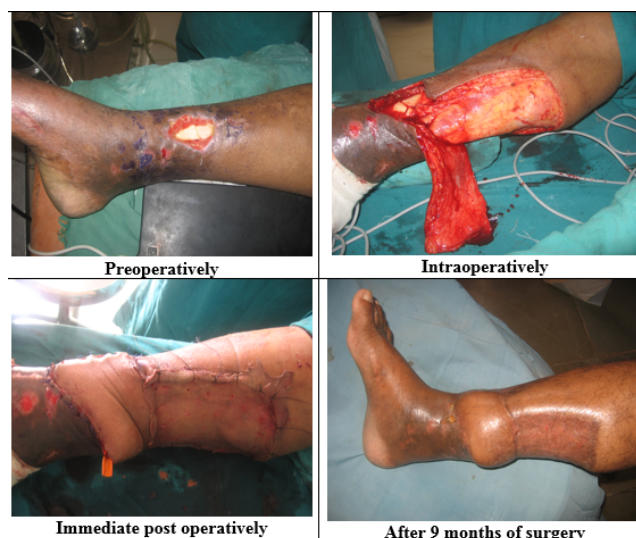For upper third leg defects 9 cases out of 45, Gastrocnemius myocutaneous flap were used in six cases (66.7%) and Fasciocutaneous flap cover given in three cases 33.3%. For middle third defects 13 out of 45, Cross leg flap were used in seven cases (53.8%) Reverse sural artery flap (7.7%) was used in one patient, Gastrocnemius muscle flap were used in one case (7.7%), and Fasciocutaneous flap were used in four cases (30.8%) For lower third defects 17 out of 45 cases, Cross leg flap were used in three cases (17.6%) Reverse sural artery flap were used in 4 cases (23.5%), Lateral premalleolar flap were used in eight cases (47%) Fasciocutaneous flap were used in two cases (11.8%) For foot defects 3 out of 45 cases, Reverse sural artery flap was used in one case (33.3%) Cross leg flap was used in one case (33.3%) and Lateral pre malleolar flap was used in one case (33.3%).

**Fig. 1:** Complications in present study

Complications like total flap loss was noted in one case (2.2%) marginal necrosis noted in five cases (11.1%) and pin track infection in three cases (6.6%).

#### 4. Discussion

The study was done on 45 cases from September 2013 to March 2016. All the cases were treated with thorough debridement and early skeletal stabilisation. Wound coverage was planned and offered based on the needs of the defect. The compound fracture of leg was observed to be more common in young and middle aged males who were active working group. Our aim to provide



**Fig. 2:** Inferior based Fasciocutaneous flap for L3<sup>rd</sup> defect

flap covers in compound fractures was to enable early union of the fractures and to minimise the morbidity and prevent complications like wound infection, osteomyelitis, shortening of limb and in extreme cases to prevent amputation of the limbs.

In our study, the minimum age was 12 years and maximum age was 60 years. Out of 45 cases, only 6 (13.3%) patients were females. The preponderance of the young and middle age group and occurrence in males can be explained by the nature of their activity and exposure to vehicular accidents. One of the most significant factors in the outcome of any limb is the amount of the energy absorbed by the tissues at the time of injury. Grade III B fractures were the most frequently encountered, highlighting the mechanism of direct hit. In our series, most of the cases were lower third defects. They constituted about 37.7%, middle third defects of the leg constituted about 28.8 % of all the cases.

In most of the cases we found fibula was fractured along with tibia. Ideally compound injury of leg should be managed by Orthopedicians and Plastic surgeons together with adequate debridement and fracture stabilisation. Soft tissue cover should be given primarily after skeletal stabilisation, or as early as possible. Though the primary cover was being advocated, we were unable to do so, for reasons of deficiencies of infrastructure, human resources with delayed admissions.

In most cases, external fixator was applied within 24 – 48 hours of hospitalization after thorough debridement. Wound cover was as a delayed procedure for various reasons. Wound cover was given after 3 weeks in all the cases. The reconstructive ladder was kept in mind while giving the wound cover. Among our 45 cases one case (2.2%) with defect over anterior aspect of right thigh of size 3x4 cms was closed primarily after advancing the flaps on either side after

transposing the adjacent muscle on to the exposed bone.

We had two cases (6.6%) around the knee joint, we contemplated Gastrocnemius myocutaneous flap cover for both the cases. We had a flap loss in one case because of exposed knee joint and septic arthritis in the joint, and the other case flap settled well with out any complications.

Out of 45 cases we had nine cases (20%) in upper third leg, we contemplated Gastrocnemius myocutaneous flap in six cases (66.7%) and superiorly based lateral Fasciocutaneous flap in two cases (22.2%) and superiorly based medial Fasciocutaneous flap in one case (11.1%). All the flaps settled well with out any complications. In study conducted by El-Sherbiny M<sup>3</sup> on 30 cases of bone and soft tissue sarcoma around knee joint ,of which 15 cases had defect on proximal tibia, all the cases were given Gastrocnemius myocutaneous flap cover and all the flaps healed with out any complications.

We have 13 cases (28.8%) in the middle third leg, in which we did Cross leg flap in seven cases (53.8%) Gastrocnemius muscle flap and SSG in one case (7.7%), Reverse sural artery flap in one case (7.7%) and Inferiorly based Fasciocutaneous flap in four cases (30.8%). Two cases (15.3%) among middle third defects of had marginal necrosis of 1cm which was addressed with regular dressings and SSG. One was with Cross leg flap and the other was with Reverse sural artery flap. Critical area was not exposed in either of the case.

In lower one third defects of 17 cases (37.7%), we did Cross leg flap in three cases (17.6%), Reverse sural artery flap in four cases (23.4%), Lateral supra-malleolar flap in eight cases (47%) and Fasciocutaneous flap in two cases (11.7%). We had two cases (11.7%) of marginal necrosis of 1 – 2cms which was managed with regular dressings and SSG. Critical area was not exposed in any of the case. One case of Lateral supra-malleolar flap and one case of Cross leg flap had this complication.

We have three cases (6.6%) out of 45 cases in dorsum of foot, and these are covered with Reverse sural artery flap, Cross leg flap and other with Lateral supra-malleolar flap.

Case covered with Reverse sural artery flap showed marginal necrosis of 1cm and none of the case showed any complications. And it was managed with regular dressings and SSG.

Though, in our department we do free flaps occasionally, but in this study all the cases were referred to us after 2 weeks, so we opted only for pedicled flaps and did not contemplated free flaps. Soleus muscle flap which is preferred flap for middle third leg, but it has been not done in our series.

In a study conducted by Asif Zubar bhatti et al<sup>4</sup> on lower limb flaps a comparison between free flaps and local flaps in 2007, 26 cases were given pedicled flaps of which one case had total flap loss (3.8%) and two cases with partial loss (7.6%). In our study of 45 cases, we had five cases

of marginal necrosis (11.1%) which were managed with regular dressings and SSG. One with total flap loss (2.2%) and three cases had pin track infection.

Among 45 cases we did Cross leg flap in 11 cases (24.4%) of which middle third defects were 7, lower third defects were 3, and one was over the foot. Two cases were found to have marginal necrosis (18.2%). In study conducted by Pawan Agarwal and HKT Raza titled Cross leg flap: its role in limb salvage in 2007,<sup>5</sup> total of 18 cases were given Cross leg flap of which 15 settled well two cases had marginal necrosis (11.1%) and one had superficial epidermal necrosis (5.5%).

In study conducted by El-Sherbiny M<sup>3</sup> in 2008 on 30 cases of bone and soft tissue sarcoma around knee joint of which 15 cases had defect on proximal tibia, all the cases were given Gastrocnemius myocutaneous flap cover and all the flaps healed with out any complications. In our series we did 9 (20%) cases of Gastrocnemius flap, we had one total flap loss for defect around knee and in all other cases flap settled well. In our study we did superiorly based Fasciocutaneous flap in three cases of upper third defects (6.6%) and inferiorly based Fasciocutaneous flaps in six cases (13.3%). All the flaps settled well.

In our study we did Reverse sural artery flap in six cases. Of which two cases had marginal necrosis and the four settled well. In the study conducted by Yimin Chai, MD, Bingfang Zeng, MD, et al., titled experience with distally based sural neurocutaneous flap for ankle and foot reconstruction in 2007,<sup>6</sup> included 15 cases of which 13 cases settled well and two cases had marginal necrosis. In study conducted by Sherine S. Ravindran, D. Perera et al titled superficial sural artery a study in 40 cases in 2003<sup>7</sup> shows no complications in 34 cases, marginal necrosis in 5 cases and flap loss in 1 case. In another study by Christof Meyer et al.,<sup>7</sup> titled reconstruction of the lower leg with sural artery flap in 2002, 17 cases were included of which marginal necrosis was noted in two and total flap loss in one case.

**Table 3:** Comparison of Reverse Sural Artery Flap with other studies

Reverse Sural Artery Flap	Yimin Chai et al., <sup>6</sup>	Sherine S. Ravindran et al. <sup>7</sup>	Christof Meyer et al. <sup>8</sup>	Our Study
Total Cases	15	40	17	6
Marginal Necrosis	2 (13.3%)	5 (12.5%)	2 (11.7%)	2 (33.3%)
Flap Loss	-	1 (2.5%)	1 (5.8%)	-

In our study we did Lateral supra malleolar flap in nine cases (20%) of which eight were for lower third leg defects and one for foot defect. One case had marginal necrosis and the rest healed well. In study conducted by Ehab Fouad Zayed et al., titled Lateral supra malleolar flap for distal leg

and foot defects,<sup>9</sup> 25 cases were included and 5 cases were found to have marginal necrosis.

## 5. Conclusions

In our study of 45 cases we found young and middle age males were commonly affected.

Road traffic accidents were found to be common cause of leg trauma. Most of the cases were having fracture of both bones of leg. Skeletal stabilisation, restoration of vascular continuity and provision of stable cover was followed. Lower third leg defects out numbered middle third leg and upper third leg defects. In Grade IIIB fractures external fixator was the choice of skeletal stabilisation. Delayed flap cover gave good results but it increases duration of hospital stay. Gastrocnemius myocutaneous flap was the choice in upper third leg defects.

For larger defects over middle third leg, lower third leg and foot defects Cross leg flap found to be reliable option in our institution. For lower third leg defects, we had two choices, for smaller defects Lateral supra-malleolar flap (largest dimension of defect we have was 8x5 cms) and Reverse sural artery flap was reserved for larger defects. The major advantage of Lateral supra malleolar artery flap over Reverse sural artery flap was we were able to nurse the patient in supine position.

## 6. Conflict of Interest

None.

## 7. Funding of Sources

No financial support was received for the work within this manuscript

## References

- Campbell AS, Willis C, Crenshaw A. Campbell's Operative Orthopaedics, 6th edn. . St. Louis, C. V. Mosby Co; 1980.
- Edwards C, Simons SC, Browner B, Weigel MC. Severe open tibial fractures. Results treating 202 injuries with external fixation. *Clin Orthop Relat Res.* 1988;(230):98–115.
- El-Sherbiny M. Clinical application in limb spraring surgical resection of sarcoma around knee region & popliteal fossa. *J Egypt Natl Canc Inst.* 2008;20(2):196–207.
- Asif, Bhatti. Lower leg flaps-comparison between Free vs. Local flaps. *Internet J Plast Surg.* 2007;3(2):e1–8.
- Agarwal P, Raza HKT. Crossleg flap: its role in limb salvage. *Indian J Orthop.* 2008;42(4):439–43. doi:10.4103/0019-5413.43394.
- Chai Y, Md ZB, Zeng F, Qinglin K, Qingcheng Y. Experience With the Distally Based Sural Neurofasciocutaneous Flap Supplied by the Terminal Perforator of Peroneal Vessels for Ankle and Foot Reconstruction. *Ann Plast Surg.* 2007;59(5):526–31. doi:10.1097/01.sap.0000258969.13723.68.
- Raveendran SS, Perera D, Happuharachchi T, Yoganathan V. Superficial sural artery flap—a study in 40 cases. *Br J Plast Surg.* 2003;57(3):266–9. doi:10.1016/j.bjps.2003.12.005.
- Meyer C, Hartmann B, Horas U, Killian O, Heiss C, Schnettler R, et al. Reconstruction of lower leg with Sural artery flap. *Langenbecks Arch Surg.* 2002;387(7-8):320–5. doi:10.1007/s00423-002-0317-7.

9. Fouad ZE. Lateral Supramalleolar Flap for reconstruction of the distal leg and foot, Clinical experience with 25 cases. *J Plast Reconstr Surg.* 2011;35(2):279–86.

**Puli Ashwin Kishore**, Assistant Professor

### **Author biography**

**M. Chandralekha**, Assistant Professor

**Cite this article:** Chandralekha M, Kishore PA. Study of soft tissue cover in compound lower limb trauma. *Panacea J Med Sci* 2022;12(1):110-115.