



## Original Research Article

## A comparative study of the outcomes of fixation of fractures of distal femur by femoralnailing vs distal femoral locking compression plate

Jhathoth Dhoom Singh<sup>1</sup>, K. Raja Ratnam<sup>2,\*</sup>

<sup>1</sup>Dept. of Orthopaedics, Dr.V.R.K.Women's Medical College and Teaching Hospital & Research Center, Hyderabad, Telangana, India

<sup>2</sup>Dept. of Orthopaedics, Maheshwara Medical College & Hospital, Medak, Telangana, India



## ARTICLE INFO

## Article history:

Received 01-03-2021

Accepted 14-05-2021

Available online 30-04-2022

## Keywords:

Locking compression plates

Dynamic condylar screws

Retrograde supra condylar nailing

## ABSTRACT

**Introduction:** Distal femoral fractures are much less common than hip fractures and account for 7% of all femoral fractures.

**Aims:** To determine the fracture characteristics (AO type, Muller's classification). To study the advantages of fixation with distal femoral locking compression plates and retrograde intramedullary supracondylar nailing.

**Materials and Methods:** The present comparative study was conducted between May 2019 to November 2020 in department of orthopaedics. Sample size of 30 patients presenting with supracondylar fractures of the femur were treated by distal femoral locking compression plates, dynamic condylar screws and retrograde supra condylar nailing.

**Results:** Out of 30 cases those treated by supracondylar nail had an average healing time of 14.8 weeks and those treated by locking compression plate had an average healing time of 15.9. Among the 30 cases of supracondylar fracture fixed by supracondylar nail 14 were scored as good and one was scored as excellent, whereas those fixed by locking compression plate 14 were scored as good and 1 cases was scored as fair. Out of 30 cases of supracondylar fracture fixed none had any intraoperative complications barring one which had break of drill bit intraoperatively and stayed insitu to the bone, there were no instances of surgical wound infections. The intraoperative blood loss was significantly lower when the fractures were fixed by supracondylar nail which averaged to 150ml when compared to the fixations by locking compression plate which averages to 300ml.

**Conclusion:** The supracondylar nail is more ideal when compared to the distal femoral locking compression plate as there is less operation time, less blood loss, more range of movement, less soft tissue stripping & faster radiological union when compared to the distal femoral locking compression plate. Fracture personality & soft tissue quality.

This is an Open Access (OA) journal, and articles are distributed under the terms of the [Creative Commons Attribution-NonCommercial-ShareAlike 4.0 License](https://creativecommons.org/licenses/by-nc-sa/4.0/), which allows others to remix, tweak, and build upon the work non-commercially, as long as appropriate credit is given and the new creations are licensed under the identical terms.

For reprints contact: [reprint@ipinnovative.com](mailto:reprint@ipinnovative.com)

### 1. Introduction

Supracondylar fractures of the femur by definition involve distal 15 cm of the femur including the distal femoral metaphysis (supracondylar) and the articular surface of the distal femur (intercondylar). They have been historically

very difficult to treat. These fractures often are unstable, comminuted and tend to occur in elderly or multiple injured patients. Because of the proximity of these fractures to the knee joint, regaining full knee motion and function may be difficult. The incidences of mal-union, non-union and infection are relatively high. These serious injuries have the potential to produce significant long-term disability.<sup>1,2</sup>

\* Corresponding author.

E-mail address: [sandhyarathnam8185@gmail.com](mailto:sandhyarathnam8185@gmail.com) (K. R. Ratnam).

Distal femoral fractures are much less common than hip fractures and account for 7% of all femoral fractures. If fractures of the hip are excluded, 31% of femoral fractures involve the distal portion. The incidence of distal femur fractures is around 37/100,000 patients per year. In the older population with osteoporotic bone and vulnerable soft-tissue envelope, distal femoral fractures occur predominantly after low-energy trauma, e.g., falls and sprain injuries complicated by a high rate of comorbidity (60% female, older than 60 years). In young patients (60% male, younger than 40 years), high-energy trauma causes complex injury with comminuted and open fractures. Severe comminution often requires fixation of multiple independent fragments with one device to minimize soft-tissue damage. The significant forces applied to this area, even during restricted patient activities, require a strong implant; however, fixation is difficult because of the wide canal, the thin cortex, and the relatively poor bone quality of the distal femur.<sup>3</sup>

They remain a significant challenge to the orthopaedic surgeon. Many factors come into play while planning treatment of these fractures, including fracture type, associated injuries, age, premorbid functional and medical status and soft tissue injury. Prior to the early 1970s most fractures of the distal femur were treated non-surgically. Advancements in internal fixation design and improvements in surgical techniques especially by AO group with studies on internal fixation gave better results, Retrograde intramedullary nailing. The most predictable results are attained with operative fixation with ability to obtain an anatomical reduction of the joint surface, restoring axial alignment and beginning early range of motion presented a clear advantage over closed means of treatment. Muller's classification is probably the most widely accepted classification system<sup>2</sup> and the same has been used in the present series.<sup>4,5</sup>

Controversy still remains regarding the optimum device for distal femur fixation. No one implant is suited for all fractures. The type of fixation device selected depends on patient variables, fracture personality and soft tissue quality. Regardless of the device chosen, the ultimate goal is the same - restoration of articular congruity, stable fixation, limited surgical morbidity and early mobilization and knee motion. The feasibility and the functional outcome of 30 cases of supracondylar fractures of femur, by fixation with locking compression plates, retrograde intramedullary supracondylar nailing and dynamic condylar screw was studied in this series and the results are reported.

## 2. Materials and Methods

The present comparative study was conducted between May 2019 to November 2020 in department of orthopaedics. Sample size of 30 patients presenting with supracondylar fractures of the femur were treated by distal femoral

locking compression plates, dynamic condylar screws and retrograde supra condylar nailing.

### 2.1. Inclusion criteria

Patients presenting with supracondylar fractures of the femur in both male and female patients, both simple and comminuted, patients older than 18 years. All supracondylar fractures of femur treated by locking compression plates and retrograde supracondylar nail.

### 2.2. Exclusion criteria

Compound supracondylar fractures of femur associated with ipsilateral femoral neck fracture, ipsilateral leg fractures and Pathological supracondylar femur fractures, with congenital deformities of femur. Patients managed conservatively for other medical reasons. 8. Supracondylar fractures of femur with neurovascular compromise. Peri prosthetic fractures of supracondylar area

All patients were admitted and a careful history was elicited from the patient or attendants to reveal the mechanism of the injury and the severity of the trauma, site of the incident, circumstances about which the injury occurred, premorbid medical history and preinjury functional status. The patients were then assessed clinically to evaluate their general condition and the vital signs were recorded. The involved extremity was examined for swelling, deformity, abnormal mobility, crepitus, shortening, discoloration, skin integrity, neurological and vascular compromise, and signs or symptoms of compartment syndrome. Medical consultation was sought expeditiously for geriatric patients. General surgeon consultation was sought to evaluate all high-energy accident victims to rule out poly trauma. Patients with severe blood loss were treated by blood transfusions and volume expanders.

Routine investigations done were: hemoglobin percentage, bleeding time, clotting time, random blood sugar, blood urea, serum creatinine, serum electrolytes, HIV and HBs Ag, Blood grouping and cross matching, ECG, Chest X-ray, Urine for macroscopy, sugar, albumin and microscopy. Other investigations like 2D Echo. Radiographic evaluation included anteroposterior and lateral radiographs of the distal femur, including the knee joint and proximal tibia and ipsilateral hip joint. If hemarthrosis was present the knee joint was aspirated and the limb was placed in Bohler Braun splint. The patient was then taken up for surgery after investigations and as soon as the patient was medically fit for surgery. Multiple surgeons performed the surgeries in this study. The interval between the injury and the definitive operation ranged from several hours to ten days (mean 3 days). Any delay in the surgery was usually attributable to multiple trauma or poor medical condition of the patient. All fractures were treated with IV

antibiotics. Pre anaesthetic check up was done. Preparation of the required part (window shaving) was done prior to the surgery. Prerogative of the anesthesiologist. In all the patients spinal anesthesia was used.

### 2.3. *Supracondylar Nail*

It is a fully cannulated stainless steel condylo-cephalic nail with 5-degree distal anterior bend which is 3.8 cm proximal from the driving end. 8-degree ante curvature begins at 50 mm from the distal end, with a second bend 3 degree curve at 120 mm. Each nail has 5 mm diameter holes for locking in medial lateral direction. It is available in diameters of 10, 11, 12 mm and length varying from 15 to 25cm. The first generation nails had multiple 7-12 holes along the entire length of the nail with 20 mm intervals between adjacent holes.

#### 2.3.1. *Five hole design*

The problem of implant failure with multiple hole design has been eliminated with the removal of the central screw holes, reducing the size of the screw holes and enlarging the implant diameter, it has 3 holes at the distal end and 2 holes at 20.5 and 40.5 mm from the proximal end of the nail.

#### 2.3.2. *Locking screw*

These screws are made of stainless steel alloy 316L, with a thread diameter of 5mm, core diameter of 4mm and pitch of 1.3mm. It has self-tapping thread, which extends along the entire length of locking screw. Initially 6.4 mm locking bolts were used. Universally now 5 mm locking bolts are being used.

### 2.4. *Operative technique (Seligson and Henry green) positioning*

The procedure is performed on a radiolucent operating room table with the leg prepared out from the iliac crest to the middle of the calf. Sterile stockinet is placed over the foot and ankle. The position is supine with a bolster under the knee to flex the knee to 45°. Tourniquet is used

#### 2.4.1. *Surgical approach*

A 3 cm midline longitudinal incision from the inferior rim of the patella to the tibial tuberosity followed by a medial parapatellar arthrotomy. The knee is flexed to expose the entire articular surface.

#### 2.4.2. *Entry point*

It is made centrally between the condyles in the sulcus intercondylaris, approximately 1 cm anterior to the insertion of the posterior cruciate ligament. A stout guide pin is then inserted just above Blumensaat's line, the roof of the intercondylar notch, under fluoroscopic guidance on the lateral view.

#### 2.4.3. *Reaming technique*

A rigid reamer, up to 13 mm, is used to open the distal femoral insertion site through the cartilage to the metaphyseal-diaphyseal junction. A ball-tipped guide rod is then inserted with a bend on the end to cross the fracture site and ream; internal rotation during insertion will aid in passing the guide wire.; Reamed in 0.5 mm increments up to 12 mm and to the depth matching the nail length chosen. The chuck and awl sleeve are then removed to leave the guide wire in place.

#### 2.4.4. *Nail length selection*

It is determined by comparing a second identical length guide wire positioned in contact with articular surface of distal femur verified by image intensifier. A radiographic ruler may also be used to determine the length of the nail. Nail diameter is also determined by the ruler apertures.

#### 2.4.5. *Insertion*

This is done by fitting the target device into the grooves of the distal extremity of the nail chosen, intraoperatively the target device should be positioned laterally and that the external radius of the nail must point anteriorly in the sagittal plane. The nail is correctly positioned in the medullary cavity when the distal extremity is 1-2 mm below the articular surface. The nail guide wire is removed after verifying position in both planes under image intensifier control.

#### 2.4.6. *Distal interlocking*

The guide sleeve and the tissue protector are assembled and placed over the most distal opening of the laterally positioned target device. A small skin incision is made. The assembled instruments pushed up against the lateral cortex. The 4.00 mm drill guide sleeve is pushed up through the guide sleeve. The lateral and medial cortex is drilled through using the 4.00 mm drill. The self-tapping 5 mm fully threaded screw is inserted via the guide sleeve and fixed into the near and opposite cortex with the screw driver. Repeat the above steps for the most proximal hole of the distal locking section. Both guide sleeves are removed and locked the middle hole of the distal locking section and verified in both planes using the image intensifier.

#### 2.4.7. *Proximal locking*

Rotation, length correction and correction of any misalignment can be done at this stage. Free hand method under image intensifier is used. With this operative technique, distal hole of proximal interlocking section is always carried out over the posterior (downwards facing) side of the target device. The guide sleeve and the tissue protector are assembled and positioned over the opening of the target device. A small incision is made. The assembled instruments are pushed up against the Lateral cortex. The

awl is introduced through the guides leave and center punch made on the lateral cortex, but only by hand. This prevents the drill from running off center later. The 4.00 mm drill guide sleeve is pushed up through the guide sleeve. The near and opposite cortex is drilled through using the 4.00 mm drill. The self-tapping 5mm fully threaded screw is inserted via the guide sleeve and fixed into the near and opposite cortex with the screwdriver.

The knee is irrigated through the small, medial parapatellar tendon incision and the medial patellar tendon is sutured with an absorbable suture to the medial retinaculum. The lateral iliotibial band is closed over the distal screws and both skin incisions are closed. Subcutaneous and skin sutures are applied to the proximal incision over a suction drain

### 2.5. Post-operative care

**Day 1:** Continuous passive motion (CPM) machines may be used in 2-3 days postoperatively to enhance knee motion and decrease limb swelling but is not necessary in all cases. Splinting in 90 degrees knee flexion or placed in a Bohler Braun splint is advised.

**Day 2:** Suction drain was removed after 48 hours. Antiseptic dressing done Physiotherapist supervised isometric and range of motion exercises begun.

**Day 3:** Gait training progressed from use of parallel bars to a walker or crutches, with weight bearing as determined by the stability of the fixation intraoperatively. In patients with stable internal fixation, touch down weight bearing of the affected extremity was allowed. In patients with comminuted fractures and with relatively unstable fixation, weight bearing is delayed until radiological evidence of fracture healing and a fracture brace may be needed.

**Day 10 to 12:** Suture removal. Antiseptic dressing done. Patient is discharged with advice to continue physiotherapy as advised and to come for follow up after 3 weeks and later 3 months, 6 months, 18 months and 24 months. At each follow up, X-rays were taken and ROM was assessed and Neer's scoring was done. By 6 weeks if x-ray showed signs of union progression, increased weight bearing can be allowed. By 12 weeks, with further evidence of radiological consolidation, full weight bearing can be allowed

### 3. Results

Total number of cases treated in department of orthopaedics May 2019 to November 2020 are 30 cases of supracondylar fractures of femur and among them 30 out of 30 cases are followed till union occurred all cases are unilateral, there were no vascular or neurological deficits.

Coming to the age incidence 10 cases belonged to the age group of 30 to 40, 8 belonged to the age group of 40 to 50 and 12 belonged to the age group of 50 to 75. Male preponderance was associated. (Table 1)

**Table 1:** Demographic details in present study

| Age intervals in years               | Number of cases | Percentages |
|--------------------------------------|-----------------|-------------|
| 30-40                                | 10              | 33.3        |
| 41-50                                | 8               | 26.7        |
| 51-75                                | 12              | 40          |
| <b>Gender</b>                        |                 |             |
| Males                                | 22              | 73.3        |
| Females                              | 8               | 26.7        |
| <b>Type of Injury</b>                |                 |             |
| High velocity road traffic accidents | 18              | 60          |
| Fall from height                     | 12              | 40          |
| <b>Type of fractures</b>             |                 |             |
| Muller type A1                       | 11              | 36.67       |
| Muller type A2                       | 8               | 26.67       |
| Muller type A3                       | 11              | 36.67       |
| <b>Side of fracture</b>              |                 |             |
| Right                                | 20              | 66.7        |
| Left                                 | 10              | 33.3        |

18 fractures occurred due to high velocity road traffic accidents in the form of direct collision of vehicles or fall from moving vehicles or hitting stationary objects like trees and the 12 fractures were due to fall from height like trees and stairs.

There were 11 cases of Muller type A1 fractures, 8 cases of muller type A2 and 11 cases of muller type A3, there were no compound fractures involved in the study.

Coming to the side of injury 20 fractures were right sided and 10 were left sided.

The 6 Type A1 fractures treated by supracondylar nail healed radiologically at an average of 15 weeks whereas the 5 treated by locking compression plate took an average of 17.6 weeks. The 3 type A2 fractures treated by supracondylar nail had average union at 13.3 weeks and 5 cases treated by locking compression plate had an average union at 15.2 weeks.

The 6 type A3 fractures treated by supracondylar nail showed radiological healing at 16.3 weeks on an average whereas those treated by locking compression plate showed union at 15 weeks on an average.

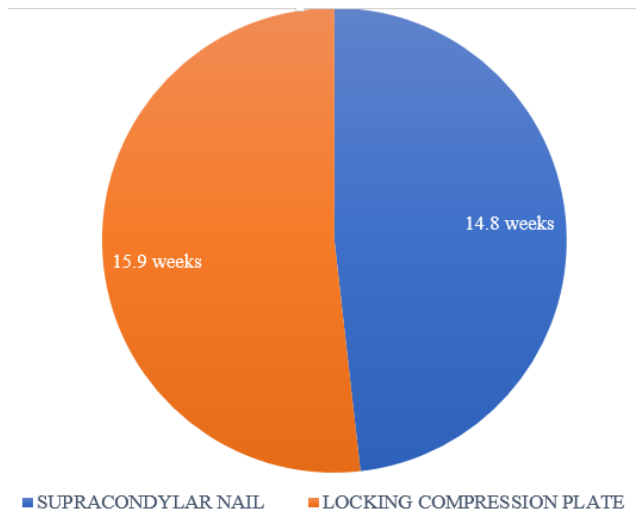
All fractures have shown radiological union in between 11 to 20 weeks, mullers A1 fractures have taken an average time of 16.1 weeks to heal. Mullers A2 took 14.5 weeks to heal. Mullers type A3 fractures healed at 15.7 weeks radiologically. (Table 2)

Out of 30 cases those treated by supracondylar nail had an average healing time of 14.8 weeks and those treated by locking compression plate had an average healing time of 15.9. (Figure 1)

The 6 cases of type A1 fractures treated by supracondylar nail had an average range of movement of 79.1 degree of active flexion, the 5 cases treated by locking compression plate had an average range of movement of 72 degree of

**Table 2:** Radiological healing after treatment in both groups

| Type of fractures | Supracondylar nail technique treated in | Radiological healing | Locking compression plate technique treated in | Radiological healing | Average time of healing |
|-------------------|---|----------------------|--|----------------------|-------------------------|
| Muller type A1    | 6 cases                                 | 15 weeks             | 5 cases  | 17.6 weeks           | 16.1 weeks              |
| Muller type A2    | 3 cases                                 | 13.3 weeks           | 5 cases  | 15.2 weeks           | 14.5 weeks              |
| Muller type A3    | 6 cases                                 | 16.3 weeks           | 5 cases  | 15 weeks             | 15.7                    |

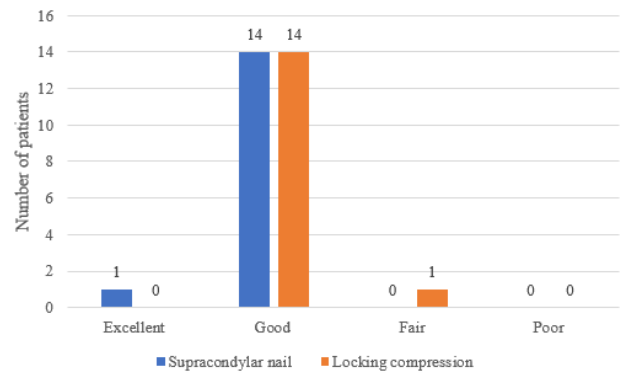
**Fig. 1:** Time taken for radiological union supracondylar nail vs locking compression plate in weeks**Table 3:** Range of movements & scoring:

| Type of fracture | Number of cases | Range of movement |
|------------------|-----------------|-------------------|
| Muller type A1   | 6 cases         | 79.1              |
|                  | 5 cases         | 72                |
| Muller type A2   | 3 cases         | 76.3              |
|                  | 5 cases         | 77                |
| Muller type A3   | 6 cases         | 80                |
|                  | 5 cases         | 76                |

active flexion. The 3 cases of type A2 fracture treated by supra condylar nail had an average active movement of 76.3 degree of active flexion and five cases treated by locking compression plate had an active flexion of 77 degrees.(Table 3)

The 6 cases of type A3 fracture treated by supracondylar nail had an average range of movement of 80 degrees and the 5 cases treated by locking compression plate had an average movement of 76 degrees.

It was found that 5 cases of typeA1 treated by supracondylar nail had good score and 1 case had excellent score, among those fixed with locking compression plate 5 cases had good score. In case of mullers type A2 fractures fixed by supracondylar nail 3 cases had good score, and among the 5 cases treated by locking compression plate, 4

**Fig. 2:** The clinical assessment of the outcome of the fractures was done using Neers scoring

had a score of good and 1 case had a score of fair.(Figure 2 )

In case of mullers A3 among 11 cases 6 cases fixed by supracondylar nail were scored as good and 5 fixed by locking compression plate . Among the 30 cases of supracondylar fracture fixed by supracondylar nail 14 were scored as good and one was scored as excellent, whereas those fixed by locking compression plate 14 were scored as good and 1 cases was scored as fair.

### 3.1. Duration of hospital stay, intraoperative & postoperative complications

Out of 30 cases fixed 14.9 days was the average number of days of hospital stay for those fixed with supracondylar nail and 12.6 days for those fixed with locking compression plate Out of 30 cases of supracondylar fracture fixed none had any intraoperative complications barring one which had break of drill bit intraoperatively and stayed insitu to the bone, there were no instances of surgical wound infections, both postoperative and post discharge period was uneventful as far as the surgical wound infections were concerned. The intraoperative blood loss was significantly lower when the fractures were fixed by supracondylar nail which averaged to 150ml when compared to the fixations by locking compression plate which averages to 300ml.

#### 4. Discussion

Distal femur fractures occur following high-energy impact in young patients often resulting in comminuted and open fractures, whereas, low energy injury is sufficient to cause distal femoral fractures in elderly patients with osteopenic or osteoporotic bone. For the treatment of distal femoral fractures, two major therapeutic principles can be employed: supracondylar nailing or distal femoral locking compression plate. The protection of soft-tissue envelopes due to minimally invasive approach and closed reduction techniques is best accomplished by IM nailing. The feasibility and the functional outcome of cases of supracondylar fractures of femur, by fixation with locking compression plates, retrograde intramedullary supracondylar nailing and dynamic condylar screw was studied in this study.

The study done by Lucas et al.<sup>6</sup> showed similar results to our study which showed

preponderance of younger patients with incidence 10 cases belonged to the age group of 30 to 40. Mean age reported 45 years by Jillala S R et al.<sup>7</sup> and Pascarella R et al.<sup>8</sup> reported mean age as 51 and 62 years respectively. Virk J S et al.,<sup>9</sup> reported it as 36.64 years and Batchelor E et al.<sup>10</sup> as 64.7 years, Acharya K N et al.<sup>11</sup> as 41 years and Rathi N B et al.<sup>12</sup> as 41.27 years.

High male preponderance was seen in the younger age group. 22 cases (73.3%) males and 8 cases of females (26.7%) are noted in study. In the studies conducted by Jillala S R et al.,<sup>7</sup> there were 31 (54.38 %) males and 26 (45.61%) females, Daroch M S et al.<sup>13</sup> reported as males are more commonly involved with 25 males (83.33%) as compare to females with 5 Cases (16.67%) because males are involved more in outdoor activities, Pascarella R et al.<sup>8</sup> reported female predominance with 35 male and 54 female patients, Acharya K N et al.<sup>11</sup> reported 20 male and 7 female patients among study population.

In present study 18 fractures occurred due to high velocity road traffic accidents in the form of direct collision of vehicles or fall from moving vehicles or hitting stationary objects like trees and the 12 fractures were due to fall from height like trees and stairs. Jillala S R et al.<sup>7</sup> and Daroch M S et al.<sup>13</sup> observed 56% and 96.66% of patients sustained injury due to roadside accidents respectively. Virk J S et al.<sup>9</sup> observed 80 % of their cases having road traffic accidents as their cause.

There were 11 cases of Muller type A1 fractures, 8 cases of muller type A2 and 11 cases of muller type A3, there were no compound fractures involved in the study. Coming to the side of injury 20 fractures were right sided and 10 were left sided. In study done by Ajay Kurahatti et al.<sup>14</sup> 19 cases (63.3%) had right sided fracture, and left side was affected in 11 cases (36.7%) had left sided fracture among both LCP and DFN group.

All fractures have shown radiological union in between 11 to 20 weeks, Out of 30 cases those treated by supracondylar nail had an average healing time of 14.8 weeks and those treated by locking compression plate had an average healing time of 15.9. Which was comparable to Virk J S et al.<sup>9</sup> and Pascarella R et al.<sup>8</sup> who observed it to be 19 and 16.3 weeks respectively. Union was defined as bridging of three of the four cortices. Daroch M S et al.<sup>13</sup> achieved union at an average of 14 weeks and Jillala S R et al.<sup>7</sup> at 15.6 weeks, Time taken for union for Nailing: In present study, average healing time in weeks was 20 which was comparable to Rathi N B et al.<sup>15</sup> study with 24 weeks and Acharya K N et al.<sup>11</sup> with 19 weeks. Neubauer T H et al.<sup>16</sup> shows osseous healing occurred in shaft fractures in 18.1 weeks on an average compared to 16.5 weeks in distal femur fractures. Jillala S R et al.<sup>7</sup> showed healing at 13.4 weeks.

In our study among the 30 cases of supracondylar fracture fixed by supracondylar nail 14 were scored as good and one was scored as excellent, whereas those fixed by locking compression plate 14 were scored as good and 1 cases was scored as fair. In LCP, Daroch M S et al.<sup>13</sup> had 33.34% of patients had excellent results and Virk J S et al.<sup>9</sup> had 80% excellent results. In nailing, Acharya K N et al.<sup>11</sup> had 77% excellent result and Rathi N B et al.<sup>15</sup> showed 50% excellent results.

Out of 30 cases fixed 14.9 days was the average number of days of hospital stay for those fixed with supracondylar nail and 12.6 days for those fixed with locking compression plate Out of 30 cases of supracondylar fracture fixed none had any intraoperative complications. The intraoperative blood loss was significantly lower when the fractures were fixed by supracondylar nail which averaged to 150ml when compared to the fixations by locking compression plate which averages to 300ml. Supracondylar fractures remain a significant challenge to the orthopaedic surgeon, the significant forces applied to this area even during restricted patient activity require a strong implant, severe comminution often requires fixation of multiple independent fragments with one device to minimize soft tissue damage, adults with axially unstable fractures with more than 5 cms of joint should be treated with a lateral fixed angle device, but a retrograde femoral nail is also acceptable, strict adherence to the AO-AISF techniques ,including interfragmentary compression, indirect reduction, preservation of soft tissue attachments& bone grafting is to be followed.

#### 5. Conclusion

From the observations and results of the current study it can be deduced and concluded that the supracondylar nail is more ideal when compared to the distal femoral locking compression plate as there is less operation time, less blood loss, more range of movement, less soft tissue

stripping & faster radiological union when compared to the distal femoral locking compression plate. Controversy still remains regarding the optimum device for the distal femur fixation, no one implant is suited for all fractures. The type of fixation selected depends on patient variables, fracture personality & soft tissue quality.

Minimal soft tissue stripping internal fixation of displaced supra condylar fractures has gained wide spread acceptance as operation techniques, properly designed implants, better understanding of soft tissues ,preoperative antibiotics & improved anesthetic measures have made internal fixation safe.

## 6. Conflict of Interest

No conflict of interest.

## 7. Source of Funding

None.

## References

- Whittle AP, and GIW. Campbell's operative orthopedics. In: Fractures of Lower Extremity, 10th edn.. vol. 3. Mosby Inc; 2003.
- Arneson TJ, 3rd LM, Lewallen DG. Epidemiology of diaphyseal and distal femoral fractures in Rochester, Minnesota, 1965-1984. *Clin Orthop*. 1965;(234):188–94.
- Schandelmaier P, Partenheimer A, Koenemann B, Grün OA, Krettek C. Distal femoral fractures and LISS stabilization. *Injury*. 2001;32(3):55–63. doi:10.1016/s0020-1383(01)00184-x.
- Stewart MJ, Sisk TD, Wallace SL. Fractures of the distal third of the femur. *J Bone Joint Surg*. 1966;48(4):784–807.
- Neer CS, Grantham SA, Shelton ML. Supracondylar fracture of the adult femur. *J Bone Joint Surg*. 1967;49(4):591–613.
- Lucas SE, Seligson D, Henry SL. Intramedullary supracondylar nailing of femoral fractures: A preliminary report of the GSH Supracondylar Nail. *Clin Orthop*. 1993;(296):200–6.
- Jillala SR, Ahmed S, Shruthi A, Gajul R, Katikitala A, Rakesh K, et al. A Comparative Study of Supracondylar Nail versus Locking Compression Plate in Distal Femur Fractures. *Ann Int Med Dent Res*. 2017;3(4):35–41.
- Pascarella R, Bettuzzi C, Bosco G, Leonetti D, Dessi S, Forte P, et al. Results in treatment of distal femur fractures using polyaxial locking plate. *Strat Traum Limb Recon*. 2014;9(1):13–8. doi:10.1007/s11751-013-0182-7.
- Virk JS, Garg SK, Gupta P, Jangira V, Singh J, Rana S, et al. Distal Femur Locking Plate: The Answer to All Distal Femoral Fractures. *J Clin Diagn Res*. 2016;10(10):RC01–5. doi:10.7860/JCDR/2016/22071.8759.
- Batchelor E, Heal C, Haladyn JK, Drobetz H. Treatment of distal femur fractures in a regional Australian hospital. *World J Orthop*. 2014;5(3):379–85.
- Acharya KN, Rao MR. Retrograde nailing for distal third femoral shaft fractures: a prospective study. *J Orthopaedic Surg*. 2006;14(3):253–8.
- Rathi NB, Solanki RA, Patel HA, Tank PJ. Study of Retrograde Intramedullary Nailing In Distal One Third Shaft Femur Fracture. *IOSR J Dent Med Sci*. 2016;15(4):18–23.
- Daroch MS, Vashisht D, Sreen S. Management of intraarticular fracture of distal femur with LCP and Lag screws in adults. *Int J Res Med Sci*. 2017;5(4):1434–8.
- Kurahatti A, Prabhu E, Naik SV, Arun HS. Distal femur fracture, a comparative study of locking compression plate versus distal femur nail. *Int J Orthop Sci*. 2019;5(2):793–8.
- Rathi NB, Solanki RA, Patel HA, Tank PJ. Study of Retrograde Intramedullary Nailing In Distal One Third Shaft Femur Fracture. *IOSR Journal of Dental and Medical Sciences*. 2016;15(4):18–23.
- Neubauer TH, Ritter E, Potschka TH, Karlbauer A, Wagner M. Retrograde Nailing of Femoral Fractures. *J Orthop Surg Traumatologiae Cechosl*. 2008;75:158–66.

## Author biography

**Jhatoth Dhoom Singh**, Associate Professor

**K. Raja Ratnam**, Associate Professor

**Cite this article:** Singh JD, Ratnam KR. A comparative study of the outcomes of fixation of fractures of distal femur by femoralnailing vs distal femoral locking compression plate. *Panacea J Med Sci* 2022;12(1):191-197.