



## Original Research Article

## Pulmonary tuberculosis: An observational study to compare radiographic abnormalities with reference to smear microscopy status

Shamrendra Narayan<sup>1</sup>, Hemant Kr Agarwal<sup>2</sup>, Arvind Kr Singh<sup>3</sup>, Dipti Agarwal<sup>4,\*</sup>, Manoj Pandey<sup>2</sup>

<sup>1</sup>Dept. of Radiodiagnosis, Dr. Ram Manohar Lohia Institute of Medical Sciences, Lucknow, Uttar Pradesh, India

<sup>2</sup>Dept. of Tuberculosis and Chest, Dr. Ram Manohar Lohia Institute of Medical Sciences, Lucknow, Uttar Pradesh, India

<sup>3</sup>Dept. of Community Medicine, Dr. Ram Manohar Lohia Institute of Medical Sciences, Lucknow, Uttar Pradesh, India

<sup>4</sup>Dept. of Pediatrics, Dr. Ram Manohar Lohia Institute of Medical Sciences, Lucknow, Uttar Pradesh, India



## ARTICLE INFO

## Article history:

Received 05-06-2021

Accepted 15-01-2022

Available online 17-08-2022

## Keywords:

Smear microscopy

Chest xray

Pulmonary tuberculosis

Diagnosis

## ABSTRACT

**Background:** Interpretation of Chest X Ray (CXR) in relation to sputum smear microscopy can be useful in early diagnosis of pulmonary TB. The study aimed to compare the CXR findings in pulmonary TB cases with positive sputum microscopy and negative sputum microscopy.

**Materials and Methods:** Patients with presumptive pulmonary TB were grouped into smear positive pulmonary TB and smear negative pulmonary TB groups based on CXR and sputum smear microscopy.

**Statistical analysis:** CXR findings in the two groups were compared using chi square and students- t test.

**Results:** A total of 225 patients with presumptive pulmonary TB were evaluated. Of these, 174 subjects were included in the study: 129 (74.2%) in smear positive pulmonary TB group and 45(25.8%) in smear negative pulmonary TB group. Parenchymal involvement was the most common finding in both smear positive and smear negative groups seen in 118 (91.5%) and 42 (93.3%) subjects, respectively. The area of parenchymal involvement was significantly more in smear positive group as compared to smear negative group ( $p < 0.001$ ). Cavitation was more commonly associated with smear positive group ( $p = 0.005$ ) Nodal enlargement was significantly more common among smear negative subjects ( $p < 0.001$ ).

**Conclusion:** CXR could detect 25.8% smear negative pulmonary TB cases. Extensive parenchymal infiltration and cavitation were more commonly associated with smear positive patients whereas nodal involvement was significantly more common in smear negative patients.

This is an Open Access (OA) journal, and articles are distributed under the terms of the [Creative Commons Attribution-NonCommercial-ShareAlike 4.0 License](https://creativecommons.org/licenses/by-nc-sa/4.0/), which allows others to remix, tweak, and build upon the work non-commercially, as long as appropriate credit is given and the new creations are licensed under the identical terms.

For reprints contact: [reprint@ipinnovative.com](mailto:reprint@ipinnovative.com)

## 1. Introduction

Tuberculosis (TB) is one of the major public health problems globally. According to the World Health Organization in 2018, 10 million individuals became ill with TB and about 1.6 million died of the disease.<sup>1</sup> India has the highest TB burden representing 23% of the total global burden.<sup>1</sup> Prompt diagnosis of TB facilitates timely therapeutic interventions and minimizes community

transmission.<sup>2</sup> For the diagnosis of pulmonary TB, smear microscopy and culture of the respiratory specimen are considered as the gold standard. Culture has the disadvantage of long turn-around time, which limits its usefulness as an initial diagnostic test. Smear microscopy is a rapid technique with moderate sensitivity and can be used for early diagnosis.<sup>3</sup>

It has been reported that smear microscopy is not able to diagnose around 42% cases of pulmonary TB.<sup>4</sup> Although patients with smear negative pulmonary tuberculosis are less infectious than smear positive cases, but they contribute to

\* Corresponding author.

E-mail address: [drdiptiagarwal@yahoo.co.in](mailto:drdiptiagarwal@yahoo.co.in) (D. Agarwal).

17% of transmission of infection.<sup>4</sup> In order to increase case detection including developing more sensitive approaches for identifying TB cases, chest X Ray (CXR) has been used as early screening tool for TB diagnosis in algorithms used by WHO.<sup>5</sup>

Radiographic changes are helpful in diagnosis of both smear positive as well as smear negative pulmonary TB cases. Interpretation of CXR findings and their association with sputum smear microscopy can result in early diagnosis. Present study aims at describing the CXR findings in pulmonary TB cases with positive sputum microscopy as compared with negative sputum microscopy.

## 2. Materials and Methods

This observational study was conducted on patients ( $\geq 18$  yrs) with presumptive pulmonary TB presenting in the department of pulmonary medicine of a tertiary hospital from January 2019 to March 2020. The study was approved by the ethical committee of the institute. Informed consent was obtained from the study subjects enrolled in the study.

Patients presenting with symptoms suggestive for pulmonary TB (cough for  $>2$  weeks, fever, night sweats, weight loss, or haemoptysis) during the study period were taken as presumptive pulmonary tuberculosis. Patients with prior history of anti tubercular therapy and HIV infection were excluded from the study. All the study subjects underwent CXR and sputum smear microscopy. Smear microscopy was performed on two samples using Ziehl Neelsen stain. Those with smear negative results were subjected to cartridge based nucleic acid amplification test (CBNAAT). In patients where bacteriological confirmation could not be obtained but had CXR suggestive for pulmonary TB was categorized as clinically diagnosed pulmonary TB after ruling out alternative diagnosis such as pneumonia, interstitial lung diseases, inflammatory disorders or malignancy (figure 1). Patients with alternative diagnosis were excluded from the study.

Based on the results of sputum smear microscopy, cases were grouped into smear positive pulmonary TB and smear negative pulmonary TB groups (Figure 1).

**Smear positive pulmonary TB-** Patients with clinical symptoms and CXR suggestive for pulmonary TB with two sputum samples positive on smear microscopy were grouped as smear positive pulmonary TB.

**Smear negative pulmonary TB-** Patients with negative smear microscopy with positive CBNAAT or clinically diagnosed cases with suggestive CXR and clinical symptoms were grouped as smear negative pulmonary TB.

CXR were reported by two radiologists who were blinded to smear status. The CXR was reported in a structured format. The lesions were noted as - nodal, pleural and parenchymal. Parenchymal involvement or consolidation was reported on opacification of airspaces with or without irregular margins. Nodal enlargement was

noted as round densities in the hilar and paratracheal location. Lucency within lung parenchyma with or without irregular margins was reported as cavitation. Presence of fluid within pleural space was read as pleural effusion. Parenchymal involvement was reported in six zones-upper, middle and lower zones of right and left side. Severity score was calculated on the basis of Timika score.<sup>6</sup> Miliary form and cavitation was also noted. Any gross discrepancy in observation were sorted out on consensus.

**Statistical analysis-** The obtained data was analyzed by means of frequency distribution table and descriptive statistics using IBM SPSS version 20. Chi square test and student- t test was used for comparing the CXR findings in smear positive pulmonary TB subjects with smear negative pulmonary TB subjects. P values  $< 0.05$  were considered statistically significant.

## 3. Results

A total of 225 patients with presumptive pulmonary TB were evaluated. Of these, 174 subjects were included in the study; 129(74.2%) in smear positive pulmonary TB group and 45(25.8%) in smear negative pulmonary TB group. The flow chart of the selection of study subjects has been shown in the Figure 1. Among smear negative subjects, 14 (31.1%) was bacteriologically confirmed and 31 (69.1%) were clinically diagnosed after ruling out other alternative diagnosis. Alternative diagnosis found were interstitial lung disease in 5 subjects and malignancy in 3 subjects.

The mean age of the subjects was 38.2 years in smear positive pulmonary TB group and 44.3 years in smear negative pulmonary TB group. Majority of the patients were males in both the groups with 82 (63.5%) and 26 (57.7%) respectively.

CXR findings in the smear positive pulmonary TB patients and smear negative pulmonary TB patients have been shown in Table 1. Parenchymal involvement was the most common finding in smear positive pulmonary TB patients seen in 118 (91.5%) cases followed by cavitation in 46(35.6%) cases. Among smear negative pulmonary TB patients, parenchymal involvement was most common finding seen in 42 (93.3%) subjects followed by nodal involvement seen in 11 (24.4%) subjects. Cavitation was seen in significantly higher number of cases of smear positive pulmonary TB than in smear negative group where cavity was seen in only 6 cases (13.3%) ( $p=0.005$ ). When comparing parenchymal involvement there was no significant difference between the two groups. However, the area of parenchymal involvement as determined by Timika score was more in smear positive group as compared to smear negative group ( $p<0.001$ ). Right upper and middle lobe was most commonly involved in smear positive pulmonary TB cases which was significantly more than smear negative pulmonary TB cases ( $p< 0.001$ ). Left upper lung and middle lobe lung involvement was more frequently

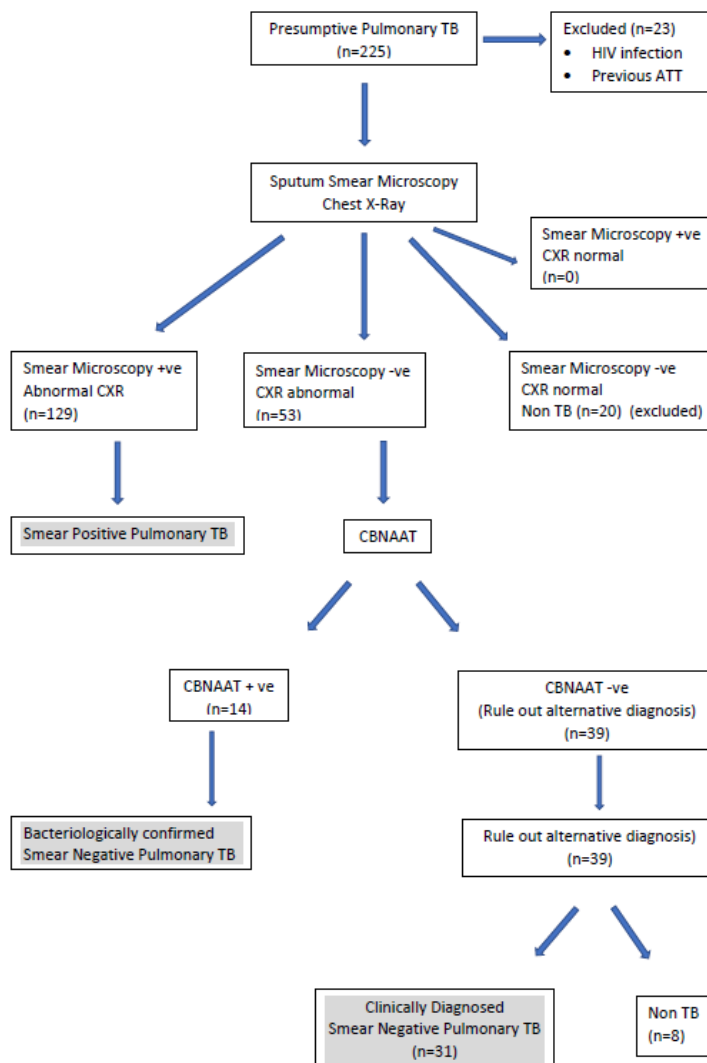


Fig. 1: Flow chart of study subject selection

Table 1: Comparison of chest X Ray finding of smear positive pulmonary TB (n=129) with smear negative pulmonary TB (n=45)

Chest X Ray findings	Smear positive pulmonary TB group n (%)	Smear negative pulmonary TB group (%)	p- value
Lung parenchyma	118 (91.5%)	42 (93.3%)	0.693
Right Upper	79 (61.2%)	11 (24.4%)	<0.001
Right mid	83 (64.3%)	15 (33.3%)	<0.001
Right lower	32 (24.8%)	10 (22.2%)	0.727
Left upper	74 (57.8%)	18 (40.0%)	0.045
Left mid	79 (61.2%)	21 (46.7%)	0.089
Left lower	30 (23.2%)	14 (31.1%)	0.297
Nodal enlargement	6 (4.6%)	11 (24.4%)	<0.001
Cavity	46 (35.6%)	6 (13.3%)	0.005
Pleural effusion	25 (19.38%)	7 (15.5%)	0.569
TIMIKA Score	22.02+ _18.48	39.28+ _24.9	<0.001

involved in smear positive pulmonary TB cases as compared to smear negative pulmonary TB ( $p=0.045$  and  $p=0.089$ ) respectively.

Pleural pathology was comparable in both the groups with involvement seen in 19.38 % and 15.6% ( $p=0.569$ ) respectively. Smear negative individuals showed nodal involvement in 11 (24.4%) cases which was significantly higher as compared to smear positive cases which showed nodal involvement in only 6 (4.7%) cases ( $p<0.001$ ).

#### 4. Discussion

Chest X Ray is the most sensitive tool for diagnosing pulmonary TB. It has historically been one of the primary tools for detecting pulmonary TB. Earlier CXR was placed at the bottom of diagnostic algorithm, but recently it has been promoted as initial screening tool. The 2010 guidelines of WHO has placed it as the first step for diagnosing presumptive pulmonary TB cases.<sup>5</sup> Active pulmonary tuberculosis is suggested by consolidation, cavitation, lymph nodal involvement, pleural effusion and miliary mottling.<sup>7</sup> This study describes the CXR findings in pulmonary TB patients and compares findings of smear positive with smear negative pulmonary TB patients.

Diagnosis of smear negative pulmonary TB is difficult especially in resource limited settings where molecular tests are not widely available. It has been reported that there are about 1.22 cases of smear negative pulmonary TB case for each smear positive pulmonary TB.<sup>8</sup> In the 2016, national prevalence survey from India, it was reported that there would be an additional 30-40% diagnostic yield using CXR as a screening tool.<sup>5</sup> In our study there were 25.8% smear negative pulmonary TB cases diagnosed by CXR. In a study conducted on prisoners, it was suggested that 20% of smear negative subjects could have been missed if radiographic changes were neglected.<sup>9</sup> In another study 14.8% smear negative patients had CXR findings suggestive of pulmonary TB.<sup>10</sup>

In our study most common finding on CXR in smear negative pulmonary TB patients was parenchymal involvement followed by nodal lesions. In a study in 159 smear negative pulmonary TB patients, the most common CXR finding was consolidation (40.3%) followed by cavitation (23.9%) and nodular lesions (17.0%).<sup>11</sup> On comparison of CXR findings, the extent of parenchymal infiltration and cavitation was significantly higher in sputum-positive pulmonary TB subjects in comparison with sputum-negative pulmonary TB. Similar has been reported in a study showing parenchymal lesions and cavity to be more common in smear positive patients as compared to smear negative patients.<sup>12</sup> In another Indian study frequency of patchy consolidation (78.9% vs 49.5%) and cavitation (36.8% vs 15.6%) was significantly higher in smear positive patients.<sup>2</sup> CXR features of smear negative pulmonary TB cases differs from smear positive pulmonary TB cases

probably due to lower bacillary load. Parenchymal lobe involved showed upper and middle lobes to be more commonly involved. Right upper lobe was reported to be most commonly involved site in smear positive subjects.<sup>2</sup> In another study in smear positive individuals right upper lobe was found to be involved in 53.8% followed by left upper lobe in 41.2%.<sup>13</sup> In our study upper lobes were more commonly involved in smear positive cases but there was no predilection of lobe involvement in the smear negative subjects.

Some findings were found to be more commonly associated with smear negative pulmonary TB. In our study nodal involvement was seen more commonly in smear negative individuals as also observed by another study.<sup>2</sup> Hilar and mediastinal adenopathy were reported to be associated more commonly with smear negative pulmonary TB individuals.<sup>14</sup> In contrast, another study had shown mediastinal widening and hilar adenopathy to be significantly more common in smear positive patients.<sup>12</sup> Pleural involvement was seen similarly in both smear positive and negative groups in our study. Some studies have found pleural involvement to be more common with sputum-negative pulmonary TB although not statistically significant.<sup>2</sup>

CXR has the disadvantage of over diagnosis as some of the abnormalities may be seen in other conditions as well.<sup>15</sup> In a study among smear negative pulmonary TB proportion of overdiagnosis with CXR was reported to be 23%.<sup>16</sup> In our study smear negative patients with suggestive CXR were confirmed using CBNAAT. Application of CBNAAT in smear negative pulmonary TB individuals can help confirming the diagnosis.<sup>17</sup> Moreover systematic reporting and carefully ruling out alternative diagnosis can reduce the possibility of overdiagnosis.

We did not use culture as a reference standard which would have allowed more robust comparison which is a limitation of the study. However, culture is not a useful diagnostic tool for pulmonary TB in high burden countries. Small sample size is another limitation of the study.

Interpretation of chest X-Ray findings is important for early diagnosis of pulmonary TB subjects. Extensive parenchymal infiltration and cavitation on CXR were found to be more commonly associated with smear positive pulmonary TB patients whereas nodal involvement was significantly more often in smear negative patients. CXR could detect 25.8% smear negative pulmonary TB cases which would have been missed. Emphasis on using quality CXR in larger sample are required to establish utility of CXR in diagnosis of pulmonary TB.

#### 5. Conflicts of Interest

No potential conflict of interest relevant to this article was reported.

## 6. Source of Funding

None.

## References

- World Health Organisation. Global Tuberculosis report; 2018. Available from: [http://www.who.int/tb/publications/global\\_report/](http://www.who.int/tb/publications/global_report/).
- Rai DK, Kirti R, Kumar S, Karmakar S, Thakur S. Radiological difference between new sputum -positive and sputum -negative pulmonary tuberculosis. *J Family Med Prim Care*. 2019;8(9):2810–3. doi:10.4103/jfmpc.jfmpc\_652\_19.
- Lenguissi LS, Mayengue P, Sidibe A, Vouvongui JS, Missontsa M, Madzou LI, et al. Prevalence of national treatment algorithm defined smear positive pulmonary tuberculosis in HIV positive patients in Brazzaville. Republic of Congo. *BMC Res Notes*. 2014;7:578. doi:10.1186/1756-0500-7-578.
- Behr MA, Warren SA, Salamon H, Hopewell PC, De Leon AP, Daley CL, et al. Transmission of mycobacterium tuberculosis from patients smear negative for acid -fast bacilli. *Lancet*. 1997;353(9151):444–9. doi:10.1016/S0140-6736(98)03406-0.
- World Health Organization. (2016). Chest radiography in tuberculosis detection: summary of current WHO recommendations and guidance on programmatic approaches. World Health Organization. Available from: <https://apps.who.int/iris/handle/10665/252424>.
- Ralph AP, Ardian M, Wiguna A, Maguire GP, Becker NG, Drogumuller G, et al. A simple, valid, numerical score for grading chest x-ray severity in adult smear-positive pulmonary tuberculosis. *Thorax*. 2010;65(10):863–9. doi:10.1136/thx.2010.136242.
- Nachiappan CA, Rakhbar K, Shi X, Guy ES, Jr EB, Shroff GS, et al. Pulmonary Tuberculosis: Role of Radiology in Diagnosis and Management. *Radiographics*. 2017;37(1):52–72. doi:10.1148/rg.2017160032.
- Colebunders R, Bastian I. A review of the diagnosis and treatment of smear-negative pulmonary tuberculosis. *Int J Tuberc Lung Dis*. 2000;4(2):97–107.
- Jones TF, Schaffner W. Miniature chest radiograph screening for tuberculosis in jails: a cost effectiveness analysis. *Am J Respi Crit Care Med*. 2001;164(1):77–81. doi:10.1164/ajrccm.164.1.2010108.
- Hernandez-Garduno E, Cook V, Kunitomo D, Elwood R, Black W, Fitzgerald JM, et al. Transmission of tuberculosis from smear negative patients: a molecular epidemiology study. *Thorax*. 2004;59(4):286–90. doi:10.1136/thx.2003.011759.
- Tewelde E, Atnaufu A, Kebede T, Tedla Y, Assefa G, Bedane A, et al. Evaluating the validity and reliability of chest radiography in the diagnosis of tuberculosis among smear negative pulmonary tuberculosis patients. *Ethiop Med J*. 2015;53(2):83–9.
- Ebrahimzadeh A, Mohammadifard M, Naseh G. Comparison of chest X- Ray findings of smear positive and smear negative with pulmonary tuberculosis. *Iran J Radiol*. 2014;11(4):e13575. doi:10.5812/iranradiol.13575.
- Eini P, Osqee HO, Nasab MS, Khiyabani FN, Rahighi A. Chest radiological features among patients with smear positive pulmonary tuberculosis. *Caspian J Intern Med*. 2013;4(4):777–80.
- Gatner EM, Burkhardt KR. Correlation of the results of X Ray and sputum culture in tuberculosis prevalence surveys. *Tubercle*. 1980;61(1):27–31. doi:10.1016/0041-3879(80)90056-2.
- Tozkoparan E, Deniz O, Ciftci F, Bozkanat E, Bıcak M, Mutlu H, et al. The roles of HRCT and clinical parameters in assessing activity of suspected smear negative pulmonary tuberculosis. *Arch Med Res*. 2005;36(2):166–70. doi:10.1016/j.arcmed.2004.12.010.
- van Cleeff M, Kivihya-Ndugga L, Githui W, Nganga L, Odhiambo J, Klatser PR, et al. A Comprehensive study of the efficacy of the routine pulmonary tuberculosis diagnostic process in Nairobi. *Int J Tuberc Lung Dis*. 2003;7(2):186–9.
- Chopra V, Virk BS, Chopra S, Bansal M, Chungath J. Application of CBNAAT (Xpert MTB/RIF assay ) in smear negative pulmonary tuberculosis patients. *Monaldi Arch Chest Dis*. 2020;90(1). doi:10.4081/monaldi.2020.1146.

## Author biography

**Shamrendra Narayan**, Additional Professor

**Hemant Kr Agarwal**, Associate Professor

**Arvind Kr Singh**, Associate Professor

**Dipti Agarwal**, Additional Professor

**Manoj Pandey**, Senior Resident

**Cite this article:** Narayan S, Agarwal HK, Singh AK, Agarwal D, Pandey M. Pulmonary tuberculosis: An observational study to compare radiographic abnormalities with reference to smear microscopy status. *Panacea J Med Sci* 2022;12(2):350-354.