



Original Research Article

Foreign body in ear, nose and throat: Three year experience in a teaching hospital in Central India

Nitin Kumar Jain¹, Vipin Kumar Jain², Dileep Dandotiya³, Sushil Ojha⁴, Megha Jain^{5,*}

¹Dept. of ENT, Chhindwara Institute of Medical Sciences, Chhindwara, Madhya Pradesh, India

²Dept. of Pharmacology, Chhindwara Institute of Medical Sciences, Chhindwara, Madhya Pradesh, India

³Dept. of Community Medicine, Chhindwara Institute of Medical Sciences, Chhindwara, Madhya Pradesh, India

⁴Dept. of Ophthalmology, Government Doon Medical College, Dehradun, Uttarakhand, India

⁵Dept. of Dentistry, Chhindwara Institute of Medical Sciences, Chhindwara, Madhya Pradesh, India



ARTICLE INFO

Article history:

Received 03-01-2022

Accepted 25-02-2022

Available online 28-11-2022

Keywords:

ENT foreign bodies

Prevalence

Children

Hydrophobic

ABSTRACT

Introduction: Foreign body presentations in otolaryngology clinic are common and 11% of these were in emergency room of ENT hospitals. Paediatric populations were more commonly suffered from the ENT foreign bodies although adults were also suffered. Earlier studies have been done to found the prevalence, diagnosis, treatment and complication related to ENT foreign bodies, however in recent past none of the studies were conducted in our hospital. Hence this study will plan to find out the prevalence among children and adults.

Objective: To evaluate the prevalence of ENT foreign bodies in paediatric and adult population along with its types, lodgment in different sites and clinical findings.

Materials and Methods: The present study was conducted in ENT department, Chhindwara Institute of Medical Sciences, Chhindwara, Madhya Pradesh. Total number of patients attending ENT OPD and casualty were 354 between May 2018 to May 2021 included in present study. In collected data, demographic evaluation, different types of foreign bodies, their lodgment site and clinical features were evaluated.

Results: In our study maximum incidence were noted for foreign bodies of Nose 48.3% followed by 40.3% and 11.3% of Ear and Throat respectively and more common in 0-10 years of age in children with higher percentage of Nasal foreign bodies 34.7%. The types of foreign bodies which were common in both the children and adults were related to foodstuffs.

Conclusion: Presence of ENT foreign bodies are more common in children and type and site of lodgment of foreign bodies varied in different age band.

This is an Open Access (OA) journal, and articles are distributed under the terms of the [Creative Commons Attribution-NonCommercial-ShareAlike 4.0 License](https://creativecommons.org/licenses/by-nc-sa/4.0/), which allows others to remix, tweak, and build upon the work non-commercially, as long as appropriate credit is given and the new creations are licensed under the identical terms.

For reprints contact: reprint@ipinnovative.com

1. Introduction

Foreign body presentations in otolaryngology clinics are common and 11% of these were in emergency room of ENT hospitals.¹ An object is considered as a "foreign body" if the object is in a location in the body where it does

not belongs. Foreign body may be classified as living and nonliving. The non-living Foreign body can be classified as vegetative and non-vegetative, and hygroscopic and non-hygroscopic. Paediatric population were more commonly suffered from the ENT foreign bodies although adults were also suffered.² Presence of foreign bodies requires prompt diagnosis and early treatment by experts otherwise can cause increased morbidity and mortality along with cost

* Corresponding author.

E-mail address: megha.vipin12@gmail.com (M. Jain).

burden.³⁻⁵ Earlier studies have been done to find out the prevalence, diagnosis, treatment and complication related to ENT foreign bodies,⁶ However in recent past none of the studies were conducted in our tertiary care centre. Hence this study will plan to find out the prevalence among paediatric and adult population.

2. Objective

To evaluate the prevalence of ENT foreign bodies in paediatric and adult population along with types of foreign bodies, its lodgment in different sites and important clinical findings.

3. Materials and Methods

The present study was conducted in ENT department, Chhindwara Institute of Medical Sciences, Chhindwara, Madhya Pradesh. Total number of patients attending the ENT OPD and causality were 354 between the study duration of May 2018 to May 2021 included in present study. In collected data, demographic evaluation in term of age, gender and occupation as well as different types of foreign bodies, their lodgment site and clinical features were evaluated after taking detailed history with careful ENT examination. The study protocol was approved by the Institutional Ethics Committee, Chhindwara institute of medical sciences, Chhindwara, Madhya Pradesh.

4. Results

In our study the maximum incidence were noted for foreign bodies of Nose 171 (48.3%) followed by 143 (40.3%) and 40 (11.3%) of Ear and Throat respectively.[Tables 1 and 2][Table 3] The occurrence of ENT foreign bodies were more common in 0-10 years of age in children with higher percentage of Nasal foreign bodies 158 (44.6%).[Table 1]The types of foreign bodies which were common in both the children and adults population were related to foodstuffs with addition of small size objects like plastic toy specially in children.

4.1. Nose

Clinical findings: History given by parents and relatives who saw the foreign bodies in the nose in which, 123(34.7%) cases presented with unilateral, purulent and foul smelling nasal discharge with few patients with blood stained, 38 (10.7%) cases presented with nasal obstruction and remaining 10(2.8%) cases presented with nasal bleed.

Types of foreign body: seeds or nuts are the most commonly presented foreign bodies in nasal cavities which consist of 67(39.2%), followed by stone 23 (13.4%), cotton/paper 17(9.9%), plastic 16(9.3%) cases, chalk 12(7.0%) cases, and metal 11(6.4%), maggots/insects 9(5.2%), thermacol 8(4.6%), wood 6(3.5%) and others in

2(1.1%) cases. [Table 4]

4.2. Ear

Clinical findings: Most of the patients were asymptomatic, rest of the patients presented with history of alleged foreign bodies in the ear presenting with complaints of ear itching, otalgia, otorrhoea, and blocked ear.

Types of foreign body: Cotton was the commonest ear foreign bodies encountered which consisted of 41 (28.6%) cases. This was followed by matchstick in 37 (25.8%) cases, insects in 28 (19.5%) cases, pencil tip in 19 (13.3%) cases, plastic toys or moti in 12 (8.4%) cases, seeds or nuts in 4 (2.7%) cases, and others in 2 (1.4%) cases. [Table 5]

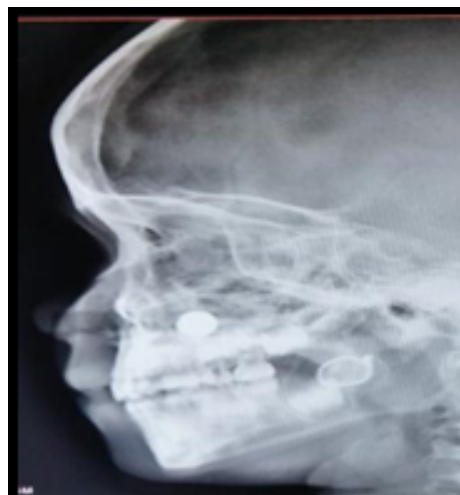


Fig. 1: FB in nose (battery)

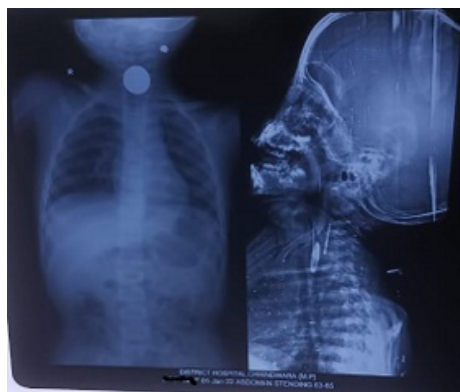

Fig. 2: FB in Cricopharynx (Coin)

4.3. Throat

Clinical findings: Most of the time patients were asymptomatic, history given by patient's guardian shows suspicion of any missing object. Rest of the patients

complains of pain during deglutition, foreign body sensation in throat and hyper salivation.

Type of foreign body: Fish bone 24(60%) is the most often found esophageal foreign body and tonsillar crypts is the most common site of lodgment followed by vallecula, base of tongue, pyriform fossa and least common in cricopharynx. Coin 12(30%) is the second most found foreign body in throat and its site of lodgment is cricopharynx.[Table 6] and others in 4(10%) cases.

Table 1: Nose foreign body in different age groups (n=171)

Age in years	No of cases	Percentage (%)
0-5	123	71.9
6-10	35	20.4
11-20	0	0.0
21-40	0	0.0
41-70	10	5.8
>71	03	1.7
Total	171	100.0

Table 2: Ear foreign body in different age groups (n=143)

Age in years	No of cases	Percentage (%)
0-5	78	54.5
6-10	29	20.2
11-15	21	14.6
16-20	0	0.0
21-40	08	5.5
41-70	07	4.8
> 71	01	0.6
Total	143	100.0

Table 3: Throat foreign body in different age groups (n=40)

Age in years	No of cases	Percentage (%)
0-5	24	60.0
6-10	02	5.0
11-20	0	0.0
21-40	12	30.0
41-70	02	5.0
> 71	0	0.0
Total	40	100.0

5. Discussion

In our study nasal foreign bodies showed the highest incidence (48.3%) followed by ear (40.4%), and throat (11.3%) which was similar to findings of other study⁷ although some studies have been shown aural foreign bodies were more common.^{1,8}The most commonly affected age group were 0-10 years in present study and these observation were similar to other studies also.^{9,10}Because of inefficient mastication with improper deglutition and exploratory behavior in form of putting objects in mouth and different body orifices as well as frequent crying

Table 4: Types of foreign body in nose (n=171)

Types of foreign body	No of cases	Percentage (%)
Seed/nuts	67	39.2
Stone	23	13.4
Cotton/paper	17	9.9
Plastic	16	9.3
Chalk	12	7.0
Metal	11	6.4
Maggots/insects	09	5.2
Thermacol	08	4.6
Wood	06	3.5
Others	02	1.1
Total	171	100.0

Table 5: Types of foreign body in ear (n=143)

Types of foreign body	No of cases	Percentage (%)
Cotton	41	28.6
Matchstick	37	25.8
Insects	28	19.5
Pensiltip	19	13.3
Plastic toy/ moti	12	8.4
Seed/nuts	04	2.7
Others	02	1.4
Total	143	100.0

Table 6: Types of foreign body in throat (n= 40)

Types of foreign body	No of cases	Percentage (%)
Fish bone	24	60.0
Coin	12	30.0
Others	04	10.0
Total	40	100.0

and shouting during playing make them vulnerable to affected with the foreign bodies.^{11,12} In present study observation revealed that in paediatric age group, seeds or nuts represented the commonest foreign bodies in nose (39.2%) and ear (2.7%) which was in accordance with the study by Barretto RL et al.¹³ The populations which were affected most belongs to farmers due to availability of vegetative and grains seeds in their houses although Higo et al in their study have been found higher incidence of plastic made toys in paediatric population.⁷ The observation in present study shown that cotton[28.6%] and matchstick [25.8%] were commonly encountered foreign bodies in adults along with the insects inside the ear were also frequently seen which was similar to findings of Antonelli PJ et al.¹⁴ For adults cases in our study the percentage of throat foreign bodies were exceeding the ear and nose foreign bodies. In our study in throat, fish bone (60%) and coin (30%) is the most common foreign bodies which was as per findings of study by Endican S et al.⁸ Management of foreign body in term of removal were successfully done

for majority of cases in outdoor basis with detailed history taking and thorough examination although in some cases general anaesthetic support was taken for removal of foreign bodies. In a prospective evaluation based study by Hon SK et al the possible complication related to presence of foreign bodies in either nose, ear and throat will be minimized if the patients were referred earliest to higher centre.⁶ For throat foreign bodies commonly found site of lodgment was tonsillar crept and cricopharynx in present study which was in accordance with other study.¹⁵

6. Conclusion

In conclusion the presence of ENT foreign bodies were more common in children and the type and site of lodgment of foreign bodies were varies in different age groups. However early diagnosis and referral reduce complications related to these foreign bodies and help in appropriate management.

7. Acknowledgment

The authors gratefully acknowledge patients enrolled for surgery, all nursing staff, and whole ENT department for their wholehearted participation in the study.

8. Conflict of Interest

None.

9. Source of Funding

None.

References

- Bressler K, Shelton C. Ear foreign-body removal: a review of 98 consecutive cases. *Laryngoscope*. 1993;103(4 Pt 1):367–70. doi:10.1002/lary.5541030401.
- Mukherjee A, Haldar D, Dutta S, Dutta M, Saha J, Sinha R, et al. Ear, nose and throat foreign bodies in children: a search for socio-demographic correlates. *Int J Pediatr Otorhinolaryngol*. 2011;75(4):510–2.
- Yuca K, Yuca SA, Caksen H. Aural live foreign bodies in children. *J Emerg Med*. 2003;25(1):102–4.
- Ansley JF, Cunningham MJ. Treatment of aural foreign bodies in children. *Pediatrics*. 1998;101(4 Pt 1):638–41. doi:10.1542/peds.101.4.638.
- Ologe FE, Dunmade AD, Afolabi OA. Aural foreign bodies in children. *Indian J Pediatr*. 2007;74(8):755–8. doi:10.1007/s12098-007-0133-8.
- Hon SK, Izam TM, Koay CB, Razi A. A prospective evaluation of foreign bodies presenting to the Ear, Nose and Throat Clinic, Hospital Kuala Lumpur. *Med J Malaysia*. 2001;56(4):463–70.
- Higo R, Matsumoto Y, Ichimura K, Kaga K. Foreign bodies in the aerodigestive tract in paediatric patients. *Auris Nasus Larynx*. 2003;30(4):397–401. doi:10.1016/s0385-8146(03)00087-7.
- Endican S, Garap JP, Dubey SP. Ear, nose and throat foreign bodies in Melanesian children: an analysis of 1037 cases. *Int J Pediatr Otorhinolaryngol*. 2006;70(9):1539–45.
- Banerjee S. Concept of foreign body, in past and present. *Indian J Otolaryngol Head Neck Surg*. 1999;51(Suppl 1):23–30. doi:10.1007/BF03001548.
- Das SK. Aetiological evaluation of foreign bodies in the ear and nose. *J Laryngol Otol*. 1984;98(10):989–91. doi:10.1017/s002221510014784x.
- Jyothi AC, Shrikrishna BH, Sanjay G, Sandeep SG, Chaitanya V. A clinical study regarding foreign bodies in aerodigestive tracts. *Odisha J Otolaryngol Head Neck Surg*. 2011;5(1):9–15.
- Shrestha I, Shrestha BL, Amatya RCM. Analysis of ear, nose and throat foreign bodies in dhulikhel hospital. *Kathmandu Univ Med J (KUMJ)*. 2012;10(38):4–8. doi:10.3126/kumj.v10i2.7334.
- Poznanovic SA, Holinger LD. Foreign bodies of the airway and esophagus. Available from: <https://entokey.com/foreign-bodies-of-the-airway-and-esophagus/>.
- Antonelli PJ, Ahmadi A, Prevatt A. Insecticidal activity of common reagents for insect foreign bodies of the ear. *Laryngoscope*. 2001;111(1):15–20.
- Ray R, Dutta M, Mukherjee M, Gayen G. Foreign body in ear, nose and throat: experience in a tertiary hospital. *Indian J Otolaryngol Head Neck Surg*. 2014;66(1):13–6.

Author biography

Nitin Kumar Jain, Assistant Professor

Vipin Kumar Jain, Assistant Professor

Dileep Dandotiya, Demonstrator

Sushil Ojha, Assistant Professor

Megha Jain, Assistant Professor

Cite this article: Jain NK, Jain VK, Dandotiya D, Ojha S, Jain M. Foreign body in ear, nose and throat: Three year experience in a teaching hospital in Central India. *Panacea J Med Sci* 2022;12(3):557-560.