



## Original Research Article

## Prevalence of hypertensive retinopathy among the known diabetics in a community-based setting using a non-mydriatic fundus camera

Saranya Rajaram<sup>1</sup>, Amod Hansdak<sup>2,\*</sup>, Newtonraj Ariarathinam<sup>1</sup>, Murugan Natesan<sup>1</sup>, Joy Bazroy<sup>1</sup>, Anil Jacob Purty<sup>1</sup>

<sup>1</sup>Dept. of Community Medicine, Pondicherry Institute of Medical Sciences, Puducherry, India

<sup>2</sup>Dept. of Ophthalmology, Pondicherry Institute of Medical Sciences, Puducherry, India



## ARTICLE INFO

## Article history:

Received 31-08-2021

Accepted 26-10-2021

Available online 28-11-2022

## Keywords:

Hypertensive retinopathy  
Nonmydriatic fundus camera  
Prevalence

## ABSTRACT

**Background:** Hypertension is a leading cause of morbidity and mortality and is associated with the risk of cardiovascular, cerebrovascular disease, and target organ damage. The risk increases exponentially in individuals with diabetes. Hypertensive retinopathy is a marker for target organ damage, so screening for hypertensive retinopathy helps in cardiovascular risk stratification. This study was conducted with an objective to screen for hypertensive retinopathy among known diabetics using a portable non-mydriatic fundus camera to ascertain its prevalence.

**Materials and Methods:** The study was conducted in three selected field practice areas of the Department of Community Medicine. A house-to-house survey was performed using a predesigned, pretested questionnaire among 302 known diabetics. The study participants were subjected to visual acuity examination using Snellen's chart and retinal fundus examination using a portable non-mydriatic Bosch Mobile Eye Care Solutions fundus camera. The fundus images were transferred to a laptop and were reviewed and graded by an experienced Ophthalmologist.

**Results:** Among the 302 participants studied, 60 were diagnosed with hypertensive retinopathy. The prevalence of hypertensive retinopathy among diabetic patients was 19.9 % (95% CI: 15.7% - 24.6%). The prevalence was found to be higher in \*\* (21.8%; 95% CI: 16% - 28.6%) as compared to \*\* (17.5%; 95% CI: 11.8% - 24.6%).

**Conclusion:** Early detection of hypertensive retinopathy with cardiovascular risk stratification and initiation of prompt treatment among the high-risk individuals will help reduce the morbidity caused due to end-organ damage and premature mortality to a greater extent and will pave the way forward to achieving sustainable developmental goals.

This is an Open Access (OA) journal, and articles are distributed under the terms of the [Creative Commons Attribution-NonCommercial-ShareAlike 4.0 License](https://creativecommons.org/licenses/by-nc-sa/4.0/), which allows others to remix, tweak, and build upon the work non-commercially, as long as appropriate credit is given and the new creations are licensed under the identical terms.

For reprints contact: [reprint@ipinnovative.com](mailto:reprint@ipinnovative.com)

### 1. Introduction

Systemic hypertension is a leading cause of morbidity and premature mortality worldwide and contributes to 7.6 million deaths globally annually. Premature mortality occurs predominantly due to cardiovascular, cerebrovascular, and renal diseases. Around 1.28 billion

adults in the world were diagnosed with hypertension, and approximately two-thirds of them live in low- and middle-income countries. Hypertension tends to be asymptomatic in the initial stages and is commonly detected by screening procedures.<sup>1,2</sup> An estimated 46% of hypertensive adults are unaware of their disease status. Hence, a large number of these subjects present with target organ damage on their first arrival at a hospital or clinic.<sup>3</sup>

\* Corresponding author.

E-mail address: [amodhansdak@yahoo.com](mailto:amodhansdak@yahoo.com) (A. Hansdak).

Diabetes and hypertension are a dual burden to the health care system as they often exist together. Hypertension affects approximately 70% of diabetic patients.<sup>4</sup> Both diabetes and hypertension are vascular risk factors and significantly increase the risk of ischemic cerebrovascular disease and retinopathy.<sup>5</sup> When diabetes and hypertension coexist, the risk of cardiovascular diseases increases exponentially. Similarly, retinopathy becomes rapidly progressive due to endothelial dysfunction and results in accelerated diabetic retinopathy, causing subsequent damage to the eyes and visual impairment. Diabetic retinopathy is a potentially blinding condition, while hypertensive retinopathy is not as devastating for vision as diabetic retinopathy but serves as a marker for end-organ damage. Place alongside this fact that systemic hypertension is also a risk factor for several potentially blinding conditions like (i) central retinal artery occlusion, (ii) branch retinal artery occlusion, (iii) central retinal vein occlusion, (iv) branch retinal vein occlusion, (v) glaucoma, (vi) age-related macular degeneration, and (vii) suprachoroidal hemorrhage during ophthalmic surgeries.<sup>6</sup> Hypertension acts as a silent killer for many years before the systemic target organ damage is clinically apparent. Hypertensive retinopathy serves as a marker for overt target organ damage. Hence, the diagnosis of hypertensive retinopathy helps in cardiovascular risk stratification. Early detection of hypertensive retinopathy and end-organ damage coupled with prompt management determines the cardiovascular prognosis to a greater extent.

The eyes are the only organs in the body where vascular changes can be observed in vivo. The retina serves as a window to study human circulation as the retinal arterioles share similar anatomical and physiological properties with cerebral and coronary microcirculation.<sup>3</sup> Poorly controlled systemic hypertension causes damage to the retinal microcirculation. Retinal vascular examination using direct ophthalmoscopy can be used to determine the extent of hypertensive vascular changes.<sup>7</sup> Using non-invasive procedures such as non-mydratic fundus imaging are widely accepted in the general population and may serve as an ideal tool for population-based screening procedures. The non-mydratic fundus imaging using a portable fundus camera brings hypertensive retinopathy screening procedure to the doorsteps of the individuals and thereby has the following advantages; (i) reduce the travel cost, (ii) has wide acceptance and increased participation (iii) cost-effective. The population-based screening procedures enables to screen larger population with no apparent clinical manifestation who often tend to be missed out during hospital-based screening procedures. Hence, this study was designed with an objective to screen for hypertensive retinopathy among the known diabetic patients using a portable non-mydratic fundus camera as a community-based screening procedure and estimate its prevalence.

## 2. Materials and Methods

### 2.1. Data collection method

A community-based cross-sectional study was conducted in three selected field practice areas of the Department of Community Medicine of a tertiary care teaching hospital in \*\* between December 2018 and January 2020. The known participants were identified by reviewing Non-Communicable Disease (NCD) registers, community-based health information and management system records, and family folders. A house-to-house survey was conducted among 302 known diabetic individuals. All the participants were briefed about the study procedure. The participants were interviewed using a predesigned and pretested questionnaire, and information regarding their demographic profile, and treatment history, etc., were obtained. The study participants were subjected to clinical examination, and blood pressure was recorded. The visual acuity examination was performed using Snellen's chart. A comprehensive ocular examination and retinal fundus examination using a portable handheld Bosch Mobile Eye Care Solutions fundus camera [Model Number: 311600460910] without pupillary dilation (non-mydratic mode). A minimum of 2 sets of images was captured for each participant in each eye. The images were transferred to a laptop via Bosch external connector and were grouped into patient-specific folders. The fundus images were reviewed and reported by an experienced Ophthalmologist from the same hospital. Hypertensive retinopathy was graded based on Keith, Wagener, and Barker hypertensive retinopathy classification.<sup>8</sup>

**Table 1:** Grading of hypertensive retinopathy using Keith, Wagener, and Barker classification

Grade	Classification	Symptoms
Grade I	Mild generalised retinal arteriolar narrowing and sclerosis	No symptoms
Grade II	Definite focal narrowing and arteriovenous crossing. Moderate to marked sclerosis of the retinal arterioles. Exaggerated arterial light reflex	Asymptomatic
Grade III	Retinal haemorrhages, exudates and cotton wool spots. Sclerosis and spastic lesion of retinal arterioles.	Symptomatic
Grade IV	Severe grade III and papilledema	Reduced survival

### 2.2. Geographical information system

Geographical Information System (GIS) is a system used to capture, store, integrate, analyze and display data that are spatially referenced to the earth. The system is gaining

importance lately due to its ability to analyze data spatially and plot them graphically into maps. It serves as a decision-making tool in health care and guides the formulation of health sector policies and programs.<sup>9</sup> GIS mapping of diseases helps identify areas of risk and enables decision-making in order to serve the priority areas.<sup>10</sup> Hence, during the household survey, the geographical coordinates of the location of the study participants were marked using the mobile phone-based application Epicollect5. These geo-coordinates were uploaded in the GIS software ArcGIS software version 10.4 developed by Environmental Systems Research Institute, Redlands, California, and the region-specific prevalence map was developed.

### 2.3. Statistical analysis

The data was entered in EpiData software version 3.1 developed by EpiData Association, Denmark. The data was exported and analyzed using Statistical Package for Social Sciences (SPSS) software version 21 developed by IBM PASW Statistics, New York, U.S. The outcome variable was classified based on the findings of non-mydratric fundus images. The categorical variables were expressed as percentage/proportion. The continuous variables were reported as mean and standard deviation and, while median with interquartile range (IQR) was commuted for data with skewed distribution. The 95% confidence interval range for the categorical variable was calculated using SPSS software version 21.

### 2.4. Ethical clearance

The study was commenced after obtaining approval from the Institutional Ethics Committee [IEC NO: RC/18/68]. All the study participants were briefed about the study procedure and informed written consent was obtained.

## 3. Results

About 302 known diabetic participants were screened for hypertensive retinopathy using a portable non-mydratric Bosch Mobile Eye Care Solutions fundus camera. The demographic characteristics of the study participants are shown in Table 2.

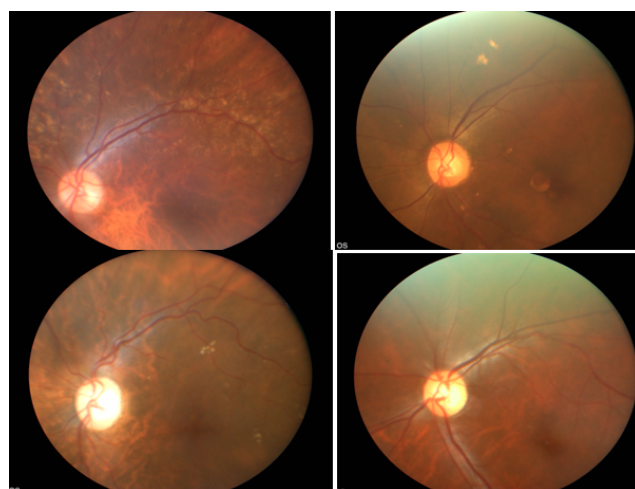
The mean age of participants was 53.5 years (SD  $\pm$  9.65). Most of the study participants were females, 190 (62.9%). About 123 (40.7%) of the participants had no formal school education. Around 137 (45.4%) known diabetic participants had a history of hypertension, and about 26 (8.6%) had coexisting cardiovascular diseases.

Out of the 302 diabetics studied, 60 (19.9%, 95% CI: 15.7% - 24.6%) were found to have some degree of hypertensive retinopathy as indicated by the presence of arteriolar attenuation and arteriovenous changes in the fundus photographs. Out of 60 participants diagnosed with hypertensive retinopathy, 35 (58.3%) were females, and 25

(41.6%) were males. Table 2

The participants diagnosed with hypertensive retinopathy were graded using Keith-Wagner-Barker classification (Table 3). About 91.2% and 91.7% were diagnosed with grade I hypertensive retinopathy in the right and left eye. About 7 % and 6.7% were diagnosed with grade II hypertensive retinopathy in the right eye and left eye, respectively. Only one participant was diagnosed with grade III hypertensive retinopathy in both eyes.

In this study, Geographical Information System was used to map the locations of hypertensive retinopathy patients using ArcGIS software and the region-specific prevalence maps were developed (Figure 2). The prevalence of hypertensive retinopathy was found to be slightly higher in Tamil Nadu (21.8%; 95% CI: 16% - 28.6%) as compared to that of Puducherry (17.5%; 95% CI: 11.8% - 24.6%). Table 3



**Fig. 1:** Non-mydratric fundus images showing features suggestive of hypertensive retinopathy.

The fundus images (Figure 1A-AD) depict the features suggestive of hypertensive retinopathy as indicated by arteriovenous changes in the fundus photographs including the presence of arteriolar attenuation, arteriolar thinning, AV nicking, exudates and cotton wool spots.

## 4. Discussion

Non-communicable diseases have emerged as a global public health crisis and a leading cause of premature mortality. Hypertension and diabetes mellitus being vascular risk factors increase the risk of both cardiovascular and cerebrovascular events. Uncontrolled hypertension damages the retinal vasculature resulting in hypertensive retinopathy. Hence active screening of hypertensive retinopathy helps in early detection and cardiovascular risk stratification. The diagnosis of hypertensive retinopathy is based on findings seen on fundoscopic examination, usually under adequate mydriasis in an outpatient department which is time-consuming and hence frustrates large-scale

**Table 2:** Demographic characteristics of the study population (n=302)

Variable	Hypertensive retinopathy				Total (n=302)
	Present (n=60)		Absent (n=242)		
	N	%	N	%	
Mean Age	53.53 years		61.64 years		53.5
<b>Gender</b>					
Male	25	22.3	87	77.7	112
Female	35	18.4	155	81.6	190
<b>Education</b>					
No formal schooling	23	18.7	100	81.3	123
Primary school	10	31.3	22	68.8	32
Middle school	16	18.2	72	81.8	88
High school	11	22.9	37	77.1	48
Graduate	0	0	11	100	11
<b>History of hypertension</b>					
Present	47	34.3	90	65.7	137
Absent	13	7.9	152	92.1	165
<b>History of cardiovascular disease</b>					
Present	11	42.3	15	57.7	26
Absent	49	12.8	227	82.2	276

**Table 3:** Distribution of the hypertensive retinopathy patients based on its severity (n=60).

S.No.	Hypertensive retinopathy classification	Right Eye		Left Eye	
		Frequency (n)	Percentage (%)	Frequency (n)	Percentage (%)
1	Grade I	52	91.2	55	91.7
2	Grade II	4	7.0	4	6.7
3	Grade III	1	1.8	1	1.6
Total		57	100	60	100

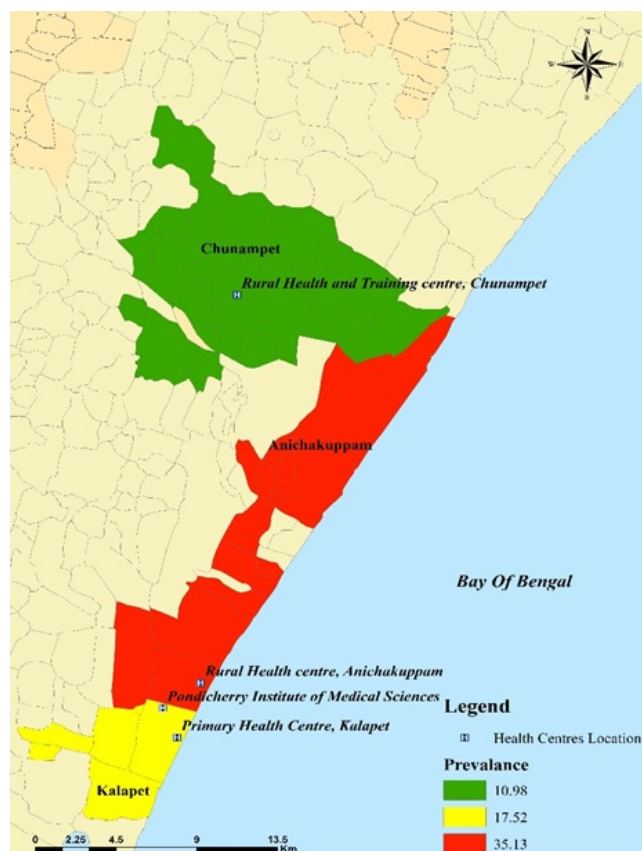
screening. On the other hand, the non-mydratic fundus camera is a portable device that can be used in a house-to-house survey without dilating the pupils and hence requires less amount of patient time. This offers a clear advantage for screening efforts. This study was undertaken to determine the prevalence of hypertensive retinopathy in known diabetics using the portable non-mydratic Bosch Mobile Eye Care solutions fundus camera in a community-based setting saved time as pupils are not dilated and so can be used as an effective tool for screening in the house-to-house survey or in a rural clinic. Other modalities of fundus examination require mydriasis and costly equipment in an outpatient department. Spectral-domain and swept-source optical coherence tomography, SD-OCT and SS-OCT, respectively, are newer modalities of imaging that can demonstrate thinning of the retina, pigment epithelium detachment, serous retinal detachment, and areas of choroidal non-perfusion.<sup>11</sup>

The mean age of the study participants in the present study was 53.5 years (SD  $\pm$  9.65). Similar findings were reported by a study by Mondal et al., which reported a mean age of 51.8 years.<sup>12</sup> The prevalence of hypertensive retinopathy increases with age likely findings were suggested by Yu T, et al. study that retinopathy is correlated with increased age and the severity of hypertension.<sup>13</sup>

In the present study, most of the study participants were female (190), which is similar to the study done by Besharati MR et al. among 213 hypertensive patients in Yazd, Iran.<sup>14</sup>

Yet the prevalence of hypertensive retinopathy was high among males as compared to that of females and these findings are in line with the study done in Bangladesh by Mondal RN et al. which showed an increased prevalence in males than females (64.1% vs. 35.9%) (P value- 0.006).<sup>12</sup> Similar findings were observed in a study in Maharashtra by Priyadarshini et al. The study observed that hypertensive retinopathy occurs more among males with a male: female ratio of 1.7:1.<sup>15</sup>

In the present study, 137(45.4%) known diabetic participants had a history of hypertension. Thirteen (21.6%) participants diagnosed with hypertensive retinopathy did not have a history of hypertension and were not aware of their disease status. Hypertension is commonly known as a silent killer disease because of the fact that it tends to be asymptomatic in most patients for several years causing serious damage to the organ system.<sup>16</sup> Generalised and focal retinal arteriolar narrowing has been shown to predict the risk of hypertension in normotensive people.<sup>17</sup> This fact highlights the silent nature of the disease and the need for regular population-based screening and helps in risk prediction. Eleven (42.3%) of the known diabetic individuals with coexisting cardiovascular diseases were



**Fig. 2:** Geographical map depicting the area-wise prevalence of hypertensive retinopathy.

The location of the hypertensive retinopathy patients mapped using Epicollect 5 were imported into Arc GIS software and were developed in prevalence maps to depict the region-specific prevalence. The prevalence was found to be slightly higher in \*\* (21.8% 95% CI: 16% - 28.6%) when compared to \*\* (17.5%; 95% CI: 11.8% - 24.6%).

diagnosed with hypertensive retinopathy. The cohort study by Jibrán et al. reported hypertensive retinopathy as an independent risk factor for post-acute STEMI in people with pre-existing cardiovascular disease and also associated with an increased relative risk of complication by 3.17 times.<sup>18</sup>

Among the 302 known diabetics screened, about 60 [19.9% (95% CI: 15.7% - 24.6%)] were diagnosed to have some degree hypertensive retinopathy as indicated by the presence of arteriolar attenuation and arteriovenous changes in the fundus photographs. The study conducted by Salaria NS et al. in a tertiary care hospital at Mathura observed a similar prevalence of 28.1%.<sup>19</sup> Yet few studies suggest a very high prevalence of hypertensive retinopathy ranging from 29% to 70%. The study by Ray S et al. observed a prevalence of 62.25%.<sup>20</sup> These findings suggest that hypertensive retinopathy predominately remains to be disease following the iceberg phenomenon and emphasis the

need for screening.

The severity of hypertensive retinopathy is significant in cardiovascular risk stratification. Grade III and IV hypertensive retinopathy are associated with poor prognosis and decreased survival. Several grading systems were used in grading hypertensive retinopathy. Keith, Wagner, Barker came up with the first classification based on arteriovenous changes, haemorrhages, exudate, and disc edema.<sup>8</sup> Wong and Michel simplified the grading into mild indicated by arteriovenous changes, moderate by retinal haemorrhages, cotton wool spots, and hard exudates and severe by moderate retinopathy plus optic disc swelling.<sup>21</sup> Hypertensive choroidopathy is marked by Elschnig's spots, lesions appearing as black spots surrounded by yellow or red halos at retinal pigment epithelium (RPE) level due to non-perfusion of the overlying choriocapillaris and resultant focal ischemic damage to RPE, whereas Siegrist streaks are linear hyperpigmented streak along choroidal arteries due to ischemia. Choroidal dysfunction can affect the pumping mechanism of retinal pigment epithelium which can lead to serous retinal detachments.<sup>22</sup> The significance of hypertensive retinopathy lies in the fact that signs of mild hypertensive retinopathy are associated with coronary artery disease, stroke and renal dysfunction.<sup>23–25</sup> In the Ibaraki Prefectural Health Study, mild hypertensive retinopathy was found to be a risk factor for cardiovascular mortality independent of cardiovascular risk factors. Signs of moderate hypertensive retinopathy were even more strongly associated with two- to four-times higher risk of death from cardiovascular causes. Hypertensive chorioretinopathy is a feature more commonly associated with younger patients. It is seen in conditions like malignant hypertension, pre-eclampsia, acute or chronic renal failure, renal artery stenosis, and adrenal carcinoma. These conditions require immediate medical treatment.<sup>26</sup> In the present study, 52(91.2%) and 55(91.7%) participants were diagnosed with grade I hypertensive retinopathy in the right and left eye. About 4(7 %) and 4(6.7%) were diagnosed with grade II hypertensive retinopathy in the right eye and left eye, respectively. Only one participant was diagnosed with grade III hypertensive retinopathy in both eyes. Similar findings were observed done in Ghana among civil servants where the prevalence of mild grades of hypertensive retinopathy was as high as 69.4%.<sup>27</sup>

In this study, Geographical information system was used to map the locations of hypertensive retinopathy patients. The use of GIS in healthcare has helped in identifying high prevalence areas that require action on a priority basis as well as in planning and decision-making. The prevalence was found to be slightly higher in Tamil Nadu (21.8%; 95% CI: 16% - 28.6%) as compared to that of Puducherry (17.5%; 95% CI: 11.8% - 24.6%). The prevalence map suggested a difference in area-wise distribution of hypertensive retinopathy. The study found a



prevalence of hypertensive retinopathy in different areas as follows: 35.13% in \*\* area, 17.52% in \*\* area and 10.98% in \*\* area. The first two areas with higher prevalence require more attention in healthcare planning and also to ascertain the various causes that could be behind this finding. GIS technology can also be utilised in mapping the behavioural risk factors contributing to non-communicable diseases and also identify clustering of patients with high risk factors.<sup>28</sup>

## 5. Conclusion

The coexistence of systemic hypertension not only exacerbates diabetic retinopathy, which is potentially a blinding condition, but also is an independent risk factor for coronary artery disease, cerebrovascular disease, renal dysfunction and other potentially blinding conditions like central retinal and vein occlusions, branch retinal vein occlusion, non-arteritic ischemic optic neuropathy, glaucoma, age-related macular degeneration and suprachoroidal haemorrhage during ophthalmic surgeries.<sup>6</sup> This fact highlights the need for better screening measures which will pick out those who are at risk without an elaborate health check-up which can defeat screening efforts. To this end, the incorporation of portable non-mydratric camera can go a long way. The GIS helps in identifying high prevalence areas so that appropriate preventive measures can be directed where needed. Early detection of hypertensive retinopathy and prompt treatment will help in reducing the morbidity and premature mortality due to hypertension to a greater extent and is a way forward to achieving Sustainable Developmental Goal.

## 6. Source of Funding

None.

## 7. Conflict of Interest

The authors declare that there are no potential conflicts of interest for the authorship and publication of the article.

## References

- World Health Organization (WHO). Hypertension [Internet]. World Health Organization; 2021. Available from: <https://www.who.int/news-room/fact-sheets/detail/hypertension>.
- The World Health Organization. A global brief on hypertension: silent killer, global public health crisis; 2013. Available from: [http://apps.who.int/iris/bitstream/10665/79059/1/WHO\\_DCO\\_WHD\\_2013.2\\_eng.pdf](http://apps.who.int/iris/bitstream/10665/79059/1/WHO_DCO_WHD_2013.2_eng.pdf).
- Prakash D. Target organ damage in newly detected hypertensive patients. *J Family Med Prim Care*. 2019;8(6):2042–6. doi:10.4103/jfmpc.jfmpc\_231\_19.
- Lago RM, Singh PP, Nesto RW. Diabetes and hypertension. *Nat Clin Pract Endocrinol Metab*. 2007;3(10):667. doi:10.1038/ncpendmet0638.
- Grosso A, Veglio F, Porta M, Grignolo FM, Wong TY. Hypertensive retinopathy revisited: some answers, more questions. *Br J Ophthalmol*. 2005;89(12):1646–54. doi:10.1136/bjo.2005.072546.
- Wong TY, Mitchell P. The eye in hypertension. *Lancet*. 2007;369(9559):425–35. doi:10.1016/S0140-6736(07)60198-6.
- Suri MFK, Qureshi AI. Hypertensive retinopathy and risk of cardiovascular diseases in a national cohort. *J Vasc Interv Neurol*. 2008;1(3):75–8.
- Keith NM, Wagener HP, Barker NW. Some different types of essential hypertension: their course and prognosis. *Am J Med Sci*. 1939;197:332–43. doi:10.1097/00000441-193903000-00006.
- Evangelos CF, Papatheanasiou IV, Mitsi D, Tsaras K, Kleisiaris CF, Kourkouta L, et al. Health based geographic information systems (GIS) and their applications. *Acta Inform Med*. 2014;22(6):402–5.
- Kumar A, Grover A. Understanding the problem of diabetes in India using geographical information system software. *Indian J Endocrinol Metab*. 2014;18(1):124–5.
- Velazquez-Villoria D, Rodrigo PM, DeNicola ML, Vitori MAZ, García AS, García-Arumí J, et al. Swept source optical coherence tomography evaluation of chorioretinal changes in hypertensive choroidopathy related to HELLP syndrome. *Retin Cases Brief Rep*. 2019;13(1):30–3. doi:10.1097/ICB.0000000000000524.
- Mondal RN, Matin MA, Rani M, Hossain MZ, Saha AC, Singh RB, et al. Prevalence and Risk Factors of Hypertensive Retinopathy in Hypertensive Patients. *J Hypertens*. 2017;6(2):241. doi:10.4172/2167-1095.1000241.
- Mitchell P, Berry G, Li W, Wang JJ. Retinopathy in older persons without diabetes and its relationship to hypertension. *Arch Ophthalmol*. 1998;116(1):83–9. doi:10.1001/archoph.116.1.83.
- Besharati MR, Rastegar A, Shoja MR, Maybodi ME. Prevalence of retinopathy in hypertensive patients. *Saudi Med J*. 2006;27(11):1725–8.
- Cholera P, Pendse M. A study of prevalence of hypertensive retinopathy at tertiary health care center. *MedPulse Int J Med*. 2020;13(3):118–21.
- World Health Organization A global brief on hypertension: Silent killer, global public health crisis: World Health Day 2013. WHO: Geneva. 2013. Last accessed July 27, 2019 ; 2013. Available from: <https://apps.who.int/iris/handle/10665/79059>.
- Smith W, Wang JJ, Wong TY, Rochtchina E, Klein R, Leeder SR, et al. Retinal arteriolar narrowing is associated with 5-year incident severe hypertension: the Blue Mountains Eye Study. *Hypertensio*. 2004;44(4):442–7. doi:10.1161/01.HYP.0000140772.40322.ec.
- Jibrán MS, Habib SA, Khan SB. Hypertensive Retinopathy: A Prognostic Factor for Morbidity and Mortality after Acute ST Elevation Myocardial Infarction. *J Coll Physicians Surg Pak*. 2019;29(3):205–9.
- Salaria NS, Phuritshabam C. Assessment of Prevalence and Risk Factors of Hypertensive Retinopathy - A Clinical Study. *Int Arch BioMed Clin Res*. 2019;5(4):OP1–4.
- Ray S, Sahu BK, Naskar S. Hypertensive retinal changes: It's prevalence and associations with other target organ damage. *Indian J Med Sci*. 2020;72(3):195–200.
- Wong TY, Mitchell P. Hypertensive retinopathy. *N Engl J Med*. 2004;351(22):2310–7. doi:10.1056/NEJMra032865.
- Tso MO, Jampol LM. Pathophysiology of hypertensive retinopathy. *Ophthalmology*. 1982;89(10):1132–45. doi:10.1016/s0161-6420(82)34663-1.
- Duncan BB, Wong TY, Tyroler HA, Davis CE, Fuchs FD. Hypertensive retinopathy and incident coronary heart disease in high risk men. *Br J Ophthalmol*. 2002;86(9):1002–6. doi:10.1136/bjo.86.9.1002.
- Ong YT, Wong TY, Klein R, Klein BEK, Mitchell P, Sharrett AR, et al. Hypertensive retinopathy and risk of stroke. *Hypertension*. 2013;62(4):706–11. doi:10.1161/HYPERTENSIONAHA.113.01414.
- Wong TY, Coresh J, Klein R, Muntner P, Couper DJ, Sharrett AR, et al. Retinal microvascular abnormalities and renal dysfunction: the atherosclerosis risk in communities study. *J Am Soc Nephrol*. 2004;15(9):2467–76. doi:10.1097/01.ASN.0000136133.28194.E4.
- Tsukikawa M, Stacey AW. A Review of Hypertensive Retinopathy and Chorioretinopathy. *Clin Optom (Auckl)*. 2020;12:67–73. doi:10.2147/OPTO.S183492.

27. Addo J, Smeeth L, Leon DA. Hypertensive target organ damage in Ghanaian civil servants with hypertension. *PLoS One*. 2009;4(8):6672. doi:10.1371/journal.pone.0006672.
28. Silva JP. Mapping Unhealthy Behavior Among Economically Active Men Using GIS in Suburban and Rural Areas of Sri Lanka. *Asia Pac J Public Health*. 2016;28(1):10–6.

**Newtonraj Ariarathinam**, Associate Professor

**Murugan Natesan**, Professor

**Joy Bazroy**, Professor

**Anil Jacob Purty**, Professor and Head

### Author biography

**Saranya Rajaram**, Senior Resident

**Amod Hansdak**, Associate Professor

**Cite this article:** Rajaram S, Hansdak A, Ariarathinam N, Natesan M, Bazroy J, Purty AJ. Prevalence of hypertensive retinopathy among the known diabetics in a community-based setting using a non-mydratic fundus camera. *Panacea J Med Sci* 2022;12(3):569-575.