

Radiology of Corrosive Poisoning: Report of Three Cases

Tyagi Sagar^{1,*}, Hans Parveen², Kumar Hemant³, Mohan Virinder⁴

^{1,2,3}Junior Resident, ⁴Professor Emeritus, Dept. of Radiodiagnosis,
Rohilkhand Medical College and Hospital, Bareilly, U.P (243001), India.

***Corresponding Author**

E-mail: sagartgi@gmail.com

Abstract

Ingestion of corrosive substances can produce severe injury to the gastrointestinal tract and can even result in death. The degree of damage depends on the type of the substance, morphologic form of the agent, and the quantity ingested. Long term complications include stricture formation, antral stenosis, gastric ulcers and the development of esophageal carcinoma. Three cases of corrosive poisoning diagnosed on the basis of barium studies and subsequent correlation with history of accidental corrosive intake in two and suicidal intake in one case are reported in this communication. The literature on the subject is scanty and hence the report.

Keywords: Barium study, Corrosive poisoning, Radiology.

Introduction

Corrosives are a group of chemicals that cause tissue injury on contact. They most commonly affect the gastro intestinal tract, respiratory system and the eyes. Corrosive ingestion has devastating effects on the upper gastrointestinal tract and present major problems in management.

Ingestion of corrosives either accidentally by children (80%) and alcoholics or intentionally for the purpose of suicide is a common form of poisoning in India (1-2). Acids and alkalis are the two primary types of agents responsible for caustic exposures. Upon ingestion alkalis primarily damage the oropharynx and esophagus whereas acids usually involve the distal part of esophagus and stomach. The acid pools in the antrum causing gastric outlet obstruction secondary to cicatricialantral stenosis⁽³⁾.

Case History 1

A 22-year-old male presented to the ENT department of our hospital with a history of accidental ingestion of acid 10 months back. He gave history of ingestion of mustard oil and water soon after. History of vomiting was present with difficulty in swallowing. His vital signs were normal. Patient was afebrile. Routine laboratory investigations were normal. On clinical examination the posterior pharyngeal wall was congested with a whitish patch on the tonsillar pillars. Abdominal examination revealed tenderness and guarding. He was referred to the radiology department for a barium swallow examination.

The barium swallow study revealed smooth narrowing of the lower half of the thoracic esophagus with minimal dilatation of the proximal segment. Visualized portion of stomach revealed complete effacement of gastric rugae (Fig. 1).

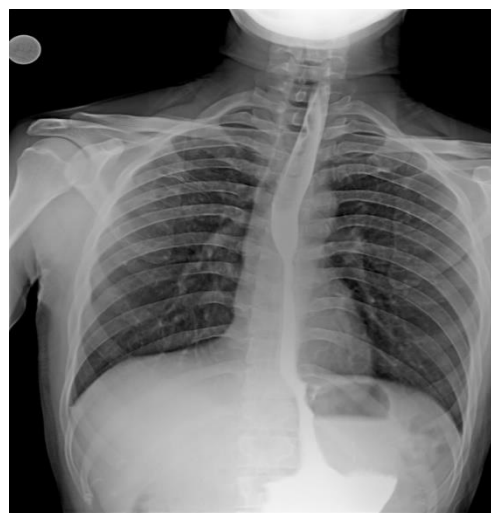

Fig. 1: Barium Swallow examination of Case 1

The study was then extended to evaluate stomach and duodenum which revealed reduced capacity of stomach with absent peristalsis and smooth contour of stomach wall (Fig. 2).

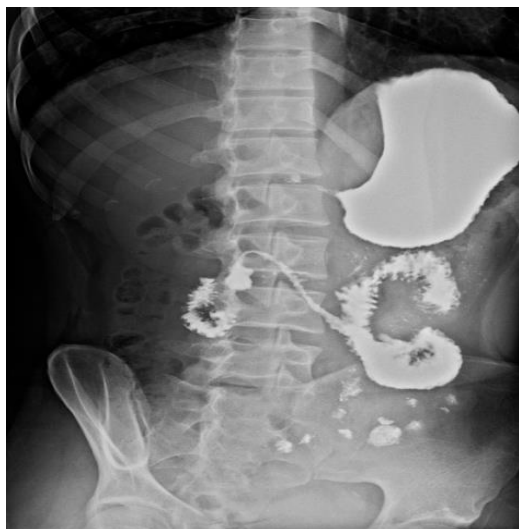

Fig. 2: Small sized stomach with smooth contours, loss of peristalsis and antral narrowing

Evidence of gross narrowing of pylorus of stomach with delayed passage of barium through the duodenum was noted (Fig. 3). Thus the diagnosis of benign stricture of the esophagus and corrosive stricture of antrum of stomach with linitis plastica type appearance of stomach due to corrosive poisoning was made.

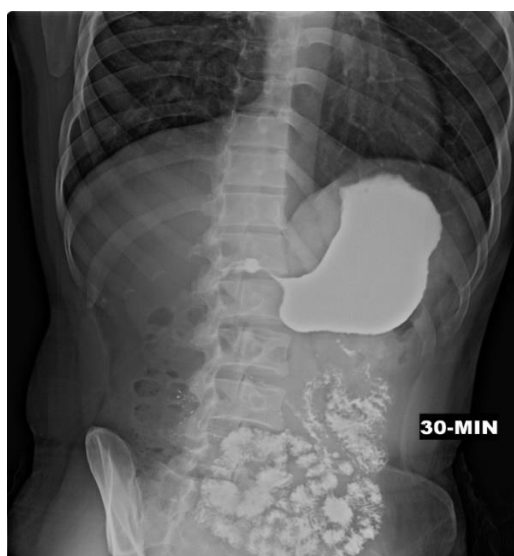

Fig. 3: Gross antral and pyloric narrowing and delayed passage of the barium contrast

Case History 2

A 35-year-old male presented in the surgical services of our hospital with the complaints of dysphagia and occasional vomiting since last 4 months and was referred to the radiology department for a Barium Swallow examination with the provisional diagnosis of achalasia cardia.

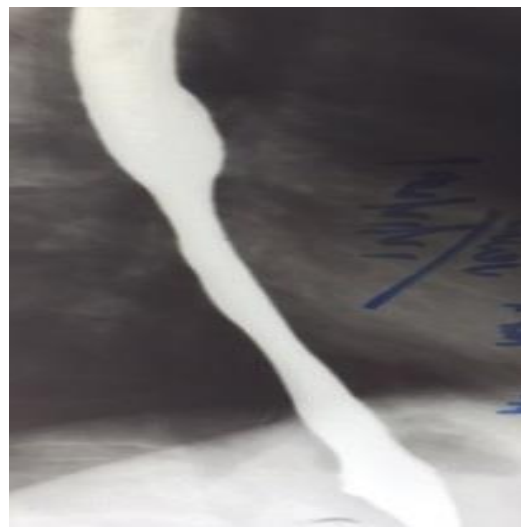


Fig. 4: Barium Swallow examination of Case 2

The barium swallow examination revealed smooth narrowing of lower third of the esophagus with minimal dilatation of the upper third (Fig. 4). No peristalsis was noted in the esophagus and there was no obstruction to the passage of the contrast in to the stomach. The study was extended to evaluate the stomach and duodenum, which revealed a small sized, contracted, aperistaltic stomach with presence of multiple ulcers at the greater curvature and gross narrowing at the gastric pylorus and antrum (Fig. 5 and Fig. 6).



Fig. 5: Continuous filling of the esophagus and stomach suggesting involvement of the gastric esophageal junction

The gastro-esophageal junction was patulous. The gastric emptying time was markedly delayed with a small trickle of the contrast identified with great difficulty. The patient was asked about the history of any corrosive intake which he denied initially but admitted having ingested acid accidentally about 7 months back.

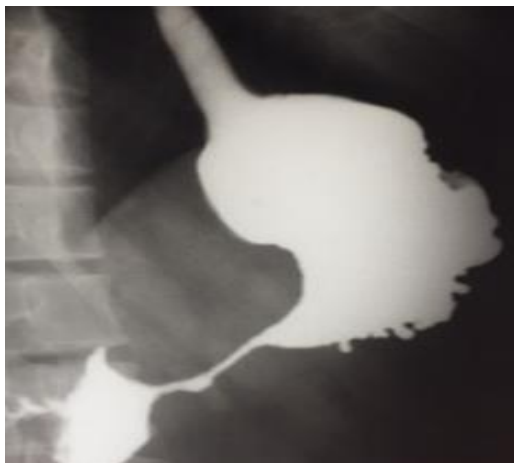


Fig. 6: Delayed film with same findings

Case History 3

A 26-year-old female presented with vomiting, loss of weight and pain in the abdomen for last one year. Clinical examination revealed an emaciated and anaemic patient. Local examination was unremarkable. She was referred to the radiology department with a provisional diagnosis of gastric malignancy with a request for barium meal study for evaluation.

The study revealed normal passage of barium through the esophagus with no narrowing or filling defects. The stomach was however, reduced in size with no peristalsis. The gastric mucosa was completely effaced with narrowing and ulceration at the antrum (Fig. 7).

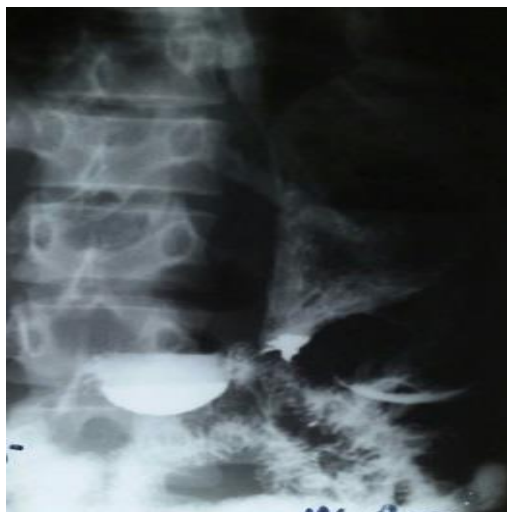

Fig. 7: Barium Meal examination of Case 3

The gastric emptying time was delayed. The barium meal findings were highly suggestive of corrosive poisoning. Upon questioning, the patient agreed that she had drunk acid one and half years in a suicide attempt.

Discussion

Ingestion of corrosive substances, either accidentally or intentionally for suicide, is a common form of poisoning⁽¹⁻²⁾. Both acid and alkali cause fibrosis and cicatrization. The nature of injury depends on the nature of corrosive agent consumed (acid or alkali), its physical state, amount, concentration of the agent consumed and the duration of contact with the mucosa⁽⁴⁾.

As acid intake accounts for only 5% of all reported cases, the knowledge about the radiological spectrum of injuries to upper gastrointestinal tract due to corrosive acidic substance is scanty. Robert⁽⁵⁾ reported the first case of corrosive induced pyloric stenosis while Ciftci et al⁽⁶⁾ reported gastric outlet obstruction in 5% cases of acid ingestion.

Acid induces coagulation necrosis with eschar formation which may limit tissue penetration. Late sequelae include stricture formation and gastric outlet obstruction. Stricture formation may become symptomatic within 3 months or may even manifest a year later. Symptoms of early satiety and weight loss may suggest gastric outlet obstruction. This however, tends to occur less frequently than stricture formation, with an incidence of 4 cases out of 214 in one study⁽⁷⁾.

Few earlier studies have suggested that acid cause maximal damage to stomach and minimal damage to the esophagus because of relative resistance of squamous epithelium to acids, rapid transit through the esophagus due to low viscosity and less specific gravity, reservoir function of stomach allowing large volume of acids, and reflex pylorospasm increasing the contact time between the acid and the stomach mucosa⁽⁸⁻⁹⁾. We tend to agree with this observation as all our patients had swallowed acid and were found to have evidence of gastric outlet obstruction and ulcer formation. Zargar et al⁽¹⁾ reported 41 cases were esophageal injury was seen in 87.5% cases, gastric injury in 85.4% and duodenal injury in 34.1% cases. They concluded that acid injury of UGI tract is a serious condition that effects esophagus and stomach equally and results in high mortality and morbidity. Isolated stomach injury although rare has been reported as a diffuse injury, which results following ingestion on an empty stomach.

Similarly gastric injury is believed to be less common with alkalis as they are neutralized by the acidic contents; however one study reported evidence of gastric injury in 93% of patients with alkali ingestion⁽²⁾.

After a latent period of 4-6 weeks patients present with persistent vomiting, early satiety, and post prandial fullness⁽¹⁰⁻¹¹⁾. Vomiting, loss of weight and decreased oral intake remains the most noticeable features. Retractive phase is characterized by progressive fibrosis which gives rise to symptoms of esophageal and gastric outlet obstruction. Obstructive symptoms usually

appear within 2-3 weeks of corrosive ingestion but may sometimes be delayed for many months.

Grossly the stomach appears to be firm, contracted, and nodular. The lumen may be completely obliterated. In most of the cases, the only change is scarring of the pyloric antrum or the pyloric ring with surrounding adhesions.

The diagnosis is easy in those cases where history of corrosive ingestion is available. Upper GI contrast studies remain a useful diagnostic tool in patients with associated esophageal stricture. Later changes include blurring of mucosa, intramural pseudo diverticulosis, deep linear ulcers with intramural dissection, retention and pocketing of contrast and intramural gas collection. The stomach may show evidence of ulceration, bullae and pseudopolyps⁽¹⁻²⁾.

Late complications include esophageal stricture, gastric cicatrization and cancer of the esophagus. Corrosive injury most often causes pyloric or antral stenosis though shortening and irregularity of lesser curvature and hour glass deformity of stomach may also occur. Gastric outlet obstruction due to antral or pyloric stenosis is less common as compared to esophageal stricture.

Early surgical intervention remains the treatment of choice with the aim to restore normal passage for food from stomach to small intestine. Partial gastrectomy with Billroth type I reconstruction remains the procedure of choice in patients with complete luminal obstruction.

Conclusion

Three cases of corrosive ingestion resulting in advanced changes in stomach are reported. All cases referred for barium swallow examination, showing normal esophagus or benign stricture formation should have barium meal examination done to know about the status of stomach and duodenum. Moreover in all cases of dysphagia/vomiting in young patients, it should be mandatory to extend the barium swallow examination to barium meal studies so that the cases of stomach injury are not missed, increasing the morbidity and mortality. Also it is a simple OPD procedure that is also cost effective.

Conflict of Interest: None

Source of Support: Nil

References

1. Zargar SA, Kochhar R, Nagi B, Mehta S, Mehta SK. Ingestion of corrosive acids: Spectrum of injury to upper gastrointestinal tract and natural history. *Gastroenterology* 1989;97:702-7.
2. Zargar SA, Kochhar R, Nagi B, Mehta S, Mehta SK. Ingestion of strong corrosive alkalis: Spectrum of injury to upper gastrointestinal tract and natural history. *Am J Gastroenterol* 1992;87:337-41.
3. Sharma S, Debnath PR, Agrawal LD, Gupta V. Gastric outlet obstruction without esophageal involvement: A late

- sequelae of acid ingestion in children. *J Indian Assoc Pediatr Surg* 2007;12:47-9.
4. Lahoti D, Broov S. Corrosive injury to upper GIT. *Ind Journ Gastroenterol* 1993;12:135-41.
5. Howard KG, Holmes CL. Pyloric stenosis caused by ingestion of corrosive substances: Report of case. *Surg Clin North Am* 1948;28:1041-56.
6. Ciftci AO, Senocak ME, Buyukpamukcu N, Hicsonmez A. Gastric outlet obstruction due to corrosive ingestion: Incidence and outcome. *Pediatr Surg Int* 1999;15:88-91.
7. Ramasamy K, Gumaste VV. Corrosive ingestion in adults. *J Clin Gastroenterol* 2003;37(2):119-24.
8. Dilwari JB, Singh S, Rao PN. Corrosive acid ingestion in man – clinical and endoscopic study. *Gut* 1984;25:183-7.
9. Chodak GW, Passaro E jr. Acid ingestion: Need for gastric resection. *JAMA* 1978;230:225-6.
10. Howard KG, Holmes CL. Pyloric stenosis caused by ingestion of corrosive substances: Report of case. *Surg Clin North Am* 1948;28:1041-56.
11. Zamir O, Hod G, Lemau OZ, Mogle P, Nissan S. Corrosive injury to the stomach due to acid ingestion. *Am Surg* 1985;51:170-2.