



## Original Research Article

# Visual outcome and prognosis following SFIOL implantation by Dr. Shin Yamane's double needle based haptic exteriorization with transconjunctival flanging of haptic tips technique

Dheerendra Singh<sup>1\*</sup>, Ganesh Pillay<sup>1</sup><sup>1</sup>ASG Eye Hospital, Bhopal, Madhya Pradesh, India

## ARTICLE INFO

## Article history:

Received 23-10-2022

Accepted 06-12-2022

Available online 13-08-2024

## Keywords:

Yamane's technique

SFIOL Implantation Technique

Suture less SFIOL Implantation

## ABSTRACT

**Aim:** To study the visual outcome and prognosis in patients after Scleral Fixated Intraocular Lens (SFIOL) implantation by Yamane's technique at a tertiary hospital in Madhya Pradesh.

**Materials and Methods:** A total of 20 eyes of 20 patients with aphakia or subluxated lens (postoperative or traumatic) reporting to our study area were included. Detailed clinical history, associated comorbidities were noted and patients were subjected to detailed ophthalmologic examination. After preoperative evaluation, SFIOL implantation using Yamane's technique was done and patients were followed up till 3 months.

**Results:** Mean age of patients was  $52.5 \pm 17.99$  years (range 20 – 78 years) and about 70% patients were males. Close globe injury followed by posterior capsular rent during phacoemulsification were the most common causes observed in 25% and 15% cases respectively leading to aphakia. About 65% patients presented with visual acuity of  $<1/60$  i.e., hand movement, counting finger or PLPR. Following SFIOL, visual acuity improved significantly i.e., 75% patients had visual acuity of 6/6 to 6/12 ( $p < 0.05$ ). No significant complication was noted in postoperative period.

**Conclusion:** Yamane's novel suture less, flapless and glue less technique of SFIOL implantation can be effectively utilized for management of aphakia and subluxation of lens due to various etiologies. Visual outcome in cases with aphakia and lens related causes of low visual acuity can be improved with SFIOL with avoidance of other suture and flap related complications as well.

This is an Open Access (OA) journal, and articles are distributed under the terms of the [Creative Commons Attribution 4.0 International License](https://creativecommons.org/licenses/by/4.0/), which allows others to remix, and build upon the work. The licensor cannot revoke these freedoms as long as you follow the license terms.

For reprints contact: [reprint@ipinnovative.com](mailto:reprint@ipinnovative.com)

## 1. Introduction

Lens is a transparent biconvex structure of eye which is suspended behind the iris and its sole function is to focus light rays onto the retina. Aphakia refers to absence of lens, which may be congenital or secondary to cataract surgery or trauma.<sup>1,2</sup> Patients of pseudophakia with lens dislocation or subluxation as well as traumatic lens subluxation are also responsible for poor visual outcome, in which vision may be restored following IOL implantation.

In cases with aphakia, optical rehabilitation is one of the important features, which poses a unique surgical challenge. In such cases, intraocular lens implantation is recommended, but the choice of IOL depends upon the patient condition, availability of IOL, affordability of the patient and expertise of ophthalmologist. Various types of IOL that can be used in patients with aphakia include anterior chamber IOL (ACIOL), iris fixated IOL, iris claw IOL, and sutured & suture less sclera-fixated IOL (SFIOL).<sup>2,3</sup>

Scleral fixated IOL (SFIOL) can be implanted using sutured as well as suture less techniques without capsular support.<sup>4</sup> Though, SFIOL has advantage i.e. it helps

\* Corresponding author.

E-mail address: [dheerendrasingh91@yahoo.in](mailto:dheerendrasingh91@yahoo.in) (D. Singh).

in achieving physiological position of lens but sutured SFIOL is a demanding technique and may presents with pseudophacodonesis and certain suture related complications such as suture breakage, knot exposure and IOL subluxation.<sup>5</sup> Thus, to avoid problems related with suture, suture less SFIOL was introduced as a new technique by Gabor et al in 2007. In this technique, posterior chamber IOL was fixed in sulcus and haptics were permanently incarcerated in a scleral tunnel. This method was helpful in achieving postoperative axial stability and provided closed-eye system.<sup>6</sup> Recently, in the year 2017, use of flanged intraocular lens fixation was suggested by Yamane et al. This technique involves externalization of the IOL haptics followed by cauterization so as to form mushroom-shaped or button-like tip at the end of each haptic. Then each haptic is threaded to a lumen of 30-gauge needle using intraocular forceps.<sup>7</sup> Following this, a low-temperature cautery is used for making the flange at the end of haptics, which in turn prevents prolapsing of haptics into the posterior chamber.<sup>8</sup>

### 1.1. Purpose

To study the visual outcome and prognosis in patients after Scleral Fixated Intraocular Lens (SFIOL) implantation by Yamane's technique at a tertiary hospital in Madhya Pradesh.

## 2. Materials and Methods

A total of 20 eyes of 20 patients with aphakia or subluxated lens (postoperative or traumatic) reporting to our study area were included. Detailed clinical history, associated comorbidities were noted and patients were subjected to detailed ophthalmologic examination. All the patients were subjected to detailed ophthalmologic examination preoperatively, their best corrected visual acuity was noted with the help of Snellen's chart. Anterior segment examination was done using slit lamp biomicroscope. Posterior segment examination was done with the help of direct and indirect ophthalmoscope. Corneal curvature in both vertical and horizontal diameters using automated keratometry. Intraocular pressure was measured using non-contact tonometry. IOL power calculation was done preoperatively. After preoperative evaluation, SFIOL implantation using Yamane's technique was done and patients were followed up till 3 months.

### 2.1. Operative procedure

The surgical technique was done under peribulbar anesthesia. Using Osher-Neumann corneal marker, peripheral cornea was marked at two points 180° apart. The port entries were made from each side using either a 23-G vitrectomy or 15° side port blade. A 6 mm corneoscleral tunnel was made which was self-sealing. A three-piece IOL was inserted through the sclerocorneal tunnel. With

the help of a standard 26-G needle (bent at 60° about 1mm from the hub), haptics were exteriorized using forceps. Two standard 26-G needles (13 mm) were bent to 60° about 1 mm from the hub. This bent needle was introduced into the ciliary sulcus and once it was visible within the pupillary margin, it was brought out through the corneoscleral tunnel. Haptic was threaded into the lumen of the needle using McPherson forceps and then other needle was inserted and the trailing haptic was exteriorized in a similar way as the leading haptic. The exteriorized haptics can be cauterized using heat cautery.

### 2.2. Follow up

Patients were followed up till 3 months and postoperative visual acuity was documented.

### 2.3. Statistical analysis

Data was compiled using MS Excel and analyzed using IBM SPSS software version 20. Categorical variables were expressed as frequency and proportion. Visual acuity before and after the surgery was compared using chi square test. P value < 0.05 was considered statistically significant.

## 3. Results

The present study was conducted on 20 eyes of 20 patients with mean age of 52.5±17.99 years (range 20 – 78 years).

Majority of patients belonged to more than 30 years of age (80%) and about 70% patients were males. Right and left eye were equally affected by aphakia.(Table 1)

Close globe injury followed by posterior capsular rent during phacoemulsification were the most common causes observed in 25% and 15% cases respectively.(Table 2)

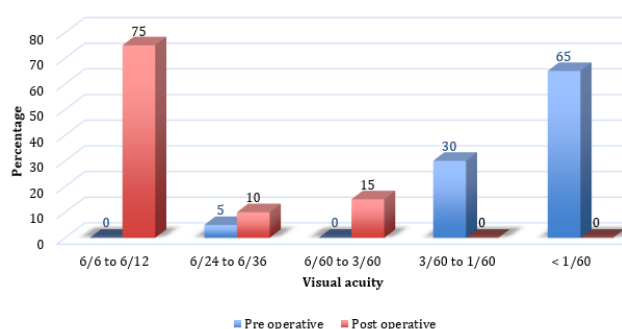


Figure 1: Visual outcome following SFIOL

In our study 65% patients presented with visual acuity of <1/60 i.e., hand movement, counting finger or PLPR. Following SFIOL, visual acuity improved significantly i.e., 75% patients had visual acuity of 6/6 to 6/12 (p<0.05).(Figure 1)

**Table 1:** Distribution of patients according to baseline variables

Baseline variables		Frequency (n=20)	P percentage
Age	≤ 30	4	20
	31 – 60	8	40
	≥ 60	8	40
Gender	Male	14	70
	Female	6	30
Eye	Right	10	50
	Left	10	50

**Table 2:** Distribution according to causes

Causes	Frequency (n=20)	Percentage
IOL Explant s/p Optic Capture with dense Posterior capsular opacification	1	5
Posterior dislocation of IOL with Capsular Bag dialysis	2	10
Anterior dislocation of IOL-Capsular Bag complex s/p	1	5
Corneal tear repair and Retinal detachment surgery		
Capsular bag dialysis noted during Phacoemulsification	1	5
Close globe injury	5	25
ECCE s/p Complicated cataract with seclusio and oclusio-pupillae	1	5
Inferior capsular bag dialysis noted during Phacoemulsification	1	5
K/c/o Marfan's syndrome	1	5
Lens aspiration during open globe injury with Traumatic cataract repair	1	5
Lensectomy during Open globe injury (Corneal perforation) +Vitreous hemorrhage repair	1	5
Open globe injury	1	5
Posterior capsular rent during Phacoemulsification	3	15
Posterior dislocation of nucleus in vitreous during Phacoemulsification	1	5

#### 4. Discussion

Sclera fixated intraocular lens implantation using sutureless Yamane's technique has been recommended in various conditions including aphakia, subluxated lens. Its utility in aphakia is reported in previous studies.<sup>9-11</sup> SFIOL is advantageous as it allow the intraocular lens to be placed to as close as physiological position of lens. Sutureless SFIOL also can be considered superior to sutured SFIOL as suture related complications such as suture breakage, knot exposure and IOL subluxation can be avoided in such cases.<sup>5</sup> Agarwal et al was the first ophthalmologist to achieve sutureless implantation of intraocular lens with the help of fibrin glue close to the scleral flaps. However, tunnel created with the help of this technique were very large which made externalization of haptics difficult. Also, large tunnel was associated with mismatch in the diameters of the sclerotomy and IOL haptic, which further lead to wound leakage and postoperative hypotony. Also, the glue is costly and ensuring its availability is difficult.<sup>3</sup> Thus, to overcome these complications, Yamane et al suggested a modified surgical technique which was sutureless and glueless.<sup>8</sup>

In present study, we utilized the SFIOL for management of not only aphakia, but also of subluxated lens, or any other pathological condition of lens. SFIOL was conducted with other ophthalmologic procedures.<sup>12</sup> The Yamane's technique could be conducted with good precision along with ECCE, ICCE, retinal detachment surgery, Phacoemulsification, lensectomy etc. The surgery is minimally invasive and is associated with early recovery, low complications in hands of experience surgeon. We documented no complications in our study during the procedure as well as in the postoperative period.<sup>13</sup>

Yamane's technique was associate with good visual outcome i.e. majority of cases had visual acuity of less than 3/60 at the time of presentation whereas during the post-operative period, visual acuity improved in 100% cases and majority of patients had visual acuity in the range of 6/6 to 6/12. Similar findings were documented by Walia et al, in which the authors documented significant improvement in visual acuity following Yamane's SFIOL ( $p < 0.05$ ).<sup>14</sup> Yamane et al observed BCVA of 0.48 logMAR units preoperatively, which improved postoperatively to 0.17 logMAR units ( $P = 0.002$ ).<sup>11</sup> In another study by

Baskaran et al, significant improvement of visual acuity (>2 line of improvement was noted in 18 of 19 eyes.<sup>15</sup> Thus, this surgical technique was associated with significant improvement in visual acuity with early recovery and lower complications. Also, the surgery in our cases required few corneal and trans-scleral penetrations and operative time was also less.

## 5. Conclusion

Yamane's novel suture less, flapless and glue less technique of SFIOL implantation can be effectively utilized for management of aphakia and subluxation of lens due to various etiologies. Visual outcome in cases with aphakia and lens related causes of low visual acuity can be improved with SFIOL with avoidance of other suture and flap related complications as well.

## 6. Conflict of Interest

None declared.


## 7. Source of Funding

No source of outside funding

## References

1. Snell RS, Lemp MA. Clinical Anatomy of the Eye. 2nd ed. John Wiley & Sons; 2009.
2. Alpar J. Present state of management of aphakia. Future of spectacles and contact lenses. *Indian J Ophthalmol*. 1989;37(2):54–7.
3. Kumar DA, Agarwal A, Agarwal A, Prakash G, Jacob S. Glued intraocular lens implantation for eyes with defective capsules: A retrospective analysis of anatomical and functional outcome. *Saudi J Ophthalmol*. 2011;25(3):245–54.
4. Sindal MD, Nakhwa CP, Sengupta S. Comparison of sutured versus sutureless scleral-fixated intraocular lenses. *J Cataract Refract Surg*. 2016;42(1):27–34.
5. Wagoner MD, Cox TA, Ariyasu RG, Jacobs DS, Karp CL. Intraocular lens implantation in the absence of capsular support: a report by the American Academy of Ophthalmology. *Ophthalmology*. 2003;110(4):840–59.
6. Gabor SG, Pavlidis MM. Sutureless intrascleral posterior chamber intraocular lens fixation. *J Cataract Refract Surg*. 2007;33(11):1851–4.
7. Baskaran P, Ganne P, Bhandari S, Ramakrishnan S, Venkatesh R, Gireesh P, et al. Extraocular needle-guided haptic insertion technique of scleral fixation intraocular lens surgeries (X-NIT). *Indian J Ophthalmol*. 2017;65(8):747–50.
8. Yamane S, Sato S, Maruyama-Inoue M, Kadonosono K. Flanged intrascleral intraocular lens fixation with double-needle technique. *Ophthalmology*. 2017;124(8):1136–42.
9. Wilgucki JD, Wheatley HM, Feiner L, Ferrone MV, Prenner JL. One-year outcomes of eyes treated with a sutureless scleral fixation technique for intraocular lens placement or rescue. *Retina*. 2015;35(5):1036–40.
10. Zhang Y, He F, Jiang J, Li Q, Wang Z. Modified technique for intrascleral fixation of posterior chamber intraocular lens without scleral flaps. *J Cataract Refract Surg*. 2017;43(2):162–6.
11. Baskaran P, Ganne P, Bhandari S, Ramakrishnan S, Venkatesh R, Gireesh P, et al. Extraocular needle-guided haptic insertion technique of scleral fixation intraocular lens surgeries (X-NIT). *Indian J Ophthalmol*. 2017;65(8):747–50.
12. Kumar B, Muni I. Scleral Fixation of Intraocular Lenses. Treasure Island (FL): StatPearls Publishing; 2023.
13. Cheng T, Liu T, Zhang G, Zhang G, Zhang X. Does Minimally Invasive Surgery Improve Short-term Recovery in Total Knee Arthroplasty? *Clin Orthop Relat Res*. 2010;468(6):1635–48.
14. Walia S, Kashyap S, Bhaisare V, Rawat P, Kori N. Novel technique of sutureless glueless scleral fixated intraocular lens (SFIOL). *Indian J Ophthalmol*. 2019;67(1):64–8.
15. Yamane S, Inoue M, Arakawa A, Kadonosono K. Sutureless 27-gauge needle-guided intrascleral intraocular lens implantation with lamellar scleral dissection. *Ophthalmology*. 2014;121(1):61–6.

## Author biography

**Dheerendra Singh**, Consultant  <https://orcid.org/0000-0002-7224-6611>

**Ganesh Pillay**, Consultant

**Cite this article:** Singh D, Pillay G. Visual outcome and prognosis following SFIOL implantation by Dr. Shin Yamane's double needle based haptic exteriorization with transconjunctival flanging of haptic tips technique. *Panacea J Med Sci* 2024;14(2):545-548.