

Resurgence of Balloon Tamponade in the Management of Post-Partum Haemorrhage

Neelima Agarwal^{1,*}, Manisha Gupta², Amita Sharma³, Alpana Agarwal⁴

^{1,2,3,4}Professor, Dept. of Obstetrics and Gynaecology, Santosh Medical College & Hospital, Ghaziabad, UP

***Corresponding Author:**

Email: agarwalneelima2@gmail.com

Abstract

Postpartum hemorrhage (PPH) in developing countries continues to be the single most common cause of maternal morbidity and mortality, accounting for approximately 25 percent of maternal deaths globally. Fourteen million cases of PPH occur each year. Deaths and serious complications resulting from PPH can be attributed largely to the lack of available emergency obstetrical interventions, inadequate referral systems, and the delivery of substandard care.⁽¹⁾

A balloon tamponade is a minimally invasive obstetric intervention that can effectively treat and manage severe postpartum bleeding. When inserted into the uterus and slowly filled with saline water, it exerts pressure on the uterus until the bleeding stops. It works rapidly and effectively, reducing the need for risky surgical interventions and blood transfusions. It also serves a critical role in reducing blood loss until the woman can be transported to a facility that can provide surgical management and other treatment options. The World Health Organization, the International Federation of Gynecology and Obstetrics, and the International Confederation of Midwives recognize balloon tamponades as a method that could have significant impact in the management of intractable PPH.²

The origin of the word tamponade appears to have come from an old French word for tampon, which carries the connotation of a plug, a bung or a stopper inserted into an open wound or a body cavity to stop the flow of blood. In context to post-partum haemorrhage, normally, this is in the form of a gauze pack or a balloon catheter. Internal tamponade procedures have been used successfully alone^{3,4} or in combination with the Brace suture to reduce or arrest massive postpartum hemorrhage.

Principles Regarding Tamponade:

Uterine tamponade requires developing intrauterine pressure to stop bleeding. This can be accomplished in two ways:

1. By insertion of a balloon that distends in the uterine cavity and occupies the entire space, thereby creating an intrauterine pressure that is greater than the systemic arterial pressure. In the absence of lacerations, the blood flow into the uterus should stop the moment the pressure in the tamponade balloon is greater than that of the systemic arterial pressure.
2. By insertion of a uterine pack consisting of a gauze roll that is tightly packed into the uterus in such a manner that pressure is applied directly on capillary/venous bleeding vessels or surface oozing (of deciduas) from within the uterus, thereby resulting in either a significant reduction or stoppage of uterine bleeding.

Methods

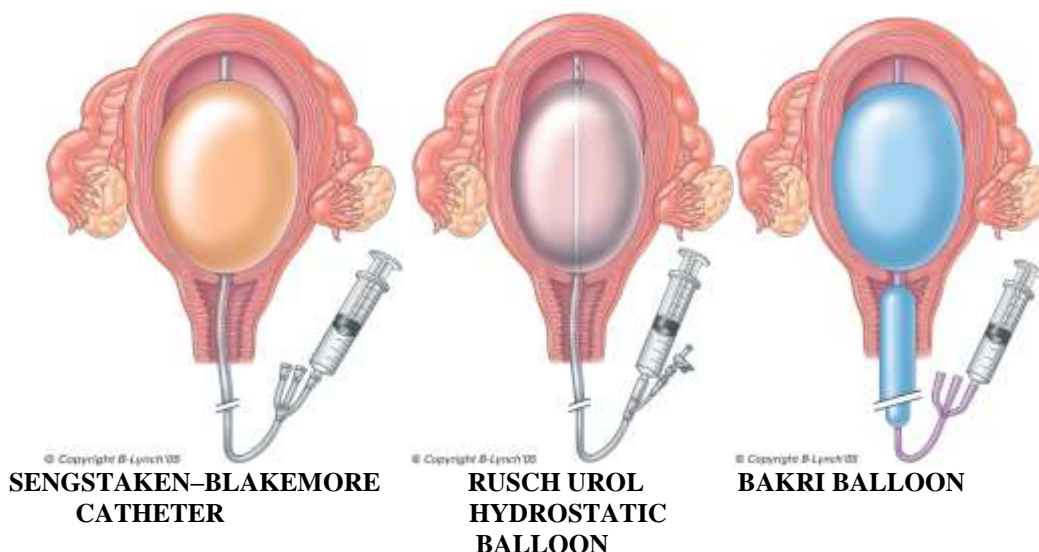
Sengstaken–Blakemore Oesophageal Catheter: The Sengs taken–Blakemore esophageal catheter was originally designed for the treatment of esophageal variceal bleeds and the introduction of contrast media. It is a three-way catheter tube with stomach and esophageal balloon components. It can be inflated to volumes greater than 500 ml. Several reports on its successful use to arrest major postpartum hemorrhage are available.

Rusch Urological Hydrostatic Balloon: This is a two-way Foley catheter (simplastic 6.7 mm, 30ml), which

can also be used for postpartum hemorrhage. It has a capacity greater than 500 ml. The technique of insertion is similar to the description already given for the Sengstaken–Blakemore esophageal catheter. A 60-ml bladder syringe can be used for inflating the balloon with warm saline via the drainage port. It is a simple technique and therefore junior residents can easily learn and become adept in its use, especially if practiced after a manual removal of the placenta.

Bakri Balloon: The SOS Bakri tamponade balloon catheter is marketed as 100% Silicon (no latex), purpose-designed two-way catheter, to provide temporary control or reduction of postpartum uterine bleeding when conservative management is warranted. Again, the insertion technique is simple. Insert the balloon portion of the catheter in the uterus, making sure that the entire balloon is inserted past the cervical canal and internal OS, under ultrasound guidance if possible. At Cesarean delivery, the tamponade balloon can be passed via the Cesarean incision into the uterine cavity with the inflation port passing into the vagina via the cervix. An assistant pulls the shaft of the balloon through the vaginal canal until the deflated balloon base comes into contact with the internal cervical os. The uterine incision is closed in the usual fashion, taking care to avoid puncturing the balloon while suturing. A gauze pack soaked with iodine or antibiotics can then be inserted into the vaginal canal to ensure maintenance of correct placement of the balloon and maximize the tamponade effect.

The balloon is then inflated with sterile fluid to the desired volume for tamponade effect. Gentle traction on the balloon shaft ensures proper contact between the balloon and the tissue surface and may enhance the tamponade effect. Success can be judged by the declining loss of blood seen through the drainage port and the fluid connecting bag.



Foleys Catheter: The successful use of the Foley catheter balloon for internal uterine tamponade is also described. A Foley catheter with a 30-ml balloon capacity is easy to acquire and may routinely be stocked on labor and delivery suites. Using a No. 24 Foley catheter, the tip is guided into the uterine cavity and inflated with 60–80 ml of saline (a volume of 150 ml can be reached before it bursts). Additional Foley catheters can be inserted, if necessary, until bleeding stops. As attractive, easy and cheap as this method is, some concerns have been raised regarding the use of the Foley catheter for uterine tamponade. First, the capacity of the immediate postpartum uterine cavity, especially if term, is too large for effective tamponade to be achieved with one inflated balloon, and the risk of one balloon falling out of the uterus is increased.⁵ Second, significant bleeding may occur above the Foley bulb, as it may not fill the entire uterine cavity. Even the use of multiple Foley catheters cannot ensure a complete compression effect on the entire uterine surface.

Hydrostatic Condom Catheter: This innovative approach from Bangladesh uses a sterile rubber catheter fitted with a condom as a tamponade balloon device. The sterile catheter is inserted within the condom and tied near the mouth of the condom with a silk thread, and the outer end of the catheter is connected to a saline set. In its original description, after placement in the uterus, the condom is inflated with 250–500 ml normal saline according to need, and the outer end of the catheter was folded and tied with thread after bleeding

had stopped. Vaginal bleeding is observed and further inflation is stopped when bleeding has ceased. To keep the balloon in situ, the vaginal cavity is packed with roller gauze and sanitary pads. Success is gauged by the amount of blood loss per vaginum. Hemorrhage was arrested within 15 min in all 23 cases in the original series.⁶ Although the sample size was small, this method represents a cheap, simple and quick intervention which may prove invaluable in, especially, resource-poor countries.

The Tamponade Test: This test, first described by Condous and colleagues,⁷ was proposed as a prognostic index as to whether laparotomy would be needed in patients with major postpartum hemorrhage unresponsive to medical therapy. In the original description, a Sengstaken–Blakemore esophageal catheter was inserted into the uterine cavity via the cervix, using ultrasound guidance when possible, and filled with warm saline until the distended balloon was palpable per abdomen surrounded by the well-contracted uterus, and visible at the lower portion of the cervical canal. The position of the Sengstaken–Blakemore esophageal catheter was checked to ensure it was firmly fixed in-situ within the uterine cavity by the application of gentle traction. If no or only minimal bleeding was observed via the cervix or there was only minimal bleeding into the gastric lumen of the Sengstaken–Blakemore esophageal catheter, the tamponade test result was considered to be positive. If this were the case, surgical intervention, with possible hysterectomy, was avoided. On the other hand, if

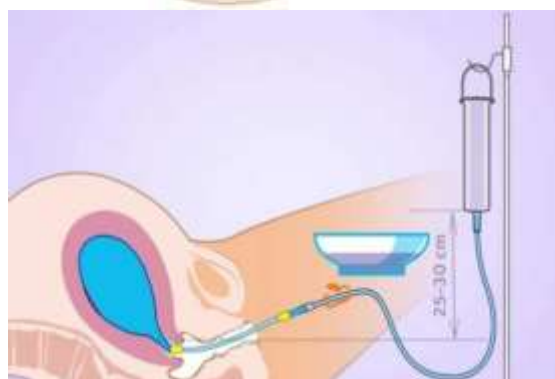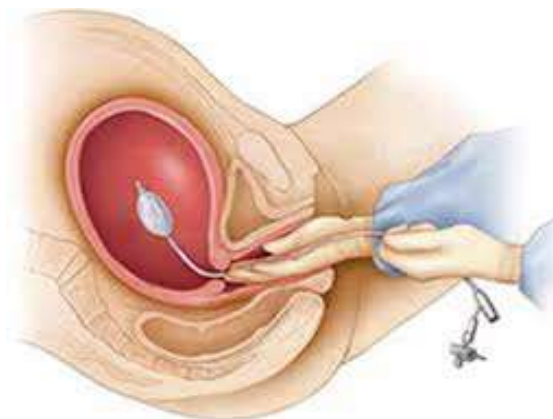
significant bleeding continued via the cervix or the gastric lumen of the tube, the tamponade test was deemed a failure and laparotomy was performed. In this study, 14 out of 16 women (87.5%) with intractable hemorrhage responded positively. Of the women who did not respond, one continued to bleed because of an overlooked cervical extension of the lower transverse uterine incision at cesarean delivery. The balloon was inadequately inflated in the other. The Rusch urological balloon has also been used successfully for the tamponade test.

Uterine Balloon Tamponade

Methodology

Exclude local trauma or retained tissue in the uterus under spinal, epidural or general anaesthesia.

- a. Secure the anterior lip of cervix with a sponge forceps.
- b. When the Sengstaken-Blakemore catheter is used, cut and remove the distal tube to facilitate insertion and retention in the uterine cavity.
- c. Hold the balloon catheter with another sponge forceps and insert it into the uterine cavity.
- d. Fill the balloon with warm sterile water until it becomes visible in the cervical canal. When the pressure exceeds that of the patient's blood pressure, no additional fluid needs to be added and the bleeding should stop.
- e. If there is no bleeding through the cervix or through the drainage channel of the balloon catheter, the tamponade test result is pronounced successful and no further fluid is added.
- f. If the bleeding does not stop, the test is unsuccessful and laparotomy is indicated.
- g. The uterine fundus is palpated abdominally and a mark is made with a pen as a reference line from which any uterine enlargement or distention would be noted.
- h. Start oxytocin drip (20 IU in 500 ml of normal saline) to keep the uterus contracted.
- i. Keep the patient under constant surveillance. Monitor pulse, blood pressure, fundal height, and signs of any vaginal bleeding or bleeding through the lumen of the catheter every 30 minutes. Check temperature every 2 hours and urinary output every hour via an in-dwelling Foleys catheter.
- j. Give intravenous broad-spectrum antibiotics at the time of insertion and for up to 3 days.



Insertion technique of balloon catheter

Removal of the balloon:

- a. After 6-8 hours, if the uterine fundus remains at the same level and there is no active bleeding through the cervix or the central lumen of the catheter, it is safe to remove the balloon, provided that the woman is stable and adequate blood replacement has been provided.
- b. Keep the patient fasting for 2 hours after the removal of the balloon, in case surgery is required under anaesthesia.
- c. Deflate the balloon slowly, but do not remove it for 30 minutes.
- d. Continue the oxytocin drip even if there is no bleeding.
- e. After 30 minutes, if there is still no bleeding, discontinue the oxytocin drip and remove the balloon catheter.
- f. If bleeding starts when the balloon is deflated, inflate the balloon again.

Results

The SBOC has been the most frequently reported device. The overall reported success rates vary between 70-100%.⁸ Uterine tamponade with the SBOC has been described as a prognostic test (the tamponade test) in obstetric hemorrhage in a study,⁷ with a positive result of >87% in successful management of PPH.

Furthermore, the use of balloon tamponade in the successful management of PPH secondary to extensive vaginal lacerations has recently been reported.⁽⁴⁾

Balloon tamponade can also effectively control bleeding in the cases of placenta previa,⁹ placenta accreta, amniotic fluid embolism, septic shock with disseminated intravascular coagulation, and retained placenta.⁸

Conclusion

The tamponade procedures are simple, cheap, easy to use, and effective measures that should be considered in women with intractable postpartum hemorrhage, especially when other options may be unavailable. The method has the **advantages** that:

- i. Insertion is easy and rapid, with minimal anaesthesia.
- ii. It can be performed by relatively inexperienced personnel.
- iii. Removal is painless.
- iv. Failed cases can be identified rapidly.

The early use of balloon tamponade may be expected to result in reduced total blood loss and hemorrhage related maternal mortality. Till date, no immediate complications (such as bleeding or sepsis) or long-term complications (such as menstrual problems or problems with conception) have been reported in women who have undergone uterine tamponade.

References

1. Prevention and treatment of postpartum hemorrhage in low-resource settings; *International J. of Gynecol and Obstet*;117(2012):108-118.
2. Erica Jacoby. Technological solutions for global health 2010.
3. Georgiou C. Balloon tamponade in the management of postpartum hemorrhage: a review. *BJOG* 2009;116(6):748-57.
4. Tatterall M, Braithwait W. Balloon tamponade for vaginal lacerations causing severe postpartum hemorrhage. *Br J Obstet Gynecol* 2007;114:647-648.
5. Doumouchtsis SK, Papageorghiou AT, Arulkumaran S. Systematic review of conservative management of postpartum hemorrhage; what to do when medical management fails. *Obstet Gynecol Surv* 2007;62:540-547.
6. Mary Ann Liebert. Condom catheter balloon in the management of postpartum hemorrhage. *Journal of Gynecologic surgery: Vol(27)*,2011.
7. Frenzel D, Condous GS, Papageorghiou AT, McWhinney NA. The use of the 'tamponade test' to stop massive obstetric haemorrhage in placenta accreta. *Br J Obstet Gynecol* 2005; 112: 676-7.
8. Kavak SB, Kavak EC, Ismail Demirel. Double-balloon tamponade in the management of postpartum hemorrhage: a case series. *Ther Clin Risk Manag.* 2014;10: 615–620.
9. Pınar K, Demirci O. The Bakri balloon for the management of postpartum hemorrhage in cases with placenta previa. *Eur J Obstet Gynecol & Reprod Bio.* 2013; 167(2):167–170