

## Fixation in bimalleolar fractures of ankle-a comparative study between fibula plating versus intramedullary nailing with medial malleolar screw

Murtuza Rassiwala<sup>1,\*</sup>, Jayant Sharma<sup>2</sup>, Pramod P. Neema<sup>3</sup>, Mayank Patel<sup>4</sup>

<sup>1,4</sup>Resident, <sup>3</sup>HOD, Unique Super Speciality Centre, Indore, <sup>2</sup>Associate Professor, Index Medical College, Indore

\*Corresponding Author:

Email: mrtzrassiwala@gmail.com

### Abstract

**Background:** A bimalleolar ankle fracture is unique in the sense that ankle is the distal most weight bearing joint and locomotion depends upon stability of the ankle mortise. The best option for management of bimalleolar ankle fracture still remains unclear because of the variability of fracture patterns and availability of variety of implants.

**Objectives:** This study was conducted to set the indications for the two modalities of surgical fixation viz- fibular plate fixation and fibula nailing in various fracture subtypes; and to compare the functional outcome of bimalleolar ankle fracture managed by these two methods at 9 months post-operative interval. Complications associated with specific modalities of fixation were also studied.

**Material and Method:** This was a randomized, prospective and comparative study for the methods used for management of the fracture done in Department Of Orthopedics and Traumatology at USSC, Indore from January 2014 to April 2016. 45 patients with bimalleolar fractures were included in the study. Clearance from ethical committee of the institute was taken. Informed consent was taken and patients were evaluated pre operatively and post operatively at 1, 3, 6 and 9 months interval with the help of Olerud Molander Ankle Score (OMAS) and radiographically.

**Results:** Duration after which partial weight bearing was initiated was significantly shorter in group1 (fibula plating) ( $p < 0.0001$ ) [average 44.54 days as compared to 55.71 days].

The average time before union and hence full weight bearing was 11.89 weeks (range 10.71 - 13.28 weeks) in group 1 and 13.67 weeks (range 11.56-15 weeks), ( $p < 0.0001$ ) in group 2 (Intramedullary nailing).

Functional outcome using OMAS scoring at 3 months post operatively was significantly better in group 1 ( $p < 0.0001$ ). While at 6 months and 9 months post operatively the functional outcomes were similar.

**Conclusion:** We concluded that Fibula Plating is a better method of fixation in AO type B2, B3 and C2 fractures while Intramedullary Nailing in Fibula is a better method of fixation in AO type A2 fractures with respect to clinical and functional outcomes. We also concluded that if the ligament injury has been dealt with properly and repaired and the fixation is anatomically sound the period of immobilization (4 to 6 weeks) does not affect the range of motion of ankle joint in the long duration.

**Keywords:** Plating, Nailing, Bimalleolar ankle Fractures, Olerud Molander score.

### Introduction

Ankle fractures are one of the most common skeletal injuries seen in clinical practice.<sup>(1)</sup> Sir Robert Jones said "Ankle is most injured joint of the body but the least well treated".<sup>(2)</sup> Ankle injury gain importance because body weight is transmitted through it and locomotion depends upon stability of joint. They are usually mixed injuries, ligamentous and bony and each injury is an end result of ligamentous and bony failure due to deforming forces.

The two most universally accepted classification systems are the Danis-Weber and Lauge-Hansen systems.<sup>(3-5)</sup> While both systems define the fracture pattern, managing these injuries is primarily based on an assessment of stability, which incorporates the amount of displacement, presence of medial injury and associated talar shift.

The goals of treatment include achieving sound union of fracture and an ankle that moves and functions normally without pain. As has been shown experimentally by Paul L. Ramsey, about one mm lateral shift in Talus, produces about 42 per cent of decrease in tibio-talar contact area.<sup>(6)</sup> This obviously shows the need for perfect anatomical reduction, which could be better,

achieved by open reduction and better maintained by internal fixation.

The operative method restores the anatomy and contact-loading characteristic of the ankle. Additional advantages include easier rehabilitation without a cast, early mobilization and earlier weight bearing.<sup>(7)</sup>

The aim of this study was to evaluate the clinical and functional results of patients with bimalleolar fractures treated with semitubular/Reconstruction plating or intra medullary nailing in fibula along with medial malleolar screw and their outcomes in various subtypes.

### Materials and Methods

**Source of Data:** 45 patients with bimalleolar fractures of the ankle treated at Unique Super Speciality Centre, Indore between January 2014 and April 2016 were included in the study.

#### Inclusion Criteria:

- Patients with bimalleolar fractures of ankle
- Patient age > 21 years
- Closed fractures
- Patients willing for treatment and who gave informed written consent.

**Exclusion criteria:**

- a. Patients < 21 years of age
- b. Medically unfit cases.
- c. Compound fractures
- d. Associated with other fractures
- e. Cases which are treated by non-operative methods (Type I Dennis Weber)

Patients were operated at USSC, Indore with a minimum period of 9 months follow up. Radiologic investigation was done with antero-posterior and lateral views of the ankle.

Group 1 was defined as patient treated with malleolar screw for medial malleolus and semi-tubular/ Reconstruction plate for lateral malleolus. 24 patients were randomly placed in this group.

Group 2 was defined as patients treated with malleolar screw for medial malleolus and intramedullary nail for lateral malleolus. 21 patients were randomly placed in this group.

**Operative procedure:** Surgery was carried out as early as possible to avoid subsequent swelling and skin problems. Ankle swelling peaks in 1 to 7 days, and operative treatment was best done before the period of maximal swelling or after the initial swelling was resolved.

The reconstruction of the fibula takes priority and therefore the lateral side was dealt with before the medial side. It was sometimes necessary to fix the medial side first, as in complex fractures with comminution and discontinuity of the fibula.<sup>(8)</sup> Surgical procedures were performed under tourniquet control with all aseptic precautions. The duration of surgery ranged from 30 minutes to 90 minutes with an average of 60 minutes.

1. **Fixation of Medial Malleolus:** A medial longitudinal incision of 8 cm was put over the medial malleolus between its anterior and posterior borders with the lower end curving anteriorly at the tip of medial malleolus. The incision was deepened to the bone protecting the long saphenous vein over the anterior part of the incision. The skin and subcutaneous tissue was retracted anteriorly and posteriorly without undue pressure over the skin. The fracture site was exposed and cleared of blood clots and intervening periosteum with a curette exposing small serrations of the fracture. The distal fragment was held with a towel clip and pulled proximally, reducing the articular geometry at the mortise and the small serrations of the fracture. Two K-wires of 2mm diameter and 8cm long were passed one anterior and one posterior from the tip of the malleoli to the proximal tibia transfixing the malleoli to the tibia without entering the joint. The towel clip was removed and a drill hole was made perpendicular to the fracture line with 3.2 mm cannulated drill bit, then tapped with 4.5mm tap securing the reduction and then screws

(malleolar/cancellous) were inserted and tightened to achieve compression at the fracture site.

**2. Fixation of The Lateral Malleolus**

- a. **Plating:** The lateral malleolus was approached through a postero-lateral incision. The incision was put about 12 cm proximal to the tip of lateral malleolus and extended distally along the posterior margin of the fibula to the tip of malleolus and curved it anteriorly for 2.5cm in line of peroneal tendons.

The fibula was exposed sub periosteally by deepening the incision through subcutaneous tissue and deep fascia. Full thickness skin flaps was retracted anteriorly and posteriorly. Soft tissue and periosteum was cleared a few millimeters of the fracture edge and visualization of the fracture was done. The foot was externally rotated to separate fracture fragments, blood clots and intervening soft tissue was removed with a small curette from the fracture site.

Reduction of the fracture was now done by manipulation.

One third tubular plate was contoured/ reconstruction plate was used to accommodate the lateral bow of the fibula and held in reduction over the lateral side of fibula. Drill holes are made with 2.5mm drill bit. The length of the screw was measured with a depth gauge and tapped with 3.5mm tap. The plate was then fixed with the measured length of cortical screws. The distal two holes were fixed with cancellous screw of length 2mm less than the measured to prevent entry of the tip of screw into the ankle joint. The reduction clamp was then removed and the stability was confirmed. In general, we placed three cortical screws above the fracture line and two/three screws distal to the fracture.

- b. **Nailing:** If the fracture is transverse, an intramedullary device (nail) was used. Expose the tip of the tip of the lateral malleolus by splitting the fibers of the calcaneofibular ligament longitudinally. Insert the intra medullary nail across the fracture line into the medullary canal after making portal at tip of lateral malleolus with a bone awl.

**Follow Up:** Post-operative immobilization of ankle joint was done by posterior slab of 12-15 days.

Sutures were usually removed between 12-15 days, following which Plaster of Paris (POP)/fiber cast in ankle at 90° position was given for 3 to 4 weeks. If the bone condition and other factors prevented secure fixation, the fracture was protected longer. At 4 weeks the POP was removed, clinical examination was done regarding tenderness and movement of ankle. Active movements of the ankle were started for the next 2 weeks without weight bearing. At 6 weeks check x-rays of the ankle were taken and looked for signs of fracture union and then partial weight bearing was started for a further period of 4-6 weeks with elasto crepe bandage and elevation of the limb at night times and active

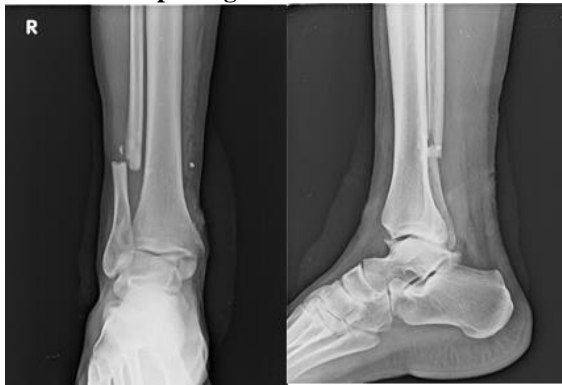movements of ankle joints simultaneously. Patients were then allowed full weight bearing on the affected limb at 11-14 weeks. Regular follow up was done at 1, 3 and 6 months after discharge till the fracture united. Syndesmotic screw is usually removed before weight bearing is allowed.

The Olerud Molander Ankle Score (OMAS) is a self-administered patient questionnaire. The scale is a functional rating scale from 0 (totally impaired) to 100 (completely unimpaired) and is based on 9 different items: pain, stiffness, swelling, stair climbing, running, jumping, squatting, supports and activities of daily living.

OMAS has been frequently used to evaluate subjectively scored function after ankle fracture.<sup>(9-11)</sup>

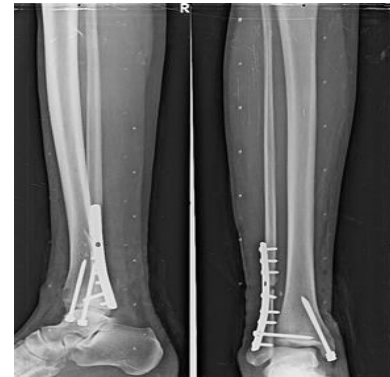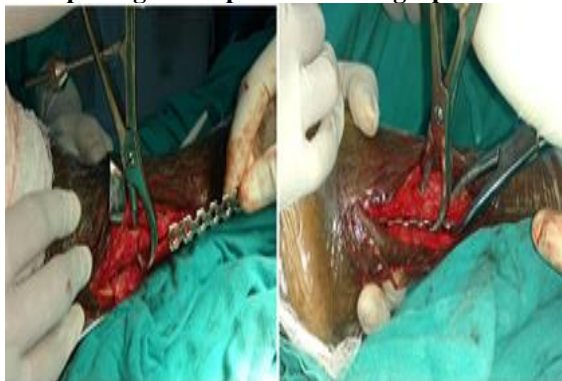We used OMAS in our study to assess the functional outcome at 3 months, 6 months and 9 months follow up period.

**Case 1: Fibula plating with medial malleolar screw**

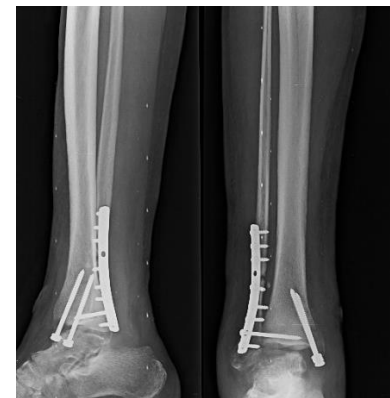


Preoperative Radiograph

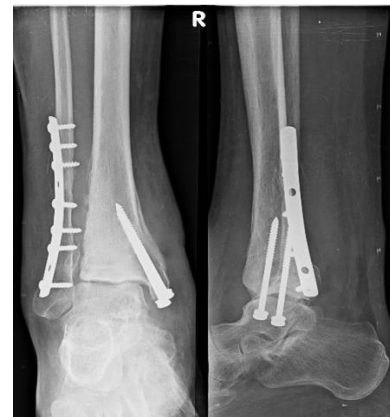**Fibula plating Intraoperative Photograph**



**Immediate post-operative radiograph showing medial malleolar Screw with 1/3 semi tubular fibular plate and syndenmotic screw**

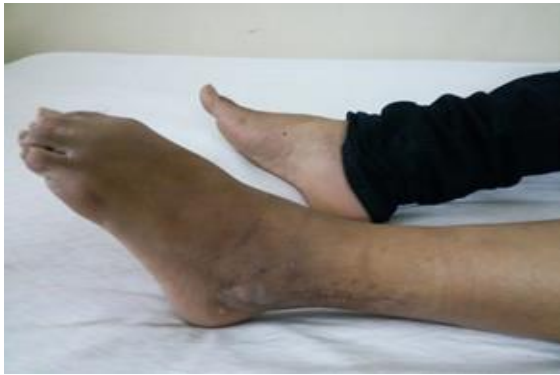

**Six month follow up Radiograph**

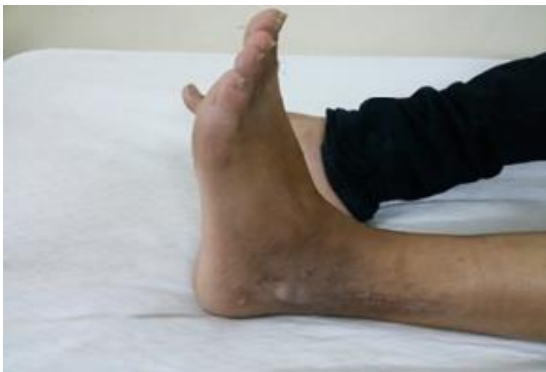

**Nine month Follow-up Radiograph**

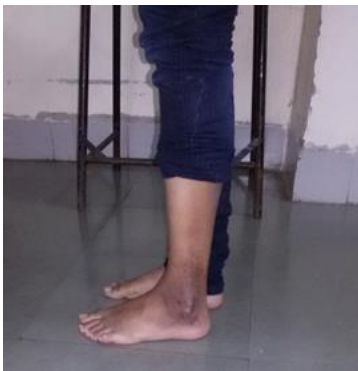**Clinical follow-up Photographs of Fibula Plating at 2months**



**Plantar Flexion**

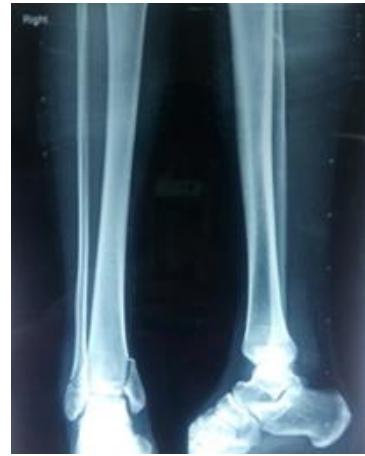

**Dorsiflexion**



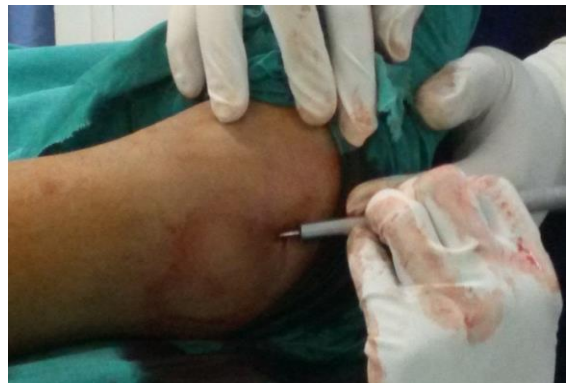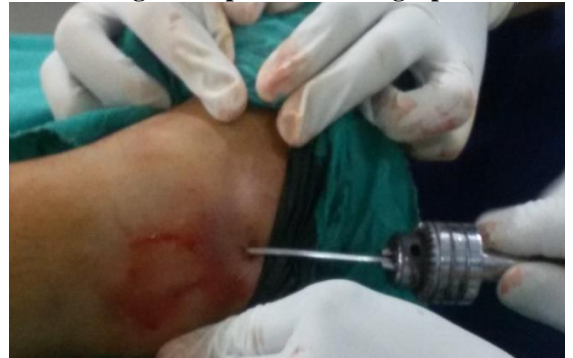**Full Weight bearing without support**

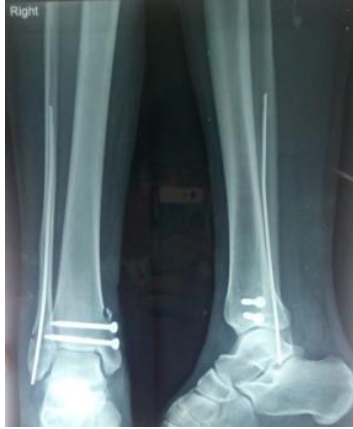**Case 2 Fibula nailing with medical malleolar screw**



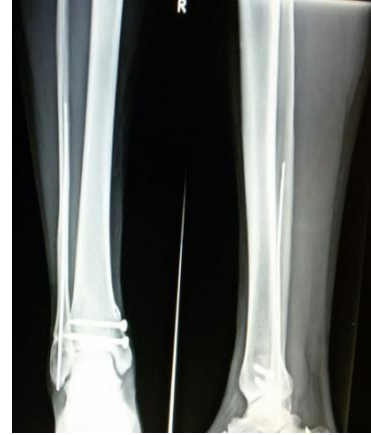**Pre-operative Radiograph**

**Fibula nailing Intraoperative Photograph**

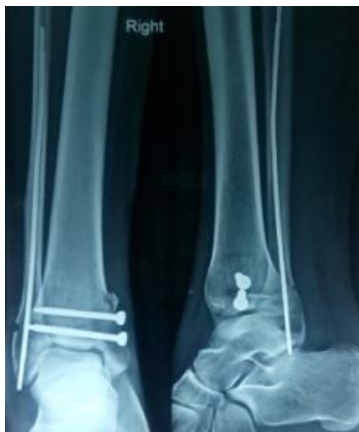



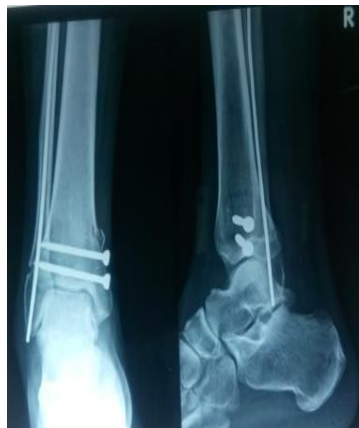Immediate Post-operative Radiograph



9 month follow up Radiograph

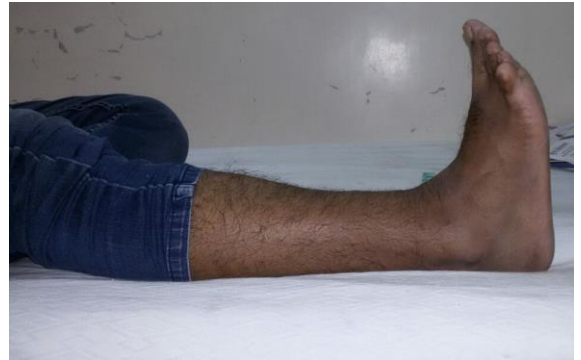

1 month follow up Radiograph

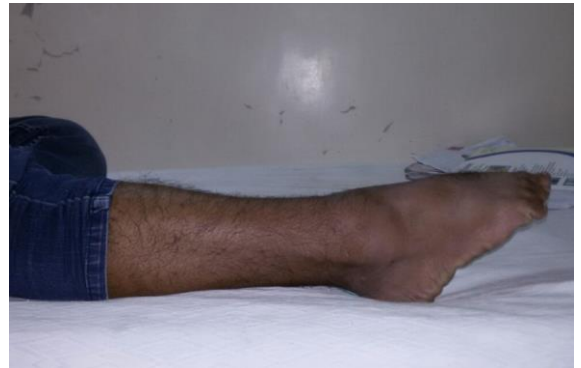

6 month follow up Radiograph

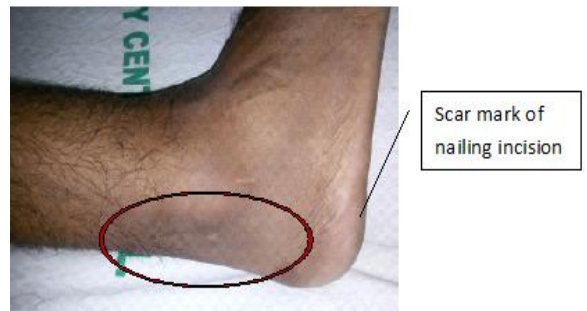Clinical Follow up Photographs of Fibula Nailing at 2 months



Dorsiflexion



Plantar Flexion



## Results

**Table 1: Age group of patients**

| Age group | Group 1 | Group 2 |
|-----------|---------|---------|
| 21-30     | 5       | 4       |
| 31-40     | 3       | 4       |
| 41-50     | 2       | 3       |
| 51-60     | 7       | 5       |
| 61-70     | 4       | 4       |
| >70       | 3       | 1       |

**Table 2: Nature of injury**

| Mode of trauma        | Group 1 | Group 2 |
|-----------------------|---------|---------|
| Fall from height      | 1       | 1       |
| Fall at home          | 4       | 3       |
| Road traffic accident | 11      | 8       |
| Assault               | 0       | 2       |
| Staircase injury      | 3       | 4       |
| Sports related injury | 5       | 3       |

**Table 3: Gender wise distribution**

| Gender | Group 1 | Group 2 |
|--------|---------|---------|
| Male   | 14      | 12      |
| Female | 10      | 9       |

**Table 4: Type of fractures as per Arbeitsgemeinschaft für Osteosynthesefragen (AO) classification**

| Type  | Group 1 | Group 2 |
|-------|---------|---------|
| 44 A2 | 7       | 6       |
| 44 B2 | 9       | 8       |
| 44 B3 | 3       | 4       |
| 44C2  | 5       | 3       |

**Table 5: Angular complication**

| Deformity             | Group 1         | Group 2          |
|-----------------------|-----------------|------------------|
| Malalignment          | 8.33%<br>[2/24] | 14.28%<br>[3/21] |
| Varus deformity(>5°)  | 4.16%           | 9.52%            |
| Valgus deformity(>5°) | 4.16%           | 4.76%            |

**Table 6: Other Complications**

| Complications      | Group 1 | Group 2 |
|--------------------|---------|---------|
| Wound infection    | 3       | 0       |
| Wound Dehiscence   | 2       | 0       |
| Screw breakage     | 1       | Nil     |
| Delayed union      | 0       | 3       |
| Non union          | 0       | 2       |
| Ankle stiffness    | 5       | 2       |
| Implant irritation | 4       | 2       |

**Table 7: Clinical Outcome of patients**

| Outcome measures                   | Group 1<br>Days (Range)<br>Weeks [Range] | Group 2<br>Days (Range)<br>Weeks [Range] |
|------------------------------------|--|--|
| Duration of non-weight bearing     | 44.54(40-52)<br>6.36 [5.71-7.43]         | 55.71(49-61)<br>7.96 [7-8.71]            |
| Duration of partial weight bearing | 38.71(31-46)<br>5.53 [4.43-6.57]         | 40.00(32-45)<br>5.71 [4.56-6.42]         |
| Initiation of full weight bearing  | 83.25(75-93)<br>11.89 [10.71-13.28]      | 95.71 (81-105)<br>13.67 [11.56-15]       |
| Average duration of union          | 83.25(75-93)<br>11.89 [10.71-13.28]      | 95.71 (81-105)<br>13.67 [11.56-15]       |

**Table 8: Functional outcome according to Olerud Molander Ankle Score OMA [out of 100]**

| Outcome measures | Group 1 | Group 2 |
|------------------|---------|---------|
| 3 months post op | 44.38   | 30.24   |
| 6 months post op | 71.04   | 67.14   |
| 9 months post op | 80.42   | 78.81   |

## Discussion

The ankle is a composite joint (hinge). It consists of two dissimilar articulations: syndesmosis connecting the distal end of crural bones and diarthrosis between their ends and talus. The ankle is a mortise in which the talus is constrained by the fibula laterally and tibia both superiorly and medially, this configuration as also been referred to as the malleolar fork.<sup>(12)</sup>

The ankle and foot segments provide a stable but mobile support needed to maintain an upright posture. The movement at subtalar joint and ankle joint are usually supportive to each other. Normal motion of the ankle joint is predominantly in the sagittal plane, but it involves variable degrees of rotation around the vertical and longitudinal axes. Inman described the empirical axis of the ankle joint as passing approximately 5 mm distal to the tip of the medial malleolus and 3 mm distal and 8 mm anterior to the lateral malleolus.<sup>(13)</sup>



The empirical axis of ankle joint is also described as the one passing just below the tips of the medial and lateral malleolus. Because of the variable contours of the medial and lateral talar dome trochlea, ankle joint has a continuously changing axis of rotation.<sup>(14)</sup>

The major weight-bearing surface of ankle is the tibia - talar surface. One sixth of static load of the body weight is transferred through fibula. The fit of talus in mortise is precise, making it the most congruent of the weight bearing joints. This loading actually serves as a stabilizing influence on the joint because it causes the talus to seek an anatomically reduced position underneath the tibial plafond (by means of an associated 2 mm lateral talar shift). The contributions of the articular surfaces, the ligaments, and the capsular and musculotendinous structures, to the stability and function of the ankle are influenced by changes in loading characteristics and joint position and are altered in response to injury.

The ankle fractures occur as a result of strong rotational or predominantly axial Loading. The malleolar fractures are caused predominantly by rotational forces whereas axial loading causes tibial plafond fractures, predominantly. The malleolar fractures primarily involve lateral or medial malleolus and often other parts of the ankle as well. Shearing and tensile forces apposed through the talus produce them indirectly. Most malleolar fractures occur when the part, including the talus, is fixed on the ground by the body's weight. The type of malleolar fracture that occur depends on two factors: the position of the foot at the time of injury, either supination or pronation, and the *deforming force*, which are external rotation, abduction or adduction. A relative bending moment is produced with rotation either in the coronal plane, producing talar adduction or abduction relative to tibia, or transverse plane, causing relative internal rotation of the tibia on the talus. These injuries are referred to as external rotation injuries.

The initial position of the foot is important because it determines which structures are tight and therefore are most likely to be injured first. When the foot is pronated, the deltoid ligament is tense, and the initial injury is medial, either a medial malleolar fracture or a deltoid ligament disruption.

The structures that are damaged are, in order, the anterior tibiofibular ligament (stage 1), the lateral malleolus (stage 2), the posterolateral aspect of the capsule or the posterior malleolus (stage 3), and the medial malleolus or the deltoid ligament (stage 4). A fracture of the posterior malleolus can occur in association with either external rotation or abduction injuries of the ankle.

A classification system is useful only if it assists in the selection of the appropriate management, offers a prognosis of eventual outcome, or allows comparison of the results of treating similar injuries. Several different classification systems of ankle injuries exists, but those in current use are Anatomical types, Lauge – Hansen's

system, Danis-Weber system and the AO/ Orthopaedic Trauma Association (AO/OTA) system. In the present study, AO (Arbeitsgemeinschaft für Osteosynthesefragen) classification system was used for operative evaluation.

Burwell and Charnley showed that anatomical reduction and rigid fixation led to early return to function. The results in current study were compared with that of Burnwell & Charnley.<sup>(15)</sup>

Gregory Joy et al<sup>(16)</sup> study recommended that anatomical reduction is the key towards a good clinical outcome, our study is also in contention with the same.

Most authors have stated that anatomical reduction of displaced medial malleolus ensures correction of talar displacement and is of paramount importance in treating unstable fractures.<sup>(17)</sup> However, Heller et al<sup>(18)</sup> states that talus is more accurately repositioned in mortise by anatomical reduction of lateral malleolus.

Observations in our study support the contention of Yablon et al<sup>(18)</sup> that lateral malleolus is the key to the anatomical reduction of bimalleolar fractures, because the displacement of the talus faithfully followed that of the lateral malleolus. Poor reduction of the lateral malleolus fracture would result in persistent lateral displacement or residual shortening.

Hughes et al<sup>(19)</sup> in their study recommended that lateral malleolus should be fixed first, then medial malleolus is inspected for stability and fixed if necessary. This allows minimal postoperative immobilization and rapid recovery of function. This does not necessarily lessen the importance of medial malleolus, because the fractures of the medial malleolus close to the plafond do require more anatomic reduction to restore normal Tibio-Talar relationship but it does serve to emphasize that the lateral malleolus should no longer be ignored.

Bistrom et al<sup>(20)</sup> in their study stated that the type of the fracture did not dictate the outcome of their study, the same was applicable in our study as well. Therefore our study supports the view of Klosser et al.<sup>(21)</sup> according to which reduction determines the final clinical result irrespective of the type of fracture.

In many studies it was seen that the syndesmosis is stable after reduction and internal fixation of fibula fracture and medial malleolar fracture. In the current series, two patients underwent trans-syndesmotic screw fixation. Excellent outcomes were seen in both the patients.

Winkler et. al<sup>(22)</sup> showed the use of fixation of the antiglide plate in the fixation of lateral malleolus in case of type B Weber fractures. The study showed the construct to be bio-mechanically sound. The use of this technique is being recommended especially in the osteoporotic bones which was found to stand true in our series where 12 osteoporotic patients were treated with plating and had good functional outcomes.

Ramasamy P et al<sup>(23)</sup> performed fibular nailing in 11 Weber B ankle fracture in elderly patients (67.2 years) with osteoporotic bones between March 1996 and

February 2000. All the fractures were displaced with significant talar shift. Nine patients remained under follow-up (average 25.9 months). Results were good and excellent in 88% of cases by the modified Olerud and Molander scoring system. We feel that fibular nailing is an important tool in managing specific types of ankle fracture. In our study we used intramedullary fibular nail in A2, B2 & B3 subtypes with good clinical and functional outcomes. Though malunion did occur in a very few cases.

A number of different post-operative regimens have been suggested. Burwell and Charnley<sup>(24)</sup> advocated postoperative joint mobility exercises in bed until motion was restored followed by full weight bearing in a cast.

Lund -Kristensen et al<sup>(25)</sup> either used no cast or applied one for a few days postoperatively and then allowed full joint mobilization out of the cast. They advocated the use of crutches to maintain a non-weight bearing status.

Meyer and Kumler<sup>(26)</sup> used a post-operative cast but only for an average of 3.8 weeks followed by non-weight bearing mobilization until fracture union. Thus in various studies comparing the effect of early movement compared to immobilisation and weight bearing versus non-weight bearing, the conclusion is that there is no difference in the final result whichever regime is used.<sup>(27)</sup>

In our study, immobilization was done for 4 weeks. Active physiotherapy was started in the bed for another 2 weeks followed by partial weight bearing for those with early radiological signs of union and full weight bearing when the signs of union were complete. The range of motion of ankle was reduced initially, but improved over few weeks. There was no instability of ankle or subtalar joints, because we allowed sufficient time for the soft tissues around the ankle to heal. We preferred postoperative immobilization rather than allowing active ankle exercise as there was no difference in the results after 6 months of follow up.

## Conclusion

Understanding the type and extent of injury in ankle fractures is essential for good reduction and fixation with good functional outcomes. The fibular length has to be maintained for lateral stability of the ankle. Anatomical reduction is essential in all intra articular fractures, more so if a weight bearing joint like ankle joint is involved. The aim of surgery should be to achieve anatomical reduction of the fracture fragments, ankle mortise congruity, restoration of the length of the fibula and restoration of syndesmotic integrity. During surgery, the soft tissues dissection should be kept minimal to avoid further vascular compromise in an already tense, swollen ankle. In the post-operative period, splintage of the ankle and precaution to prevent swelling of the ankle is necessary. The swelling may lead to delayed wound healing. Patients are ambulated with crutches or walker without bearing weight on the injured limb from the first

post-operative day if there are no associated injuries and can be discharged from the hospital by the first week.

The four to six week period of immobilization did not affect the final range of ankle function as most patients had achieved full range of motion by the end of 12 weeks postoperatively with active exercise regimen.

We concluded that Fibula Plating is a better method of fixation in AO type B2, B3 and C2 fractures while Intramedullary Nailing in Fibula is a better method of fixation in AO type A2 fractures with respect to clinical and functional outcomes.

We also concluded that if the ligament injury has been dealt with properly and repaired and the fixation is anatomically sound, then the period of immobilization (4 to 6 weeks) does not affect the range of motion of ankle joint in the long duration.

## References

1. P. Pott. Some few general remarks on fractures and dislocations. 2007:1758. Clin Orthop.;458, pp. 40-41.
2. Dr. Bhavik Y. Dalal, Dr. Krunal J. Chaudhri, Dr. Parimal J. Patel, Dr. Ravi R. Bhesaniya A study of Bimalleolar fractures treated with open & closed method by TBW, k-wire, CC screw & semitubular plate Volume : 3 | Issue : 10 | October 2014 • ISSN No 2277-8179.
3. Danis R. Les fractures malleolaires. In: Danis R, editor. Theorieetpratique de l'osteosynthese. Paris: Masson; 1949.
4. Weber BG. Die verletzungen des oberen sprunggelenkes. 2. Berne: Verlag Hans Huber; 1972.
5. Lauge-Hansen N. Fractures of the ankle II: combined experimental-surgical and experimental-roentgenologic investigations. Arch Surg. 1950;60:957-985. doi: 10.1001/archsurg.1950.01250010980011.
6. Ramsey PL, Hamilton W. Changes in tibiotalar area of contact caused by lateral talar shift. J Bone Joint Surg [Am] 1976;58-A:356-357.
7. Geissler WB, Tsao AK, Hughes JL. Fractures and injuries of the ankle. In: Rockwood and Green's fractures in adults. 4th ed. Lippincott Raven; 1996: 2201-66.
8. Desouza LJ. Fractures and dislocations about the ankle. In: Fractures and dislocations, Chapter- 30, Vol. II, ed. Gustilo RB, Kyle RF, Templeman D, St. Louis: Mosby Year book Inc., 1993, 997- 1043pp.
9. Ponzer S, Näsell H, Bergman B, Törnkvist H: Functional outcome and quality of life patients with Type B ankle fractures: a twoyear follow up study. J Orthop Trauma. 1999;13:3638.10.1097/0000513119990600000007.
10. Olerud C, Molander H: A scoring scale for symptom evaluation after ankle fracture. Arch Orthop Trauma Surg. 1984;103:1904. 10.1007/BF00435553.
11. Olerud C, Molander H: Bimalleolar ankle fractures operated on with non-rigid internal fixation. Clin Orthop. 1986;206:25360.
12. Gumann G. Ankle fractures. In: Foot and ankle trauma. Chapter- 28, Edt. Scurran BL, New York: Churchill Livingstone, 1989;579- 638pp.
13. Inman V, ed. The Joints of the Ankle. Baltimore: Williams and Wilkins, 1976.
14. Barnett CH, Napier JR. The axis of rotation at the ankle joint in man; its influence upon the form of the talus and the mobility of the fibula. J Anat 1952;86(1):1-9.
15. Burwell HN, Charnley AD. The treatment of displaced fractures of ankle by rigid internal fixation and early joint movement. J Bone Joint Surg. 1965;47B:634-60.



16. Gregory Joy, Michael J Paizakis, Paul J Harvey Jr. Precise evaluation of the reduction of severe ankle fractures, technique and correlation with end results. *J Bone Joint Surgery Am* 1974;979-93.
17. Hanssen SH, Bremerskov V, Barkgaard N. Ankle fractures treated by fixation of medial malleolus alone. *Acta Orthopaedica Scandinavia*.1978;49:211-14.
18. YablonIG, Heller FG, Shouse L. The key role of the lateral malleolus in displaced fractures of the ankle. *J Bone Joint Surg Am*. 1977;59(2):169–173.
19. Hughes J. The medial malleolus in ankle fractures. *Orthopaedic Clinics of North America*. 1989 July;11(3):649-660.
20. Bistrom O. Conservative treatment of severe ankle fractures, A clinical and follow-up study. *Acta Clin Scandinavica, Supplementum*; 1952;168.
21. Klossner, Olli. Late results of operative and non-operative treatment of severe ankle fractures. A clinical study. *Acta Chir Scandinavica, Supplementum* 1962;293.
22. Benedikt Winkler. Et al. The dorsal antiglide plate in the treatment of Danis Weber type B fractures of the distal fibula. *CORR* 1990, No 259, p 204.
23. Ramasamy P. Role of fibular nail in the management of Weber Type B ankle fractures in elderly patients with osteoporotic bone – A preliminary report. *Health Sciences Journal* 32(6):477-85.
24. Burwell HN, Charnley AD. The treatment of displaced fractures of ankle by rigid internal fixation and early joint movement. *J Bone Joint Surg*.1965;47B:634-60.
25. Lundberg A, Goldie I, Kalin B, Selvik G. Kinematics of the ankle/foot complex: Plantar flexion and dorsiflexion foot and ankle. 1989;9:194-200.
26. Meyer TL, Kumler KN. ASIF technique and ankle fractures, *Clin Orthop*, 1980;150:211-216.
27. Makwana NK, Bhowal B, Harper WM, Hui AW. Conservative versus operative treatment for displaced ankle fractures in patients over 55 years of age-A prospective study. 2001;83B:525-9.