

## Uterine arteriovenous malformation secondary to scar pregnancy

Smita Goenka<sup>1\*</sup>, Madhuri Gawande<sup>2</sup>, Sulbha Joshi<sup>3</sup>, Chetna Ratnaparkhi<sup>4</sup>

<sup>1</sup>Junior Resident, <sup>2</sup>Assistant Professor, <sup>3</sup>Professor & HOD, Dept. of Obstetrics & Gynecology, <sup>4</sup>Associate Professor, Dept. of Radiodiagnosis, NKP Salve Institute of Medical Sciences, Nagpur, Maharashtra

\*Corresponding Author:

Email: smita.goenka19@gmail.com

### Abstract

Uterine arteriovenous(AV) malformations resulting in abnormal uterine bleeding is relatively rare condition. It can be congenital or acquired. Acquired AV malformation is usually secondary to trauma, pregnancy or malignancy. The mainstay of management is uterine artery embolization or definitive surgery. We report a case of AV malformation in lower uterine segment secondary to previous ruptured scar pregnancy. The condition was diagnosed by Doppler ultrasound and confirmed by MR angiography. Our subject opted for hysterectomy over uterine artery embolization. The clinical findings were confirmed by histopathological examination by presence chorionic villi.

**Keywords:** Arteriovenous malformations, Scar pregnancy, Uterine artery embolization, Doppler ultrasound, MR angiography.

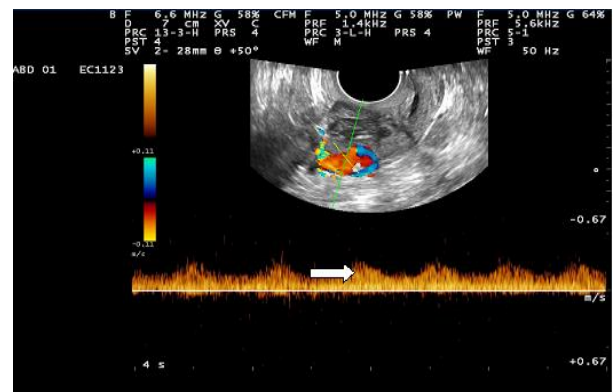
### Introduction

The incidence of cesarean section is increasing worldwide. Hence the incidence of scar pregnancy that is implantation of gestational sac in lower uterine segment at previous scar site is also increasing. Scar pregnancy represents 6% of all ectopic pregnancies.<sup>(1)</sup> The secondary complication of scar pregnancy can be development of uterine arteriovenous malformation at that site. It can result in abnormal uterine bleeding which is usually resistant to medical management.<sup>(2)</sup> The AV malformation in uterus is a rare cause of abnormal uterine bleeding. It can be either congenital or acquired. Acquired AV malformation is usually after pregnancy or pregnancy related complications.<sup>(3)</sup> We are reporting a case of AV malformation in lower uterine segment secondary to previous ruptured scar pregnancy. We are reporting this case for its rarity. Very few cases are reported on literature search.

### Case History

A 37-year-old woman one para and previous one ectopic pregnancy reported in outpatient department of our tertiary care hospital with chief complaints suggestive of irregular and heavy menstrual bleeding since 6 months. She had complaints of irregular and episodic bleeding per vaginum not responding to hormonal management. There was no history suggestive of dysmenorrhoea, post-coital bleeding. On obstetric history she had one full term cesarean delivery for fetal distress 4years back. After her detailed history, it was noticed that six months before she had two and half months amenorrhoea followed by severe pain in abdomen. Through her previous case records we got to know that she had ruptured scar pregnancy at nine weeks of gestation for which laparotomy was performed. The products of conception were removed and scar site was sutured after refreshing the margins. The subject lost for follow up after that. She was

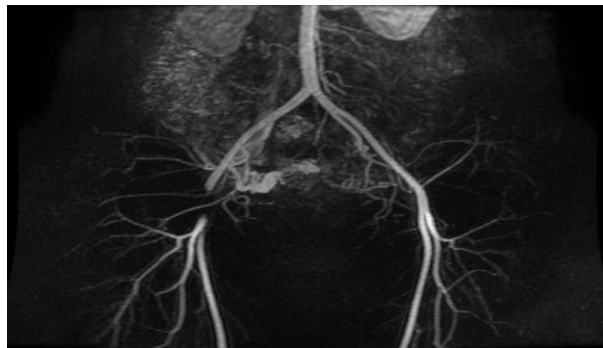asymptomatic for one month after the procedure. After one month she developed intermittent bleeding pervaginum for which she consulted and was treated by physician. It was not responding to medical management. During course of treatment she also received two units of blood transfusions for anemia. On examination her general condition was stable. She was pale. Abdomen was soft with no lump palpable. On per speculum and vaginal examination her cervix and vagina was normal. There was fullness in lower uterine segment. Her serum beta HCG was done which was within normal limits. On ultrasonography uterus was normal in size, shape and echotexture. Endometrium was normal. In lower uterine segment there were hypoechoic areas with echogenic focus within, which on color doppler showed increased vascularity. Largest 1.5 cm x1.4cm lesion showed arterial low resistance flow. Findings were suggestive of AV malformations of lower uterine segment (Fig. 1).



**Fig. 1: Tuft of tortuous blood vessels**

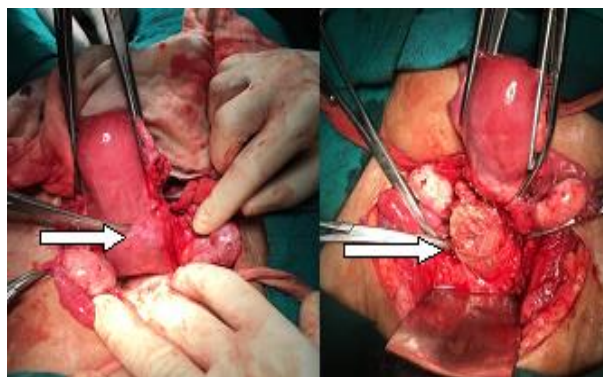
On MR angiography post contrast study suggested that a well defined heterogenous lesion noted in lower uterine segment and proximal cervix measuring 3.7 cm x3.6 cm x4cm hypointense with few hyperintensities. On

contrast multiple dilated tortuous vascular channels were noted in bilateral parametrium. A branch of right internal iliac artery was likely feeding the lesion and multiple dilated collaterals were noted with early drainage into right iliac vein (Fig. 2).



**Fig. 2: MR angiography shows the dilated tortuous vascular channels in right parametrium, feeding vessel from right internal iliac artery**

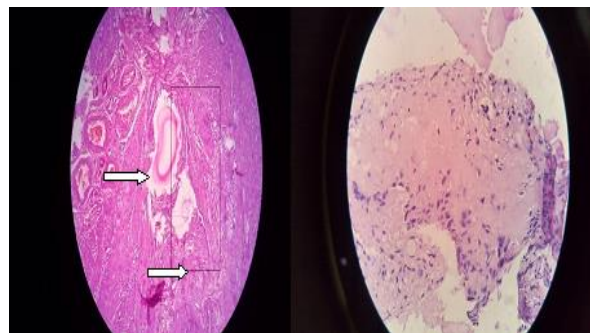
The diagnosis kept was possibility of uterine AV malformation involving lower uterine segment. Considering her age the option of uterine artery embolization was given. But patient opted for hysterectomy over uterine artery embolization due to financial issues. Intraoperatively uterus and ovaries were normal size and shape. A bulge was seen in lower uterine segment more on right side at previous scar site with prominent blood vessels over it. As soon as uterovascular fold was opened, a dead necrotic tissue mass 3 cm x2 cm size could be removed from scar site which was connected to the uterus cavity (Fig. 3).



**Fig. 3: Bulge in lower uterine segment more on right side, and retained products of conception at the same site**

It was not foul smelling. The cervix was normal. Total hysterectomy was done. The approximate blood loss was approximately 300 ml. Intraoperative and postoperative period was uneventful. The histopathology report was degenerated chorionic villi in necrotic tissue removed from previous scar site was suggestive of previous scar pregnancy. There were

dilated vessels more on right side of lower uterine can be suggestive of AV malformation in lower uterine segment (Fig. 4).



**Fig. 4: Dilated vessels and chorionic vill**

### Discussion

Uterine AV malformation resulting in abnormal uterine bleeding is relatively rare condition. It can present as life threatening hemorrhage accounting to 1 to 2% of all genital hemorrhages.<sup>(4-5)</sup> The pathogenesis of uterine AV malformation can be either congenital or acquired. Congenital AV malformation is secondary to abnormal embryonic differentiation.<sup>(6)</sup> Acquired uterine malformation can be the result of trauma, instrumentation, uterine surgery, therapeutic abortion, uterine malignancy and gestational trophoblastic disease.<sup>(7)</sup> Acquired AV malformation of the uterus are characterized by single or multiple AV fistulas (AMFs) which represents the direct connection of an artery and vein. There is no intervening capillary bed. Whereas the congenital AV malformations have nidus of poorly differentiated blood vessels between artery and vein.<sup>(8)</sup> The venous system is unable to accommodate the high flow, high pressure state resulting in higher propensity of bleeding.<sup>(7)</sup> The ultrasonography with Doppler studies can diagnose uterine AV malformation. The acquired AVM is usually secondary to trauma or previous intervention. In our case it was secondary to previous scar pregnancy. The incidence scar pregnancy is rising due to increase in cesarean section rate. In 1978 the first cesarean scar implantation was reported. Cesarean scar pregnancy can be diagnosed by visualization of a gestational sac which is low and anterior in relation to the endometrial stripe complex with attenuated overlying myometrium. The overlying myometrium measures five mm or less in thickness.<sup>(9)</sup> The proposed mechanism for AV malformation secondary to scar ectopic pregnancy can be from failed obliteration of placental blood vessels after removal of retained products of conception. Or if the chorionic villi are retained, it will lead to collateral vessels formation and pseudo-aneurysm vessels.<sup>(3)</sup> On literature search Rygh et al<sup>(1)</sup> reported first case of AV malformation of uterus as a consequence of previous scar ectopic pregnancy in 2009. Uterine AV malformation can be very well diagnosed by Doppler ultrasound in a case of

abnormal uterine bleeding. Ultrasound findings include heterogeneous, ill-defined mass, with multiple, hypoechoic cystic or tubuli form structures varying in size and focal or asymmetrical endometrial and myometrial thickening. Doppler ultrasound demonstrates arteriovenous shunt with high-velocity and low resistance flow.<sup>(10)</sup> MR arteriography can distinguish between an AVM and AVF by demonstrating presence and absence of nidus respectively. As hysteroscopy is routinely done in cases of AUB, hysteroscopy can diagnose AVM and can differentiate between polyp or retained products of conception.<sup>(1)</sup> The differential diagnoses with similar sonographic findings include gestational trophoblastic disease, retained conception products and abnormal placentation. The management of uterine AV malformation is occlusion of nidus, whereas AV fistulas require occlusion of the fistulus communication or its feeding vessels.<sup>(7)</sup> The feeding vessels can be occluded by uterine artery embolization only when distal territory of AV malformation can withstand ischemia. The technical and clinical success rate of UAE for traumatic AVMs are reported 100 and 93% respectively.<sup>(11)</sup> For those who deny for UAE or when embolization fails, surgical removal of uterus is mainstay of management. Because collateral vessels formation is more as in our case non surgical management would have been limited and non successful.<sup>(3)</sup> Janelle et al reported a case of AV malformation secondary to cesarean scar pregnancy which had failed embolization and was extending in the parametrium. To reduce intraoperative bleeding prior internal iliac artery ligation might be required.<sup>(7)</sup> Acquired AV malformation is mostly after pregnancy or pregnancy related complications and may coexist with retained products of conception, gestational trophoblastic disease. The treatment of retained products of conception is curettage. But with AV malformation this procedure can evoke torrential bleeding.<sup>(1)</sup> Hence, before subjecting these patients for definitive surgery prior ultrasound with Doppler should be kept in mind.

### Conclusion

Uterine AV malformation is uncommon cause of abnormal uterine bleeding and can lead to life threatening hemorrhage. When AUB not responding to medical management without any uterine pathology AV malformations should be kept in mind. Though uncommon, uterine AV malformation can be secondary to scar ectopic pregnancy. The mainstay of diagnosis is by Doppler ultrasound and MR angiography. Transcatheter embolisation of feeding vessels is a minimally invasive treatment for such lesions. Those who deny or when embolization is unsuccessful the only option left is definitive surgery.

### References

1. Rygh AB, Greve OJ, Fjetland L, Berland JM, Eggebo TM. Arteriovenous malformation as a consequence of a scar pregnancy. *Acta Obstet Gynecol Scand* 2008;88(7):853-5.
2. Ash A, Smith A, Maxwell D. Caesarean scar pregnancy. *BJOG* 2007;114(3):253-63.
3. Chittawar P, Patel K, Agrawal P, Bhandari S. Hysteroscopic diagnosis and successful management of an acquired arteriovenous malformation by percutaneous embolotherapy. *J Midlife Health* 2013 Jan-Mar;4(1):57-9.
4. Farias MS, Santi CC, Lima AAAA, Teixeira SM, De Biase TCG. Radiological findings of uterine arteriovenous malformation: a case report of an unusual and life-threatening cause of abnormal vaginal bleeding. *Radiol Bras* 2014 Mar/Abr;47(2):122-4.
5. Cura M, Martinez N, Cura A. AV Malformation of uterus. *Acta Radiol.* 2009; 50: 823-9.
6. Kasznica J, Nisa VN. Congenital vascular malformation of the uterus in a stillborn: a case report. *Hum Pathol.* 1995;26:240-1.
7. Jennele KM, Leslie AG, Gloria MS, Annekathryn G. The role of radical surgery in the management of acquired uterine Arteriovenous Malformation. *Case Rep Oncol.* 2013 May-Aug;6(2):303-10.
8. Senthil Kumar Aiyappan, Upasana R, Savitha V. Doppler Sonography and 3D CT Angiography of acquired arteriovenous Malformations: Report of Two cases. *J Clin Diagn Res.* 2014 Feb;8(2):187-9.
9. Matthew Rheinboldt, Dan Osborn, Zach Delproposto. Cesarean section scar ectopic pregnancy: a clinical case series. *J Ultrasound.* 2015 Jun;18(2):191-5.
10. O'Brien P, Neyastani A, Buckley AR. Uterine arteriovenous malformations: from diagnosis to treatment. *J Ultrasound Med.* 2006;25:1387-92.
11. Ghai S, Rajan DK, Asch MR. Efficacy of embolization in traumatic uterine vascular malformations. *J Vasc Inter Radiol.* 2003;14:1401-8.