

Monocanicular repair using angiocatheter tube as a stent in secondary level eye hospital

Suresh Rasaily^{1,*}, Sulaxmi katuwal², Santosh subedi³, Nita Sunam⁴, Jyoti Sapkota⁵, Aric Vaidya⁶

^{1,2,3}Rapti Eye Hospital, Dang, Nepal, ^{3,5,6}Chhanda Kale Babu Narayani Eye Hospital, Kapilvastu, Nepal, ⁴Lamahi Eye Hospital, Dang, Nepal

***Corresponding Author:**

Email: srasaly@gmail.com

Abstract

Canalicular lacerations can result from direct or indirect injury to the canalicular system.

Case 1: A 34 -year-old male had lower canalicular laceration in left eye with a sharp object. An angiocatheter tube was used as a stent for canalicular reconstruction.

Case 2: A 52-year-old male had road traffic accident sustaining injury in right eye resulted in a conjunctival tear in lower fornix, lid tear involving the canaliculus and medial and lateral canthi laceration. All of the structures were repaired successfully during a single procedure. An angiocatheter tube was used as a stent for canalicular reconstruction.

The focus of these report is on the method used, as well as the material for the repair in a rural hospital.

Conclusion: Angiocatheter tube can be a suitable alternative to silicone tube for canalicular repair.

Keywords: Canalicular reconstruction, Angiocatheter tube.

Introduction

Injuries to the eye resulting in lid tears or lacerations also involve the canalicular system in many cases. These types of injuries are more common in children and young adults (Herzum, 2001; Reifler, 1991 and Naik, 2008). This Canalicular system laceration need urgent primary microsurgical repair along with stenting to maintain its patency (Struck, 2009). Out of the various methods available, the most commonly advocated were by using a pigtail probe or with a bicanalicular stent and silicone tubes. However, monocanicular involvement needs a different approach for its repair. Since these stents are expensive and their use require much surgical experience, a suitable and/or cheaper alternative would be useful in cases where the stent is not available. Here, we present a case report of canalicular reconstruction using an angiocatheter tube as a stent in adult patient which had a satisfactory outcome.

Case report 1

A 34 -year old male presented to our outpatient department following an injury to lower canaliculus of his left eye (OS), caused by a sharp object. On examination, he had an injury to punctum and canaliculus. [Fig. 1]. The anterior segment was normal without any intraocular involvement. A meticulous microscopic repair was done under local anesthesia. A 22 G angiocatheter was used to cannulate the torn canaliculus through the lower punctum. The stellate of the angiocatheter was withdrawn; the plastic tube was left in situ and cut near the punctum parallel to the lid margin to prevent post-operative irritation (Fig. 2 a,b). A fixation suture was passed through the tube and the eyelid skin with a 4/0 silk to prevent its extrusion.

The eye was patched and bandaged. The patient was prescribed with oral and topical antibiotics. The tube was left in situ and the wound was seen to be well approximated on the postoperative day 1. On 1st follow up on postoperative day 7, the tube was in situ (Fig. 3). In the 12th week after the surgery, the tube was removed. The patient had a patent canaliculus on syringing.

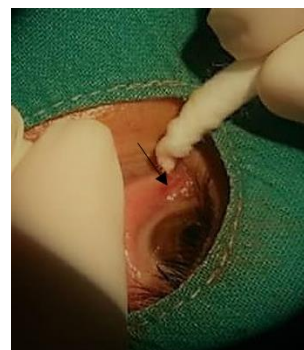

Fig.1: Lower punctum and canalicular laceration

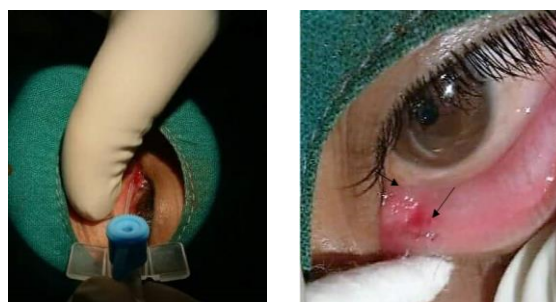

Fig. 2a: A 22-G angiocatheter tube passed; 2b: Plastic tube left in situ and cut through punctum

and canaliculus. near the punctum parallel to the lid margin

Case report 2

A 52-year-old male presented to our outpatient department following an injury in right eye after road traffic accident. On examination, he had an injury to the lower lid involving the lacrimal canal (Fig. 3), a tear in the lower conjunctival fornix, and both medial and lateral canthi laceration.

The eyelid was repaired surgically in layers. The lacrimal canal was repaired using the Teflon sleeve of a 22G Intrabath (Fig. 4). A fixation suture was passed through the tube and the eyelid skin with a 4/0 silk to prevent its extrusion. We located the proximal end of the canal and confirmed it by syringing. Both the canthi were reconstructed. Lower conjunctival fornix was reconstructed. The eye was patched and bandaged. The patient was prescribed with oral and topical antibiotics. The tube was left in situ and the wound was seen to be well approximated on the postoperative day 1. On 1st follow up on postoperative day 7, the tube was in situ. We are waiting further for his follow up visit.

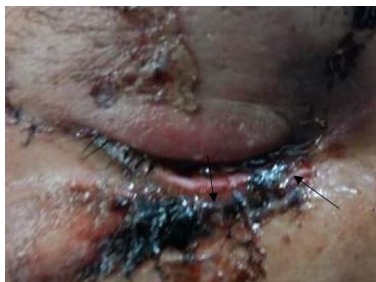

Fig 3. Lower lid with canalicular laceration

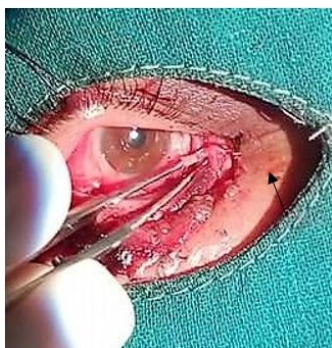


Fig.4 Teflon tube in situ

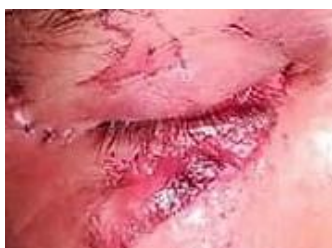

Fig. 5: Post-operative (Day 7) photograph

Discussion

Lacrimal canal lacerations are common in ophthalmic practice, but direct injury to the canal is reported only in 16% to 54%^{1,4} of cases. Variable success rates have been reported for lacrimal canal repair using different techniques, including a pig tail needle² or silicon tube for intubation^{2,3} or a mini-monoka.³

Epiphora is reported to be more common when no canalicular stent is placed at the time of surgical repair. Controversy still exists regarding the repair of a single-lacerated canaliculus. However, considering the predominance of the younger population and the long-term morbidity in the form of eyelid malposition, epiphora, ocular irritation, dermatitis, infection like dacryocystitis, it may be prudent to repair all canalicular lacerations even if a single canaliculus is involved.^{3,5,6}

Early repair and intubation with stents are crucial in achieving a good success rate after the reconstruction of the lacrimal drainage system. Intubation of the canaliculus is crucial for the prevention of stenosis, and repair of the lacrimal drainage system should be performed.⁷ There is no consensus regarding the exact duration for which the canaliculus should remain stented to achieve long-term patency.⁸ Conlon and associates (1994) designed an animal model to study the histology of canalicular lacerations following intubation and concluded that the optimum time for removal of the tube was 12 weeks.

The use of angiocatheter tube for canalicular injury achieved anatomical as well as functional success in our patient. Extrusion of the angiocatheter tube occurs within one month, necessitating close initial follow-up.

Conclusion

The use of an angiocatheter tube as a stent is a simple, efficient, inexpensive and feasible alternative to the use of a silicon tube in the repair of canalicular lacerations in a rural setting.

References

1. Lima-Gómez V, Mora-Pérez E. Lesiones oculares asociadas a heridas palpebrales con y sin afectación de la vía lagrimal. [Ocular lesions associated with lid wounds with or without tear duct affection]. *Cir* 2006;74(1):11–4.
2. Walter WL. The use of the pigtail probe for silicone intubation of the injured canaliculus. *Ophthalmic Surg* 1982;13(6):488–492.
3. Naik MN, Kelapure A, Rath S, Honavar SG. Management of canalicular lacerations: epidemiological aspects and experience with Mini-Monoka monocanicular stent. *Am J Ophthalmol* 2008;145(2):375–80. doi: 10.1016/j.ajo.2007.09.018.
4. Harish AY, Ganesh SC, Narendran K. Traumatic superior oblique tendon rupture. *J AAPOS* 2009;13(5):485–87. doi: 10.1016/j.jaapos.2009.07.005.

5. Herzum H, Holle P, Hintschich C (2001). Eyelid injuries: epidemiological aspects. *Ophthalmology*; 98:1079 –108
6. Reifler DM (1991). Management of canalicular laceration. *Surv Ophthalmol* 36:113–32
7. Sreedhar A, Varghese TA(Dec.2011) Canalicular tear repair. *Kerala Journal of Ophthalmology*; 23 (4) : 342-344
8. Romano PE (1986). Single silicone intubation for repair of single canaliculus laceration. *Ann Ophthalmol* 18:112–13.
9. Conlon MR, Smith KD, Cadera W, Shum D, Allen LH (1994). An animal model studying reconstruction techniques and histopathological changes in repair of canalicular lacerations. *Can J Ophthalmol* 29:3–8.