

THE ANATOMY OF SMILE IN HARYANAVI FEMALES

Garg S^{1,*}, Rathee S.K.², Shelja³

¹Assistant Professor, ²Professor, Dept. of Anatomy, Pt. Bhagwat Dayal Sharma Post Graduate Institute of Medical Sciences, Rohtak, Haryana, India

³Postgraduate student, Dept. of Physiology, Pt. Bhagwat Dayal Sharma Post Graduate Institute of Medical Sciences, Rohtak, Haryana, India

***Corresponding Author:**

Email: vishalksingla@yahoo.com

ABSTRACT

Facial Aesthetics is a primary consideration for the patients seeking prosthodontic and orthodontic treatments. The present study was conducted on 50 females age group 18-25 years in Pt. B.D. Sharma Post graduate institute of Medical Sciences, Rohtak. The photographs were clicked with the digital camera with high resolution. The maximum number of teeth exposed during full smile was 10 in 52% followed by 12-16 in 32%, 8 in 14% and 6 in 2% cases, the midline relationship of central incisors to philtrum was central in 48% followed by right of the center in 44% and left of the center in 8% cases, bilateral negative space was normal in 76% followed by increased space in 24% cases.

Keywords: Smile, Prosthodontic, Orthodontics, Aesthetics

INTRODUCTION

Dentofacial attractiveness is a major determinant of overall physical attractiveness.¹ Individuals mainly focus on other people's eyes and mouths during interpersonal interaction, with little time spent on other facial features.² In the mind of the general public, the smile ranks second only to the eyes as the most important feature in facial attractiveness.³ The anatomy of the smile is an integral part of dentistry. Its understanding involves close scrutiny of all elements of the oral region. Smile should be analyzed from the frontal view to achieve the goals of symmetrically framing the teeth with the lips and harmonizing the teeth, gingiva, negative space, and lips. To create a harmonious smile the dentist must maintain or create the normal curvature of the lips, proper exposure of the red zone of the lips, an undistorted philtrum, and undisturbed nasolabial grooves. The lips are the frame, the teeth are the main subjects, and the gingiva is the background. These entities, maintained in harmony with the exposed teeth, constitute the anatomy of a smile.⁴ In other words, being able to interpret the nuances of a smile gives each orthodontist the opportunity to act in a conscious manner in the mouth aesthetic treatment of their patients, allowing the diagnosis to be integrated with the prognosis and giving a realistic outlook of the results that can be obtained. In order that patients may be served properly, the smile must be understood, recorded, and analyzed so that desirable aspects may be preserved and graceless components returned to attractiveness.

MATERIALS AND METHOD

The study was conducted on 50 females age group 18-25 years in Pt. B.D. Sharma Post graduate institute of Medical Sciences, Rohtak. The methods

and objectives were explained to them and written consent was obtained for willful participation in the study. Following inclusion and exclusion criteria were used for selection of the subjects.

Inclusion criteria: The subjects having full dentition were included. However, the eruption of last molar was ignored in the subject as its eruption is variable and is not a dependable criterion.

Exclusion criteria:

- a) Subjects with deformity, injury, trauma, malformation, surgical scar and congenital abnormalities of the lips were excluded.
- b) Subjects who have migrated into Haryana from other places were excluded.

The photographs were clicked with the digital camera with high resolution. The following parameters of smile were studied.

1) Number of teeth exposed during full smile: The number of teeth displayed in smile was as follows^{5,6}

- I. Six anterior teeth exposed (canine to canine)
- II. Eight anterior teeth exposed (Six anterior teeth and first premolar)
- III. Ten anterior teeth exposed (Six anterior teeth, first and second premolar)
- IV. Twelve-sixteen anterior teeth exposed (Six anterior teeth, first and second premolar, and first molar)

2) Midline Relation of central incisors to philtrum

[fig. 1]: A midline is an imaginary line that runs from the midpoint of the nose base, and through philtrum or the midpoint of the arch in the upper lip through the center of central incisors. It may pass right or left

of central incisor.⁵To attain optimal aesthetics, the facial midline must coincide with the maxillary and mandibular central incisor midline. A properly placed midline in conjunction with a long solid interproximal contact relationship between two central incisors produces a desirable effect of “cohesiveness” of the dental composition. The facial midline is a critical reference position for determining multiple design criteria, in orthodontic treatment planning,⁷ as it is an important functional component of occlusion.⁸

3) Bilateral negative space(BCs)[Fig.2]: As the smile expands, the lips separate, the commissures curve upwards, and the teeth are exposed.¹² Buccal corridors or the negative space is the space created between the buccal surface of the posterior teeth and lip corners when the patient smiles.⁹ As small BCs make a smile more attractive, orthodontic expansion has been proposed to improve smile attractiveness.¹⁰This smile feature has been thought of primarily in terms of maxillary width, but there is evidence that the buccal corridors are also heavily influenced by the anteroposterior position of the maxilla relative to the lip drape.¹¹

RESULTS

The result of this experiment showed the following characteristics of smile in Haryanavis (Table 1):

- I. The center midline relation of central incisors to philtrum was maximum followed by midline passing through right of center while it was rarely passing through left side of the philtrum.
- II. The number of teeth exposed during full smile was 10 teeth(Six anterior teeth, first and second premolar) in 52% cases followed by 12 teeth in 32% cases.
- III. The Bilateral negative space was normal in 76% cases followed by increased space in 24% cases.

DISCUSSION

In the present study, the most common midline relationship of central incisors to philtrum was centrally placed (48%) followed by right of the center(44%) and left of the center(8%)[Table 2].In North –Indian females about more than 3/4th females have central relation of central incisors to philtrum while in Haryanavi females this percentage is less than 50% cases. The harmonious relationship of central incisors with the philtrum imparts a desirable effect of “oneness” of dental composition to the smile of Haryanavis.

In the present study, maximum number of teeth exposed during full smile was 10 (52%) followed by 12-16 in 32%, 8 teeth in 14% and 6 teeth in 2% cases[Table 3]. Our study did not follow the trend with Tjan et al ⁶ study conducted in American

population .He reported that maximum number of teeth exposed were 8 in 48.6% followed by 10 teeth (40.65%)and 12-16 teeth in 3.74% cases. The study on North Indian population conducted by Patnaik &Goel ¹²showed that maximum number of teeth exposed during full smile was 8 in 69.67% followed by 6 in 21.29% and 10 teeth in 9.03% cases. The different results of the above studies could be explained on genetic basis.

Sabri reported that those young subjects displaying the first molars during full smile were ranked highest esthetically. Only 80% of the maxillary incisor was exposed on smile, and with further maturation and aging, this amount was expected to decrease.¹³ Therefore, the lack of incisor show was considered both an initial esthetic problem and a long-term problem because it was expected to worsen with further growth and maturation.

The present study revealed that the bilateral negative space was normal in 76% cases and increased in 24% cases[Table4]. The bilateral negative space was normal in 93.54% cases in the study on north Indian females by Patnaik &Goel.¹² Importantly, Moore et al provided the data regarding smile. He demonstrates that broader smiles with no buccal corridors(BCs) are more attractive than smiles with BCs. This indicates that both orthodontists and laypeople prefer smiles with no or small BCs over those with large BCs.¹⁴ This is in agreement with the opinion of Sarver and Ackerman¹⁰ that small BCs are more attractive. But, the orthodontist’s eye for beauty is an important factor in creating appropriately sized buccal corridors.

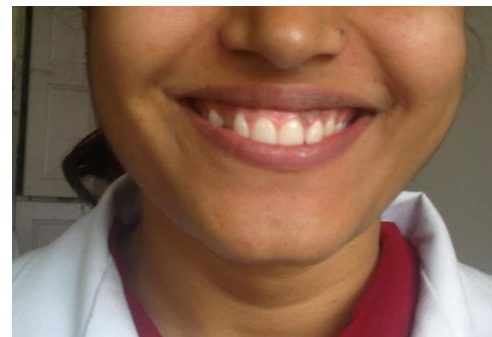

Fig. 1(a): Philtrum passing through center

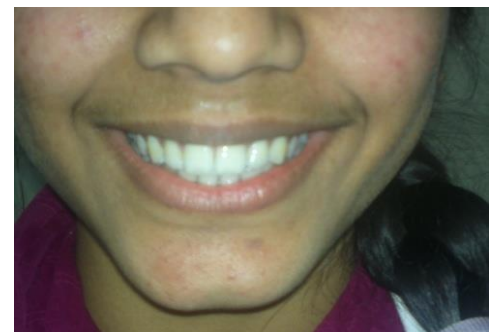


Fig. 1(b): Philtrum passing through right

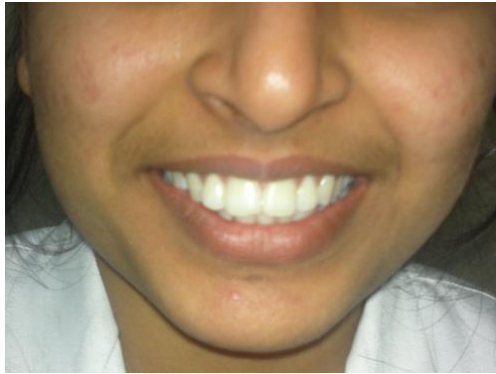

Fig. 1(c): Philtrum passing through left

Fig. 1: Showing Midline Relation of central incisors to philtrum

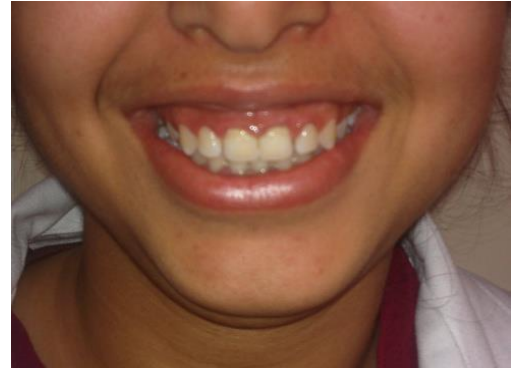

Fig. 2(b) Increased Bilateral negative space

Fig. 2: Showing Bilateral negative space

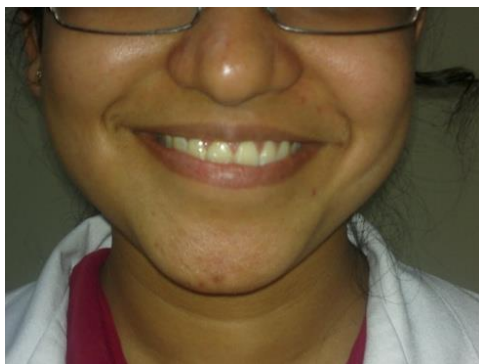


Fig. 2(a): Normal Bilateral negative space

Table 1: Showing percentage frequency of different parameters of smile in Haryanavi females

Parameters	Positions	Number	Percentage
Midline relation of central incisors to philtrum	Center	24	48%
	Right of Center	22	44%
	Left of Center	4	8%
Number of Teeth exposed during full smile	6	1	2%
	8	7	14%
	10	26	52%
	12	16	32%
Bilateral negative space	Normal	38	76%
	Increase	12	24%

Table 2: Showing comparison of midline relationship of central incisors to philtrum in North-Indian and Haryanavi females

Midline Relation of central incisors to philtrum				
Authors	Region	Midline Relation		
		Center	Right of center	Left of center
Patnaik& Goel (2010) ¹²	North India	76.77%	1.29%	21.93%
Present Study(2013)	Haryana	48%	44%	8%

Table 3: Showing number of teeth exposed during full smile in different studies

Number of teeth exposed during full smile					
Authors	Region	Number of teeth exposed during full smile			
		6	8	10	12-16
Tjan et al(1984) ⁶	California(USA)	7.01%	48.6%	40.65%	3.74
Patnaik&Goel(2010) ¹²	North India	21.29%	69.67%	9.03%	—
Present Study	Haryana	2%	14%	52%	32%

Table 4: Showing Bilateral negative space in North-Indian and Haryanavi females

Bilateral negative space			
Authors	Region	Space	
		Normal	Increase
Patnaik & Goel (2010) ¹²	North India	93.54%	6.46%
Present Study(2013)	Haryana	76%	24%

CONCLUSIONS

The smile is one of the most important facial expressions and should be carefully analyzed as a whole before the accomplishment of dental treatment, aiming to establish the harmony between the teeth

and adjacent soft tissues, achieving an esthetic and pleasant smile.¹⁵ Evaluation of the face should be conducted together with the intraoral examination for the establishment of treatment goals that may meet the patient's expectations and reestablish the most

esthetic conditions as possible. ¹⁶People with normal dental appearance are judged socially more attractive over than those with malocclusions. An attractive smile has always been the focal point of a person's attention to improving esthetic appearance and thus self-esteem. Therefore, it is essential that the clinician has a comprehensive knowledge of the elements and basic principles of aesthetics and the specific characteristics of the individual's teeth. This study may provide useful data which may allow the orthodontist to systematically and consistently deliver high-quality, stable results with beautiful smiles in Haryanavi females. The present study is a baseline data for normalcy of an esthetic smile in Haryanavi females.

REFERENCES

1. Jenny J, Cons NC, Kohout FJ, Jacobsen JR. Relationship between dental aesthetics and attributions of self-confidence. *J Dent Res* 1990; 69:pp204.
2. Miller AG. Role of physical attractiveness in impression formation. *Psych Sci* 1970; 19:pp241-243.
3. Goldstein RE. Study of need for aesthetics in dentistry. *J Prosthet Dent* 1969;21:pp589-598.
4. Matthews TG. The anatomy of a smile. *J Prosthet Dent* 1978 Feb; 39(2):pp128-34.
5. Patnaik VVG, Singla RK, Bala S. Anatomy of A Beautiful face and smile. *J Anat Soc India* 2003;52(1):pp74-80.
6. Tjan AHL, Dent Dr, Millar CD, The JGP: Some esthetic factors of smile. *J Prosthet Dent* 1984; 51:pp24-8.
7. Beyer JW, Lindauer SJ. Evaluation of dental midline position. *Seminars in Orthodontics* Sept 1998;4(3):pp146-52.
8. Thomas JL, Hayes C, Zawaideh S. The effect of axial midline angulation on dental aesthetics. *Angle Orthod* 2003;73:pp359-64.
9. Levin EI. Dental aesthetics and the golden proportion. *J Prosthet Dent* 1978;40:pp244-52.
10. Sarver DM, Ackerman MB. Dynamic smile visualization and quantification: Part 2. Smile analysis and treatment strategies. *Am J Orthod Dentofacial Orthop* 2003; 124:pp116-127.
11. Sarver DM. The face as determinant of treatment choice. In: *Frontiers of dental and facial aesthetics. Craniofacial Growth Series, Center for Human Growth and Development. Ann Arbor: University of Michigan; 2001. Vol 38, p. 19-54.*
12. Patnaik VVG, Goel A. Lip Morphometry and Dentofacial Analysis Based Data for Personal Identification and Forensic Significance. *J Indo-Pacific Acad of Forensic Odont* 2010;1:pp5-11.
13. Sabri R. The eight components of a balance smile. *JCO* 2005;39(3):pp155-67.
14. Moore T, Southard KA, Casco JS, Qian F, Southard TE. Buccal corridors and smile aesthetics. *Am J Orthod Dentofacial Orthop* 2005;127:pp208-13.
15. C M Hulsey. "An esthetic evaluation of lip-teeth relationships present in the smile". *Am J Orthod* 1970; 57(2):pp132-44.
16. MR Mack. "Perspective of facial aesthetics in dental treatment planning." *J Prosthet Dent* 1996; 75(2), pp169-76.