

### A RARE CASE OF LARGE PARATUBAL CYST - A DIAGNOSTIC DILEMMA

Neelima Agarwal<sup>1,\*</sup>, Manisha Gupta<sup>2</sup>, Amita Sharma<sup>3</sup>, Alpana Agarwal<sup>4</sup>

<sup>1,3,4</sup>Professor, <sup>2</sup>Associate Professor, Department of Obst & Gynaecology,  
Santosh Medical College & Hospital, Ghaziabad

**\*Corresponding author:**

E-mail: agarwalneelima2@gmail.com

---

#### ABSTRACT:

*Cysts near the ovary are derived from anomalies of the fallopian tubes or the broad ligament. The paramesonephric types consist of ciliated cells similar to the oviduct epithelium. The mesonephric types consist of an epithelium with minimal surface structures. They can be found on the thin oviduct (paratubal cysts) or near its fimbriated end (hydatid of Morgagni). Small paratubal cysts are frequent incidental findings during gynecological surgery and are often confused with ovarian tumors. Most reported cases of paratubal cysts have occurred in pediatric patients, and this type of cyst rarely causes symptoms of lower abdominal pain mimicking appendicitis. However some of them may attain large size and lead to pain, torsion, and rupture and give a diagnostic dilemma. We present a rare case of paratubal cyst of much larger dimensions than usual presentation.*

**Key words:** Paratubal cyst, paraovarian cyst, hydatid of Morgagni

---

#### INTRODUCTION

Paratubal cysts represent remnants of the paramesonephric or mesonephric ducts, the former being more common. They are generally known as 'Hydatid cyst of Morgagni' and are small, round, blind cysts attached by a pedicle to the fimbriated end of the fallopian tube.<sup>1,2</sup>

#### CASE REPORT

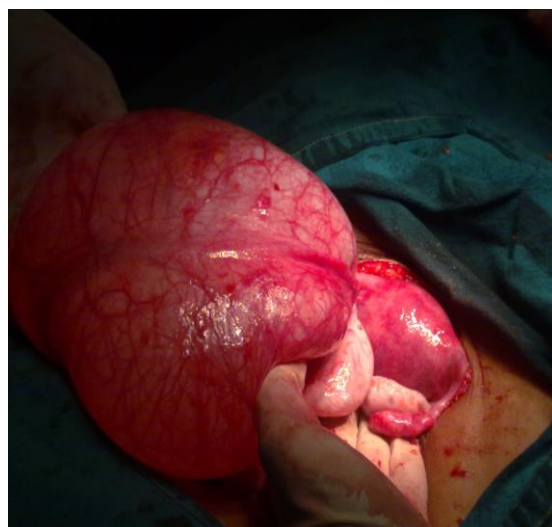A 20 years old female, came to gynecology OPD with history of pain in lower abdomen for 2 months, more since 4-5 days. There was no history of colicky pain, fainting attacks, vomiting or other gastrointestinal disturbances. Her bowel and bladder habits were normal. She was married for 5 months and was nulligravida. Her menstrual cycles were regular, 3-4 days /30 days, moderate flow and were not associated with dysmenorrhea. Her last menstrual period was 15 days back and had a normal flow.

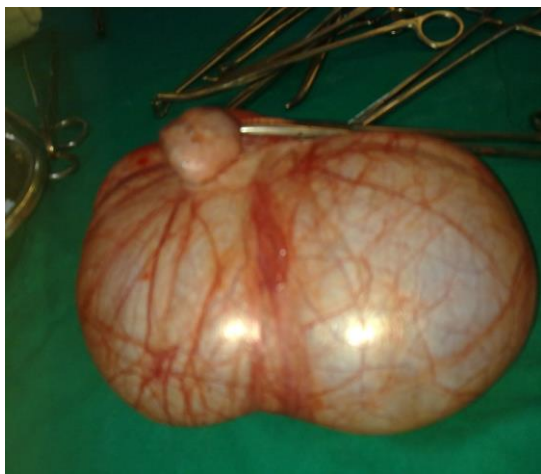
There was history of receiving ATT 11 yrs back for pulmonary koch's for 1 year. On examination, she was thin built, and her vitals were stable. Per abdominally, there was a soft cystic lump reaching up to umbilicus, dull on percussion, and no fluid thrill. On per vaginum examination uterus was retroverted normal size and bilateral fornices were free. Cyst could not be felt vaginally. Patient's ultrasound was done on the same day which revealed a large well defined thin walled cystic lesion with echo free contents extending from pelvis to supraumbilical region of 15x12x7 cms, volume 665 cc. Both ovaries were poorly visualized. Diagnosis of? Mesenteric cyst? ovarian cyst was made.

Patient was put on injectable antibiotics; a surgical reference was taken, but since no definite diagnosis could be reached, she was advised CT scan. CT scan showed the large cystic mass as seen on ultrasound. But both ovaries were seen as normal,

uterus was also normal. Her FNAC was taken; histopathology showed no malignant cells, and findings suggestive of? Dermoid cyst of ovary. With a diagnostic dilemma between a mesenteric cyst and an ovarian cyst, the decision of laparotomy was taken, since malignancy had already been excluded on FNAC.

Abdomen was opened by vertical incision. Uterus and both the ovaries and tubes were normal. A large cyst appx. 15x12x5 cms was seen attached to the left fallopian tube. Left sided fimbrial end was seen separately.





**Fig. 1 and fig. 2: Paratubal cyst measuring 15 x12 x5 cm has been delivered out. Left tube is seen stretched over the cyst. The left ovary is seen separately.**

Since cystectomy was not possible, left sided salpingo-oophorectomy along with the cyst removal was done. Care was taken to avoid the rupture of the cyst during surgery. Histopathology of the cyst confirmed the diagnosis of paratubal cyst. Patient's post operative period was uneventful, and was discharged on 8<sup>th</sup> day. There was no effect on the fertility of the patient, as she conceived within three months of the surgery.

## DISCUSSION

Paratubal cysts are frequent incidental findings during gynecological surgeries for other abnormalities, or are found on sonographic examination. Most of these cysts are asymptomatic, and slow growing and are discovered in 3<sup>rd</sup> and 4<sup>th</sup> decade of life.<sup>3</sup> Extremes of the sizes have been noted, but most measure less than 3 cms.

The reported incidence of para adnexal cyst [para tubal and paraovarian cysts] varies, but a recent autopsy series cited a rate of 5% of adnexal cysts.<sup>4</sup> No certain risk factors have been found with their formation, although some have reported them to be more common following in-utero exposure to DES [diethyl stilbestrol].<sup>2</sup>

They are generally not detected on pelvic examination. Rarely if they grow large enough symptoms may develop, which mimic those of any other ovarian pathology, such as pelvic or abdominal pain or increasing girth. Such cases are frequently associated with torsion, hemorrhage or rupture.<sup>4</sup> Most cysts have thin smooth walls and anechoic centers. Eccentrically located cysts may resemble hydrosalpinx. Sonography and MR imaging is not helpful in differentiating between ovarian, paraovarian & paratubal cysts.<sup>5,6</sup> Thus many women may be managed similarly as for the diagnosis of ovarian cyst.

## CONCLUSION

Paratubal cysts are very difficult to diagnose with sonography, therefore their management should be approached as any other adnexal mass. However rupture or puncture of masses should be avoided when possible, to prevent potential tumour dissemination in the event of a malignancy, as cases of endometrioid tumour of variable malignant potential has been noted arising in paratubal cysts.<sup>2,7</sup>

## REFERENCE:

1. Moyle PL, Yataoke MY, Nakai A et al: Nonovarian cystic lesions of the pelvis. *Radiographics* 2010; 30:921-938.
2. Charbel Salmon, Carmen Tornos et al: Borderline endometrioid tumor arising in a paratubal cyst. *Gynaecologic oncology*; April 2005; 97(1): 263-265.
3. Atef M. Darwish, Ahmed F.Amin et al. Laparoscopic management of paratubal and paraovarian cyst. *JLSLS*, april-june 2003; 7(2): 101-106.
4. Lurie S, Golan A, Glazerman M. Adnexal torsion with a paraovarian cyst in a teenage girl. *J Am Assoc Gynecol Laparosc* 2001; 8:597-9.
5. Lazarov N, Lazarov L, Angelova M. Paraovarian cyst in an 18 year old patient. *Akus Ginekol* 2000; 40-50.
6. Oelsner G, Bider D, Goldenberg M et al. Long-term follow up of twisted ischemic adnexa managed by detorsion. *Fertil Steril* 1996; 60:976-9.
7. Korbin CD, Brown DL, Welch WR. Paraovarian cystadenomas andcystadenofibromas: sonographic characteristics in 14 cases. *Radiology*1998; 208:459-62.