

Metastatic breast carcinoma involving the thyroid gland: A rare case report and literature review

Litake MM¹, Moger J², Parasnis A³

Abstract:

Being a rare site of metastasis, breast carcinoma metastasis to thyroid is rare. Presenting herewith a case of carcinoma breast operated one year ago in a 65 year old woman with negative for ER/PR and HER-2-neu status. She presented a year later after postoperative chemo-radiotherapy to our hospital with thyroid swellings and cervical lymphadenopathy. PET scan revealed spinal metastasis in thoracolumbar segments and suspicious thyroid malignancy. Ultrasonography of the neck was suspicious of thyroid neoplasia. Histo-pathological examination of total thyroidectomy revealed metastatic invasive ductal carcinoma of breast and immunohistochemistry was positive for GCDPF-15 and negative for thyroglobulin and TTF-1.

¹Associate Professor

²Chief Resident, General Surgery, ³Associate Professor B.J. Government Medical College, Pune
manjusha_litake@hotmail.com

Keywords: GCDPF-15 (Gross cystic disease fluid protein-15), TTF-1 (Thyroid transcription factor-1), Breast carcinoma.

Introduction:

Being a common carcinoma in females, breast carcinoma is a leading cause of death (1). Irrespective of early detection due to mammography screening, distant metastasis or local recurrences are seen in many, even after completion of treatment. Liver, lungs, brain, and bone are the common metastatic sites for carcinoma breast but the incidence of metastasis of carcinoma breast to the thyroid is relatively rare (2). Only 2%–3% of all malignant tumours of the thyroid are metastatic even though the thyroid gland is highly vascular (3). However, incidence of thyroid metastasis ranges from 1.25 % to 24% in various autopsy series (4). Breast, lung and renal cell carcinoma are the common primary malignancies that metastasise to the thyroid (5).

Case History:

The patient, a 65-year-old female, underwent modified radical mastectomy for left breast carcinoma in August 2013. On histopathological examination, it came out to be invasive ductal carcinoma. The primary tumour was 36x22x22 mm in size and two axillary lymph nodes in the specimen showed tumour deposit with perinodal extension. Immunohistochemically, the tumour was negative for ER, PR and HER-2-neu. The patient then underwent adjuvant chemotherapy and radiotherapy and was followed up every six monthly. Patient was free of symptoms for 12 months after which she presented to our hospital in the month of November 2014 with 2 thyroid swellings on left side and level 1B cervical lymphadenopathy on right side. PET scan of the

patient done in the month of November 2014 showed spine metastasis in thoracolumbar segments, mediastinal lymph nodes and suspicious thyroid malignancy.



Fig.1: PET scan showing multiple metastasis

Ultrasonography of the thyroid gland was also showing suspicious neoplastic lesions & FNA was positive for malignancy. Thyroid function test results were found to be normal. Thus a total thyroidectomy was performed with right submandibular lymph node excision and the specimen was sent for histopathological analysis.

Histological examination of the thyroid specimen revealed multiple foci of metastatic invasive duct carcinoma breast which was confirmed by immunohistochemical studies. The pleomorphic tumor cells,

arranged in nests, intermingled with the thyroid follicles. They displayed moderate anisokaryosis and nuclear hyperchromasia. Foci of coagulative tumor necrosis were also noted. Surrounding normal thyroid parenchyma was also identified.

Tumor cells in the metastatic foci were also expressed negative staining for ER, PR and Her-2-neu, similar to the staining pattern of primary breast lesion. These were, however, positive for GCDPF-15 thus confirming their origin from breast. Furthermore, the metastatic cells were negative for thyroglobulin and TTF-1, both of which were positive in the surrounding normal thyroid parenchyma, suggestive of that the neoplastic cells did not originate from the thyroid gland.

HPE IMAGES

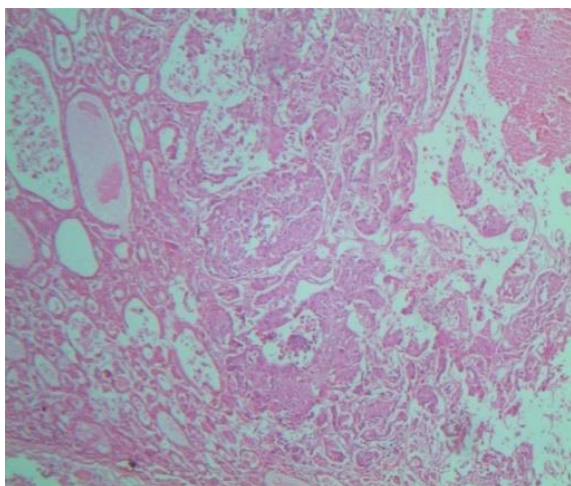


Fig.2: H & E staining low power

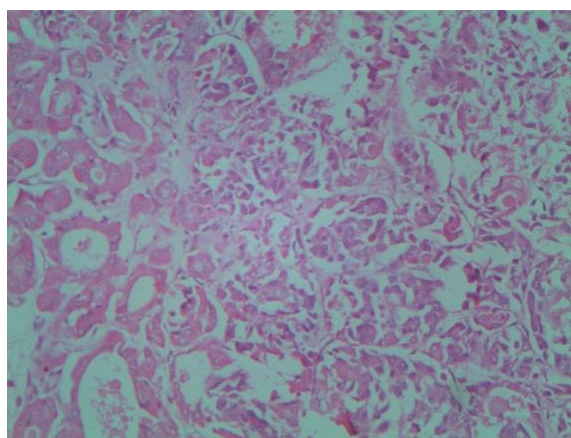


Fig. 3: H & E staining high power

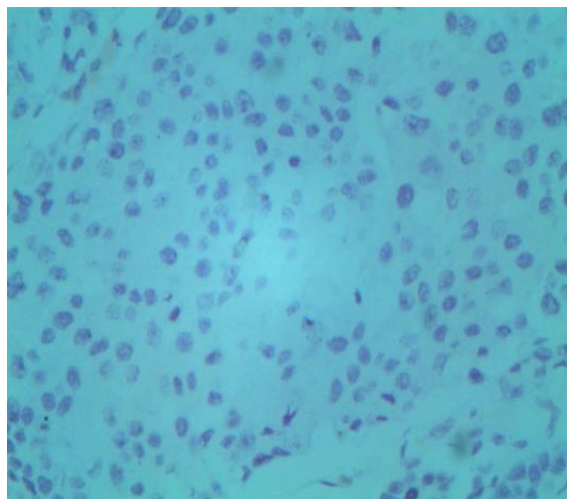


Fig.4: ER negative

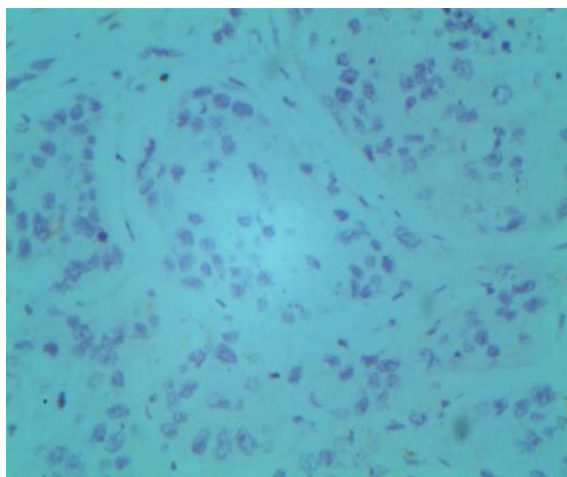


Fig.5: PR negative

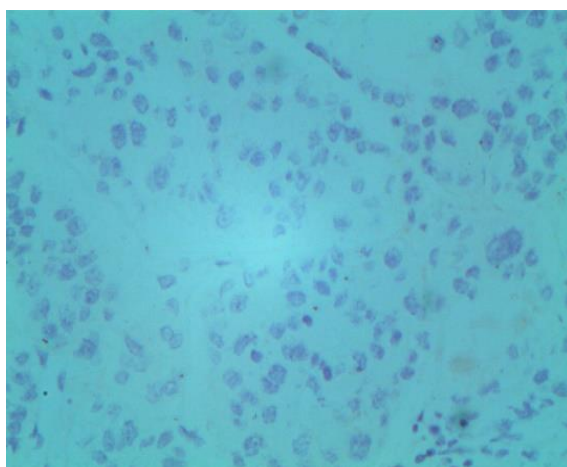


Fig.6: HER 2 neu negative

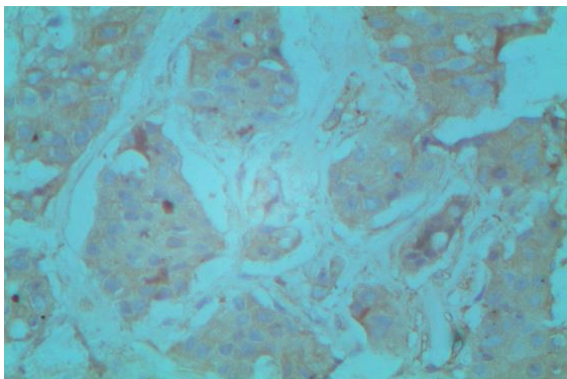


Fig.7: Thyroglobulin negative in tumour tissue

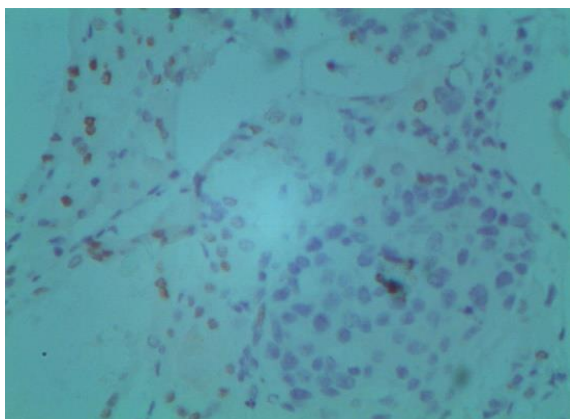


Fig.8: TTF 1 negative in tumour tissue

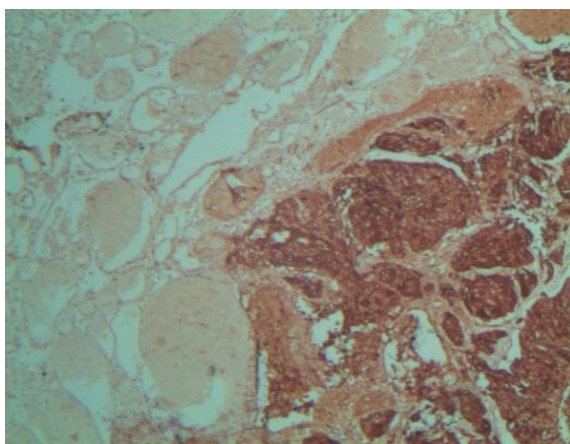


Fig.9: GCDFP-15 positive in tumor tissue

(Fig.2 low power (H&E) and Fig.3 High power (H&E) view showing metastatic duct carcinoma of breast infiltrating into the thyroid parenchyma.)

(Fig 4, Fig 5 and Fig 6 showing tumour cells negative for ER, PR and Her-2-neu respectively.)

(Fig. 7 & Fig.8 showing thyroglobulin and thyroid transcription factor negative in the tumour tissue which is positive in the surrounding thyroid parenchyma respectively.)

(Fig. 9 showing positivity for GCDFP-15 in the tumor cells which is negative in the surrounding thyroid parenchyma.)

Discussion:

This study presents a rare case of metastatic breast carcinoma disseminated to the thyroid gland. In various autopsy series, the rate of occurrence of thyroid metastasis has been found to be less than 24%. Thyroid gland is an uncommon site for clinically visible metastasis from non-thyroid malignancy, especially from the breast. Prognosis and the likelihood of cure of thyroid lesion depend on its diagnosis. The treatment modality for metastatic breast carcinoma to thyroid gland is different from that of primary thyroid malignancy. Therefore a diagnosis of metastatic thyroid lesion in a patient with previous history of breast carcinoma should be considered unless and until it is ruled out histologically.

About 33% of breast cancer patients will have blood metastasis to the lungs, liver, bone, and gastrointestinal tract in their lifetime. There is well established correlation between estrogen-progesterone receptor status of breast cancer and the site of metastasis. Estrogen receptor positive have more affinity for thyroid and parathyroid glands, while progesterone receptor cases have more affinity towards myocardium, urinary tract and gastrointestinal epithelium for metastasis (6). In this case, the status for estrogen receptor and progesterone receptor was found to be negative. The uncommonness of thyroid metastasis is thought to be due to unknown, immunological mechanisms (7).

The site of primary cancer dictates the survival in case of metastatic thyroid disease. Although there are no clinically proven survival benefits after thyroidectomy in thyroid metastatic disease, in cases with no metastasis to other organs except thyroid, early diagnosis and radical treatment in the form of thyroidectomy seems to improve survival (8). However, primary cancer metastasising to thyroid indicates systemic dissemination with dismal prognosis (9).

In the reported case, the diagnosis of metastatic breast carcinoma to thyroid was confirmed with the help of histopathology and immunohistochemistry. Immunohistochemistry was particularly helpful in differentiating the metastatic breast carcinoma from primary thyroid malignancy. Thyroglobulin and TTF-1 are the tumour markers that are positive in tumours of thyroid follicular epithelial cells. In our case both these markers were found to be negative in the tumour cells but strongly positive in the surrounding normal thyroid parenchyma. Furthermore, the tumour cells were strongly positive for GCDFP-15 which confirmed their origin from a breast lesion (10). Hormonal status (ER and PR) and Her2neu status

were found to be negative in the metastatic tumour similar to the expression pattern of the primary breast carcinoma.

Conclusion:

Our present report emphasises the need of clinical vigilance for detection of metastatic disease to thyroid especially when associated with a previous history of malignancy and the need for liberal use of immunohistochemistry analysis to confirm the diagnosis of the same.

References

1. WHO. Breast cancer: Prevention and control 2012.
2. Rosen IB, Walfish PG, Bain J, Bedard YC. Secondary malignancy of the thyroid gland and its management. *Ann Surg Oncol*. 1995;2:252-256.
3. Cichoń S, Anielski R, Konturek A, Barczyński M, Cichoń W. Metastases to the thyroid gland: seventeen cases operated on in a single clinical centre. *Langenbecks Arch Surg* 2006 Nov;391(6):581-7.
4. Liang HH, Wu CH, Tam KW, Chai CY, Lin SE, Chen SC. Thyroid metastasis in a patient with hepatocellular carcinoma: case report and review of literature. *World J Surg Oncol* 2007 Dec 24;5:144.
5. Gandhi A, Banerjee SS, Bhatti WA, El-Tereifi H, Bundred NJ. Carcinoma of the breast presenting as a thyroid mass. *Eur J Surg* 1997;163:871-873.
6. De la Monte SM, Hutchins GM, Moore GW. Estrogen and progesterone receptors in prediction of metastatic behaviour of breast carcinoma. *Am J Med* 1984;76:11-17.
7. Czech JM, Lichtor TR, Carney JA, van Heerden JA. Neoplasms metastatic to the thyroid gland. *Surg Gynecol Obstet* 1982;155:503-505.
8. Nakhjavani MK, Gharib H, Goellner JR, van Heerden JA. Metastasis to the thyroid gland. A report of 43 cases. *Cancer* 1997;79:574-578.
9. Owens CL, Basaria S, Nicol TL. Metastatic breast carcinoma involving the thyroid gland diagnosed by fine needle aspiration: a case report. *Diagn Cytopathol* 2005 Aug;33(2):110-5.
10. Mazoujian G, Bodin C, Haagensen Jr DE, Haagensen CD. Expression of GCDFP-15 in breast carcinomas. Relationship to pathologic and clinical factors. *Cancers* 1089;63:2516-2561.