

An innovative approach to salvage a fractured endodontically treated tooth – A case report of resection, regeneration and restoration

Vignesh Chandrashekar¹, Harinath Parthasarathy^{2,*}, Anupama Tadealli³, Deepa Ponnaiyan⁴

¹Post graduate student, ²Professor, ^{3,4}Professor, ¹⁻⁴Dept. of Periodontics and Oral Implantology, SRM Dental College and Hospital Ramapuram, Chennai, India

***Corresponding Author: Harinath Parthasarathy**

Email: drvignesh0508@gmail.com

Abstract

Introduction: The progressing inflammatory periodontal disease, if untreated, results in attachment loss. This can affect the furcation region of multirooted teeth. Hemisection is the splitting of two rooted tooth into two separate portions accompanying crown portion of two-rooted teeth most likely mandibular molars. In the healing phase after hemisection, alveolar bone undergoes additional atrophy as a result of the natural remodelling process. Post-extraction Alveolar Ridge resorption may have an impact on dental implant placement, since sufficient vertical and horizontal volume of alveolar bone should ideally be present at the site of insertion. Alveolar ridge preservation (ARP) procedures have been introduced for aesthetic concern, as well as to prevent alveolar ridge atrophy and maintain adequate dimensions of bone in order to facilitate implant placement in prosthetically driven positions.

Case Description: A 51 years old systemically healthy male patient came with a chief complaint of pain and swelling in his lower left back tooth region. On clinical examination, Endodontically treated mandibular first molar manifested bucco-lingual fracture, grade 2 mobility of mesial component, 10 mm probing depth in mesial region and grade 3 furcation involvement. The treatment of the tooth included proposed hemisection of the mesial component followed by socket augmentation and delayed implant placement. After phase 1 therapy, hemisection was performed and mesial root socket was augmented with xenograft and PRF membrane. After 8 months, Osteotomy site was prepared with flapless procedure then narrow, two piece implant of size 3.3 × 11.5 mm was placed in hemisected region of mandibular molar which was followed by provisional restoration at 3 weeks.

Conclusion: An innovative approach for a periodontally compromised fractured endodontically treated tooth which was undertaken with a definitive treatment.

Keywords: Early loading, Furcation, Hemisection, Mandibular first molar, Socket preservation.

Introduction

Bony lesions of the periodontium that do not originate from either periodontal or pulpal pathosis will be deep coronal fractures, vertical root fractures, and palatal groove and other lesions.¹ In these cases, the treatment options will be total removal of the tooth or partial resection of the root with or without crown. According to Weine, in cases with severe coronal destruction involving floor of the pulp chamber, one of the treatment options is hemisection. The terms 'hemi-section' and 'root amputation' are known collectively called as 'root resection'.² Hemisection refers to sectioning of a molar into two halves followed by removal of the diseased root and its coronal portion. The retained root is endodontically treated and restored with an extra-coronal restoration. After removal or resection, the need for restoration is mandatory and for restoration, the need for regeneration or not plays a vital role. Restoration part consists of removable, fixed bridge, implant according to clinical conditions, patient's need and compliance.³

Case Presentation

A 49 years-old male patient reported to the Department of Periodontics and oral implantology with chief complaint of pain and food lodgement in broken lower left back tooth region, for which he had undergone root canal treatment around an four years ago without undergoing subsequent crown prosthesis. The medical history was non-contributory. On intraoral examination, the broken mandibular left first molar was evident involving the

furcation area. On radiographic examination, a bone loss was seen in mesial root of the tooth till periapical region. Hence the tooth was resulted with post endodontic fracture with periodontitis with radiographic evidence of bone loss in the mesial root. Considering the age, awareness and also noncompliance of the patient for extraction, it was planned to save the tooth rather than extracting it. Hemisection of mesial root was planned followed by socket preservation. Placement of implant in the preserved socket of mesial root of 36 was considered as a better treatment option to be followed by placement of a porcelain fused to metal crown. The treatment plan was explained to the patient and a written consent was obtained. The following interdisciplinary treatment protocol was then carried out.

Case Management

Hemisection

Phase 1 therapy addressed towards elimination of local factors. The patient was on strict oral hygiene protocols. After one week of phase 1 therapy, Under LA Localised surgical management done by raising flap in relation to 36. The crown of 36 was sectioned at the level of furcation using high speed handpiece and tapering fissure 13 bur. The hemisected mesial crown and root was removed with a tweezers. A finishing bur was used to smooth on the margins of the remaining structure and occlusal adjustments was made to redirect the forces along the long axis of the distal root.

Socket Preservation

After Hemisection of mesial component, Curettage of mesial socket was done. Thorough irrigation with sterile saline was done to clear the remnants. Then, Socket preservation was done by grafting the extraction site with DMBM= Dimineralized bone matrix * and covered with PRF to induce the bone formation and to prevent the collapse of the soft tissue in to the socket. The flap was approximated, simple interrupted sutures were placed using 3/0 vicryl sutures#. The surgical site was covered with a periodontal dressing\$. Postoperative instructions educated and medications prescribed. Review was done at 1,2,4 weeks following surgery, Extraction socket was covered completely by approximation of flaps, epithelial attachment has taken place and no more periodontal pocket was evident.

* = (OSSEOGRAFT, advance biotech products (p) ltd. Tamilnadu, india)

= (Ethicon, Division of Johnson & Johnson Ltd., Aurangabad, India)

\$ = (coe-pack™ GC America INC. ALSIP, IL, USA)

Implant

Patient was under follow up. Review done in 1, 2, 4 weeks after hemisection. Radiographic socket fill seen after 8 months and then planned for implant placement. Preoperative radiographs taken, casts prepared. According to patients bone availability and related an anatomical landmarks, Implant size is determined as 3.35 * 11.5 mm *

Under LA in 36 region. Without flap elevation, pilot drill placed. Osteotomy done in sequential drill protocol. Followed by Implant placement, healing abutment placed. After 3 weeks healing abutment removed. Impressions taken for restoration. Two separate final restoration were given for implant and the distal component of 36. Follow up of one year with restoration was done with periodic reviews at the interval of 3, 6, 9 and 12 months.

* = (ADIN IMPLANTS).

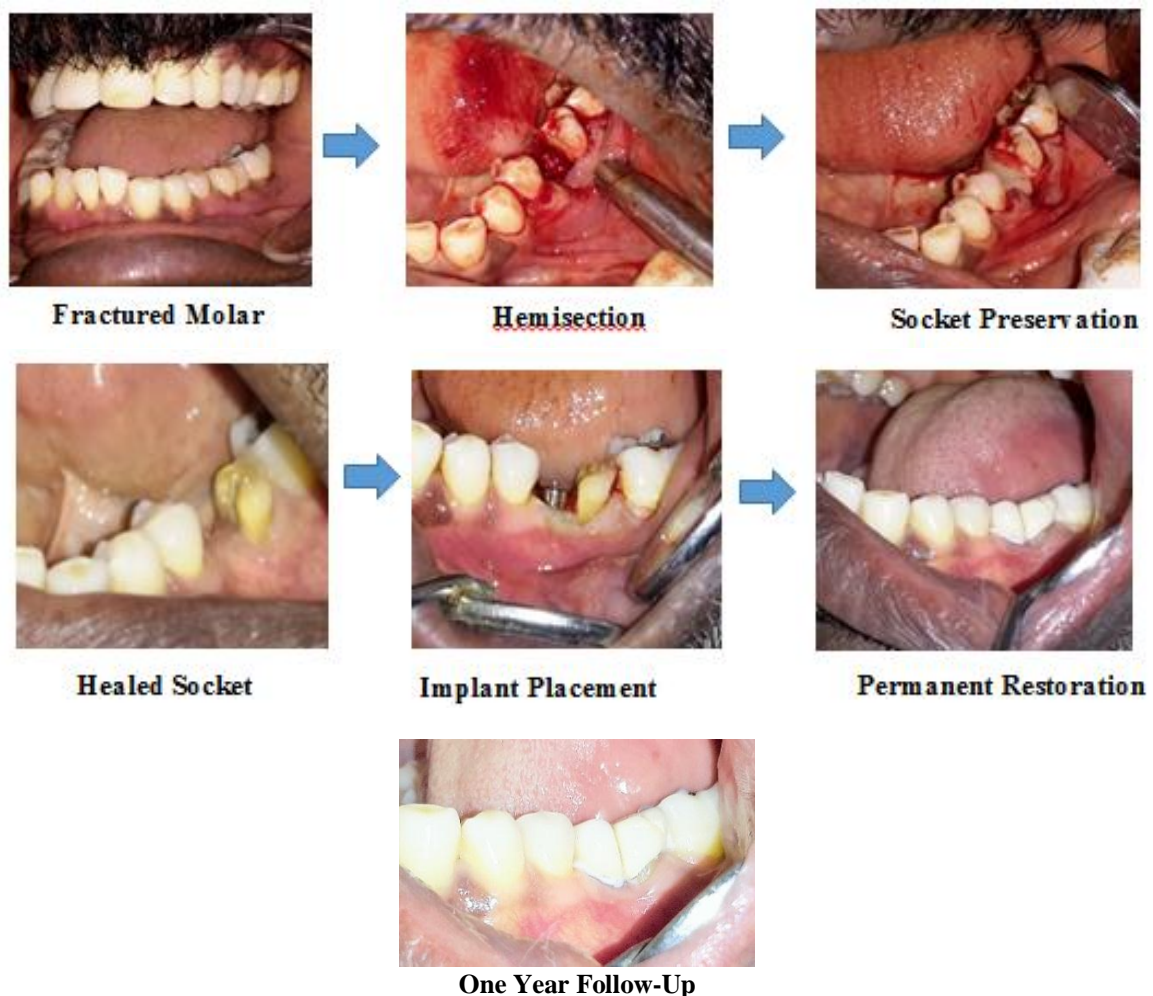
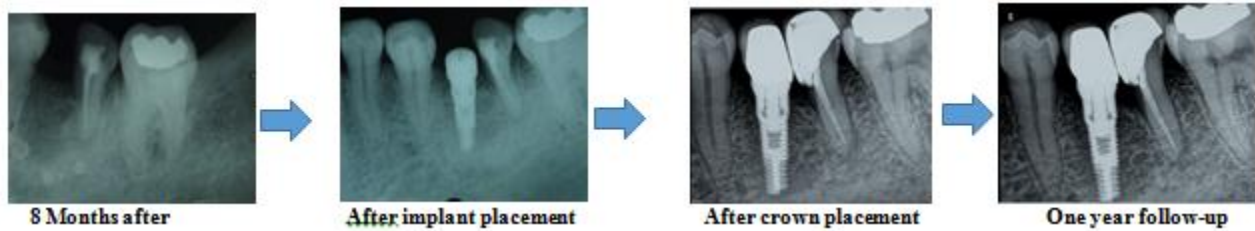
Fig. 1: Clinical Representation



Socket Preservation

Fig. 2: Radiographic representation

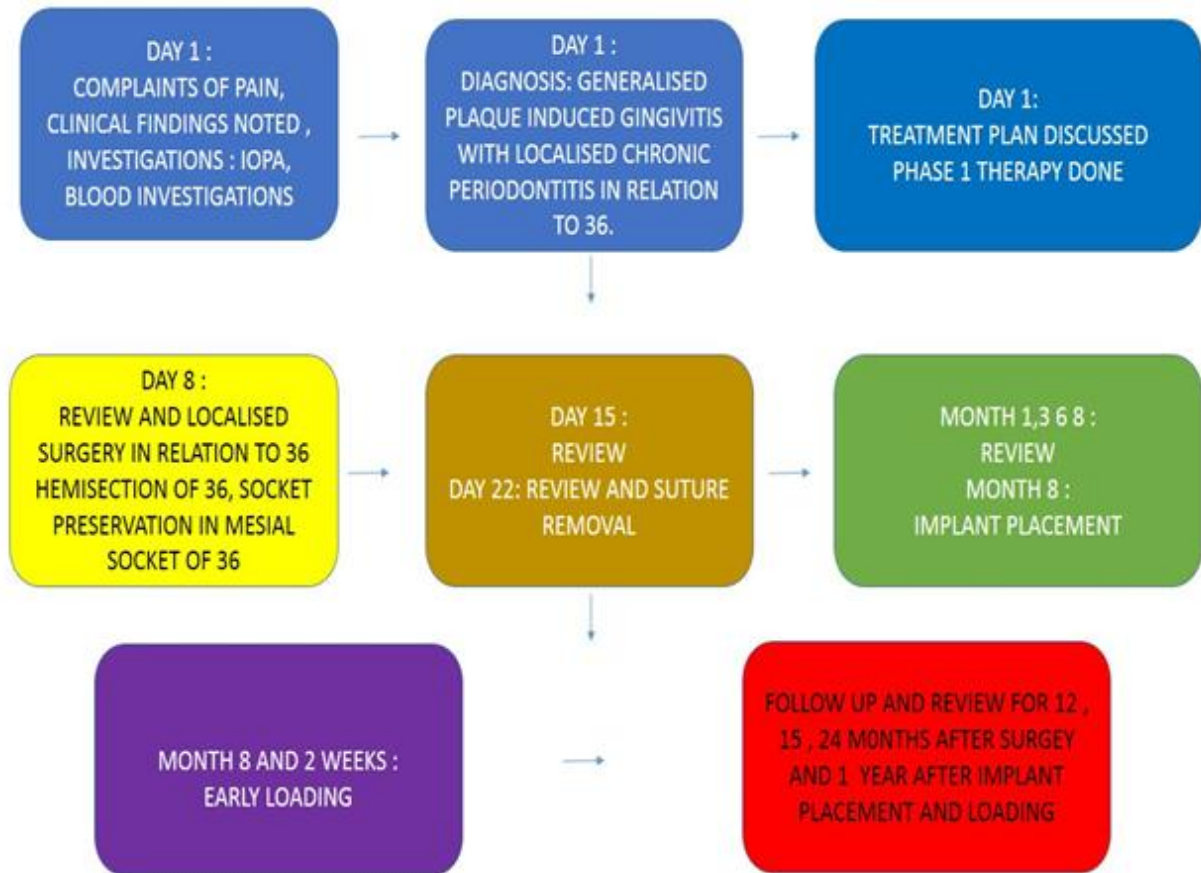


Fig. 3: Schematic representation of treatment

Discussion

Buhler stated that hemisection should be considered before every molar extraction, because it provides a good, absolute, and biological cost saving alternative with good long term success. DBM has been studied to an increasing extent in recent years in connection with alveolar ridge preservation. Overall, the studies show clinical validation and the establishment of a good therapeutic track record for DBM use. When the tooth loses part of its root support, it will require a restoration to permit it to function independently or serve as an abutment for fixed partial denture or splint. Thus, restoration is required for function and stabilization of occlusion.

Wongthai P et al, in their case report in 1993,⁴ described the replacement of the mesial root of the mandibular first

molar, 5 months after hemisection, with a root form implant followed by two separate crowns for the retained distal root and the implant 4 months after the implant placement. The results from this exploratory case offer considerable evidence to support the osteoinductive activity of the DBM graft and PRF membrane materials tested, their clinical acceptability in preserving sockets, and their ability to generate new bone capable of reliably supporting implants.

Mahender singh et al, in their case report in 2017,⁵ described the replacement of the mesial root of the mandibular first molar, immediately with BCS implants after hemisection followed by single crown for the retained distal root and the implants immediately. The results from this exploratory case offer considerable evidence to support

the BCS IMPLANTS and their clinical acceptability in immediate placements, with immediate loading.

EL Gendy et al, in their study in 2014,⁶ evaluated clinically and radiographically the validity of using hollow versus solid immediate screwimplants in the socket of extracted root of hemisected mandibular molars augmented with Cerasorb in the treatment of advanced perioendo lesion affecting mainly. They concluded that Immediate one piece (hollow or solid) implantation and augmentation with Cerasorb in the socket of extracted root of lower hemisected molars resulted in favorable clinical results with success rate up to 100% in follow up period extended up to 15 months

Conclusion

This case highlights the interdisciplinary approach of molar hemisection, implant placement and prosthetic rehabilitation as an innovative procedure providing better results with minimal patient apprehension and long term stability.

Conflict of Interest: None.

References

1. Parolia A, Gait TC, Porto IC, Mala K. Endo-perio lesion: A dilemma from 19 th until 21 st century. *J Interdiscip Dent* 2013;1;3(1):2.
2. Singh M, Batra R, Das D, Verma S, Goel M. A novel approach for restoration of hemisected mandibular first molar with immediately loaded single piece BCS implant: A case report. *J oral biol craniofac res* 2017;1;7(2):141-6.
3. Agrawal VS, Agrawal IS, Kapoor S. Hemisection: Tooth savior maneuver after iatrogenic complication. *Int J Health Allied Sci* 2015;1;4(3):185.
4. Wongthai P, Rosen J. Implant restoration of a hemisected molar: clinical report. *Implant dent* 1993;2(3):182-4.
5. Singh M, Batra R, Das D, Verma S, Goel M. A novel approach for restoration of hemisected mandibular first molar with immediately loaded single piece BCS implant: A case report. *J oral biology craniofac res* 2017;1;7(2):141-6.
6. El-Gendy AM, Nassar MM, Saudi HI. Immediate hollow versus solid screw implants augmented with bone graft in the extracted socket of hemisected mandibular molars: Clinical and radiographic study. *Tanta Dent J* 2014; 1;11(1):56-62.

How to cite this article: Chandrashekar V, Parthasarathy H, Tadepalli A, Ponnaiyan D, An innovative approach to salvage a fractured endodontically treated tooth – A case report of resection, regeneration and restoration. *Int J Periodontol Implantol* 2019;4(1):22-25.