

## A comparative study between open haemorrhoidectomy and minimal invasive procedure for haemorrhoids (MIPH) in cases of grade III and IV haemorrhoids

Shalabh Gupta<sup>1\*</sup>, Apoorv Goel<sup>2</sup>, Yogesh Yadav<sup>3</sup>, Prakhar Garg<sup>4</sup>, Tripta S Bhagat<sup>5</sup>

<sup>1</sup>Professor and Head, <sup>2</sup>Assistant Professor, <sup>3</sup>Post Graduate Trainee, <sup>4</sup>Assistant Professor, <sup>5</sup>Professor, Dept. of Surgery, Santosh Medical College and Hospitals, Santosh University, Ghaziabad, Uttar Pradesh, India

**\*Corresponding Author: Shalabh Gupta**

Email: drapurvgoel@gmail.com

### Abstract

Haemorrhoid is a common anorectal disorder which usually requires surgical intervention. Conventional haemorrhoidectomy had been practiced for long time but in 1993 Longo introduced a newer minimally invasive procedure for haemorrhoids. In this study we have compared the post-operative results of MIPH with conventional open haemorrhoidectomy. To analyze and compare various Pre and post-operative factors such as duration of surgery, post-operative pain and analgesia, duration of hospital stay, post-operative complications, recurrence and early return to work in the patients suffering from Grade III and IV Haemorrhoids undergoing Open Miligan-Morgan's haemorrhoidectomy and Minimal Invasive Procedure for Haemorrhoids(MIPH). In this prospective study a total of sixty patients underwent surgery for grade III and IV haemorrhoids at Santosh Medical College and Hospital, Ghaziabad from April 2017 to October 2018. Thirty patients in group A underwent Milligan Morgan technique of open haemorrhoidectomy and thirty patients in group B underwent Longo's technique of MIPH (Minimal Invasive Procedure for Haemorrhoids). The average duration of surgery was significantly less in MIPH group as compared to open haemorrhoidectomy group. Only 6.6% of MIPH developed early post-operative complications whereas at least 25% of open haemorrhoidectomy developed early complications such as pain, bleeding per rectum and wound infection. Early return to work was significantly better in MIPH group. MIPH is safe with a low recurrence rate and complications. It is a novel technique and has emerged as an alternative to open haemorrhoidectomy. Only limitation is the cost of the MIPH stapler device.

**Keywords:** Haemorrhoids; MIPH, Open Haemorrhoidectomy; Stapled Haemorrhoidopexy.

### Introduction

Haemorrhoids are one of the most common anorectal disorder which affects almost 25-30% of the population. It commonly present as mass protruding per rectum and fresh bleeding per rectum. Haemorrhoids may be primarily due to chronic constipation, as a consequence of adaptation of erect posture by mankind, excessive straining to expel constipated stool or hereditary. It can also occur secondarily due to carcinoma of rectum, pregnancy, uterine tumors, difficulty in micturition due to stricture or enlarged prostate and portal hypertension.<sup>1-3</sup> Haemorrhoids can be classified in many different ways. Primarily they are divided into internal, external and mixed types. Internal haemorrhoids are situated above the dentate line, covered with mucous membrane and external haemorrhoids lie below the dentate line, covered by skin. Another classification tells us the grading of the haemorrhoids ranging from grade I, being only symptomatic bleeding; grade II with spontaneous reduction of prolapsed haemorrhoids mass; grade III requiring manual repositioning of prolapsed haemorrhoids up to grade IV which are completely prolapsed haemorrhoids. The third type of classification determines haemorrhoids by their anatomical position, where 3, 7 and 11 o'clock are considered to be primary and the areas between them to be as secondary.<sup>1-3</sup>

Though grade I and early grade II haemorrhoids, can be treated conservatively with laxatives, dietary precautions and flavinoids whereas grades III and IV require surgical interventions in order to treat the condition. Some grade II and III haemorrhoids can also be treated by Injection Sclerotherapy, banding or Infra-red/laser coagulation.<sup>3,4</sup>

There are various surgical methods available such as Ferguson's closed haemorrhoidectomy, Open Miligan-Morgan hemorrhoidectomy and Longo's Stapled Haemorrhoidopexy or MIPH.<sup>5-7</sup> No recurrence and reduction of pain after haemorrhoidectomy is an important goal along with reduction in the length of hospital stay and the possibility of day care surgery. Hemorrhoidectomy by conventional technique causes considerable post-operative pain, prolong bed rest, post-operative complications and delay in return to work.<sup>8-10</sup>

MIPH (Minimal Invasive Procedure for Hemorrhoids) is a new concept introduced by Longo in 1998 which was devised to overcome these problems. Stapled haemorrhoidopexy or MIPH is an alternative for prolapsing grade III and IV haemorrhoids and has resulted in decrease post-operative pain, complications, low recurrence rate and early return to work.<sup>7-9</sup>

### Aims and Objectives

To analyze and compare various Pre and post-operative factors such as duration of surgery, post-operative pain and analgesia, duration of hospital stay, post-operative complications, recurrence and early return to work in the patients suffering from Grade III and IV Haemorrhoids undergoing Open Miligan-Morgan's haemorrhoidectomy and Minimal Invasive Procedure for Haemorrhoids(MIPH).

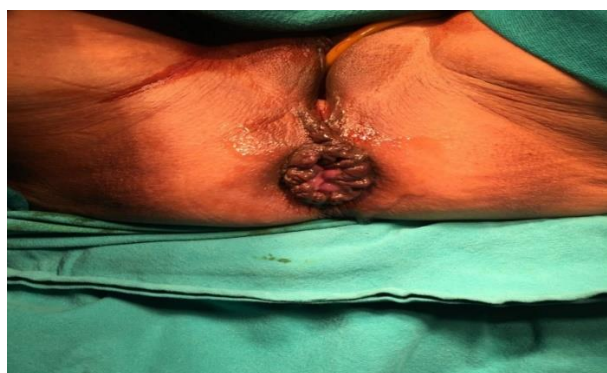### Materials and Methods

This is an interventional study carried out at Santosh Medical College and Hospitals, Ghaziabad from April 2017 to October 2018. This study included 60 Patients of grade

III and IV haemorrhoids which were randomly divided into two groups of 30 patients each. Group A was offered Conventional Open Miligan-Morgan Haemorrhoidectomy and Group B underwent MIPH. Patients in MIPH group were informed about the new technique and formal consent was taken. All Patients aged between 18 to 65 years suffering from grade III and IV haemorrhoids were included in this study. Patients with grade I and II haemorrhoids, suspected malignancy, associated Fissure-in-ano, patient unfit for surgery under Spinal Anaesthesia, Bleeding diathesis and previous ano-rectal surgery were excluded from this study. Patients underwent necessary pre-operative investigations followed by formal pre-Anaesthetic evaluation. Colonoscopy was done in few selected cases only when indicated. All patients were evaluated for various intra-operative factors and post-operative outcome and data was analysed using IBM statistical package for social sciences (SPSS) version 17.0. Chi-square test and student's t test were used for comparison of data between two groups. P value of  $<.05$  was considered significant. Pain was measured as continuous variable using visual analogue scale (VAS, a 0-10 cm scale). The surgery in both the groups was performed by an experienced ano-rectal surgeon having more than 20 years of experience in Anorectal surgery and regularly performing MIPH for more than 10 years.

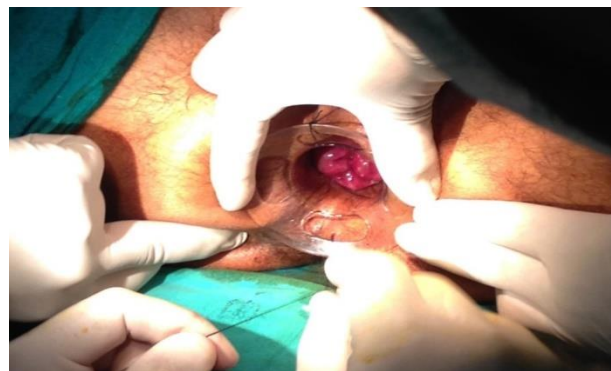#### Technique

MIPH was performed under SA (Spinal Anaesthesia) with patient in lithotomy position. Patients were re-examined under Anaesthesia to confirm the grade of haemorrhoids and to rule out associated anal pathologies like anal fissure and fistula-in-ano (Fig. 1).



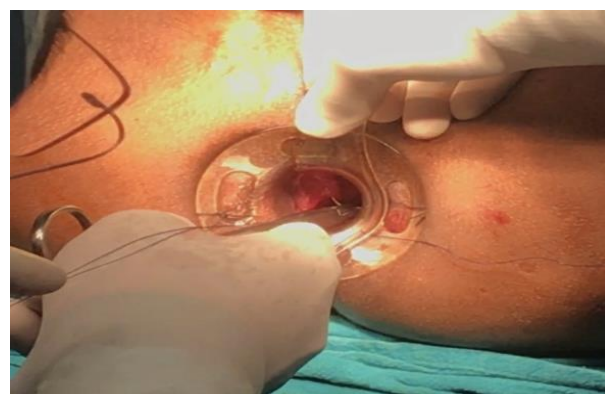
**Fig. 1:** A case of grade III haemorrhoids

A 33-mm circular stapling device 'PPH-33 Kit' which contains a Stapler gun, circular transparent anoscope, anal dilator, a purse-string transparent slit Anoscope, suture passer and 2-0 polypropylene suture. The anal sphincter was progressively dilated to three fingers with the help of anal dilator and the transparent circular Anoscope is inserted and fixed with perianal skin using silk suture which allows visualization of the dentate line at all times (Fig. 2).



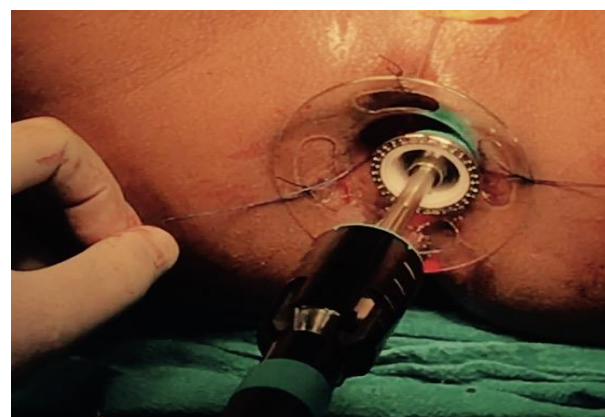
**Fig. 2:** Fixation of transparent circular anoscope

A purse-string suture with 2-0 Prolene was taken approximately 4 cm above the dentate line. Only the mucosa and Submucosa was taken during Suturing. Once purse-string was completed circumferentially, the suture Anoscope was removed from the circular Anoscope (Fig. 3).



**Fig. 3:** Purse-string submucosal sutures

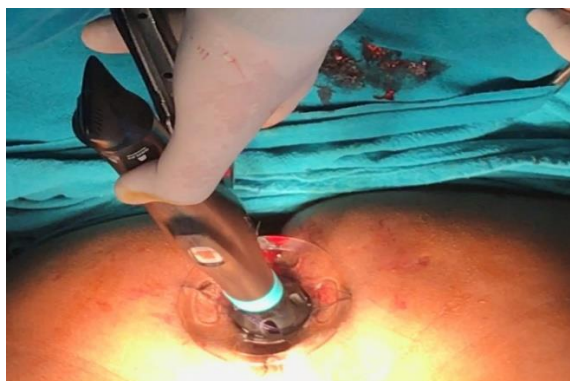The stapler gun was inserted through the circular Anoscope, with the head of the stapler maximally opened. The head was then passed through the purse-string suture. The purse-string suture was tied on the stapler shaft (Fig. 4).



**Fig. 4:** Introduction of Stapler head beyond the purse string

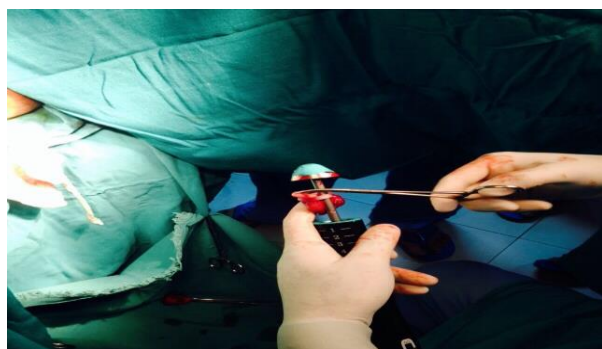
The suture passer was then passed through each of the side channels on the stapler head, and the tails of the purse-string suture were brought out from either side of the head

of the stapler and tied over the device thus giving a gentle traction. The stapler was advanced into the anal canal, such that the 4 cm mark on the head of the stapler was at the level of the anal verge, and the stapler head was tightened. Care was taken to keep the stapler in the same axis as the long axis of the anal canal to avoid deforming the anal canal. When fully closed, the stapler was fired and held closed for 45 seconds to aid Haemostasis (Fig. 5).



**Fig. 5:** Stapler device fired

The stapler was then fully opened and then gently withdrawn. Whole of the doughnut was visualized (Fig. 6). The staple line was inspected for bleeding points. Haemostatic suture with Vicryl 2-0 were taken if there were bleeding points. A small dressing was applied.



**Fig. 6:** Excised donut examined

Patients were reviewed on out-patient basis one week after surgery. Patients were advised to report immediately in cases of emergency. Patients were regularly reviewed at 1 week, 2 weeks and 3 weeks and after 6-10 weeks postoperatively. On follow up patients were asked to rate the control of their symptoms, degree of continence to flatus and stools, duration to return to normal activities and any other problem. A physical examination was also carried out at each follow-up. The outcome measures were post-operative pain, analgesia requirement, operative time, hospital stay, time taken for wound Healing, time to return to normal activity, continence and complications.

## Results

Out of 60 cases of grade III and IV Haemorrhoids 52 were male. Mean age of patients was  $45.43 \pm 13.08$  year. Most common presenting complaints of patients were bleeding and Haemorrhoidal mass protruding per rectum. Approximately 30% of patients also presented with painful defecation and perianal itching. Mean duration of surgery was significantly less (p value  $<0.05$ ) in MIPH Group ( $25.90 \pm 4.21$  minutes) as compared to open Haemorrhoidectomy Group ( $46.73 \pm 5.10$  minutes) (Table 1). Post-operative bleeding was seen in 8 patients following open Haemorrhoidectomy and 3 of them required re-suturing whereas only 1 patient in MIPH group had bleeding which significantly low. Similarly significant residual prolapse was seen in 6 cases of open Haemorrhoidectomy (Table 1). First bowel movement occurred on post-operative day 1 in 90 percent of cases in both the groups. Mean hospital stay for open Haemorrhoidectomy group was  $5.93 \pm 1.20$  days as compared to MIPH group which was only  $2.07 \pm .024$  days (Table 1). Mean wound healing time for MIPH cases was  $5.43 \pm 0.817$  days as compared to open Haemorrhoidectomy cases which was  $14.43 \pm 0.817$  days. Similarly average time for return to normal activities in MIPH group was  $4.23 \pm 0.567$  days whereas in other group it was  $18.67 \pm 0.348$  days. (Table 1). Patients were followed up to 6 months following surgery and no recurrence or incontinence was seen in both the groups (Table 1).

**Table 1:** Comparative Analysis of MIPH with conventional Miligan-Morgan Haemorrhoidectomy on basis of various Intra-operative and post-operative factors

Various Intra-operative and Post-operative Factors	Miligan-Morgan Haemorrhoidectomy	MIPH	P Value
Mean Age (years)	$46.10 \pm 12.92$	$44.77 \pm 13.42$	NS
Mean Duration of Surgery (minutes)	$46.73 \pm 5.10$	$25.90 \pm 4.21$	$< .001$ (HS)
Post-operative Bleeding (no. of cases)	1	8	$< .05$ (HS)
Hospital Stay (days)	$5.93 \pm 1.20$	$2.07 \pm .024$	$< .001$ (HS)
Residual Prolapse	Nil	6	$< .001$ (HS)
Mean duration of wound healing (days)	$14.43 \pm 0.817$	$5.43 \pm 0.817$	$< .001$ (HS)
Mean duration of return to work (days)	$18.67 \pm 0.348$	$4.23 \pm 0.567$	$< .001$ (HS)
Incontinence(At 6 months)	Nil	Nil	NS
Recurrence (At 6 months)	Nil	Nil	NS

NS - non-significant; HS – highly significant

**Table 2:** Comparative analysis of postoperative pain using VAS (Visual Analogue Scoring)

VAS (0-10)	Miligan-Morgan Haemorrhoidectomy	MIPH	P Value
Day 0	6.87±0.43	3.73±0.58	<.001(HS)
Day 1	5.67±0.45	2.10±0.55	<.001(HS)
Day 7	3.30±0.47	1.00±0.0	<.001(HS)

HS – highly significant

Post-operative pain was significantly less in MIPH group on day 0, day 1 and day 7 as per VAS scoring system and requirement of additional analgesia was significantly reduced as compared with the cases of open haemorrhoidectomy (Table 2).

### Discussion

Haemorrhoid is the commonest anorectal disorder worldwide. Grade I and early grade II can be managed conservatively but grade III, IV and late grade II Haemorrhoids require surgical intervention.<sup>2-4</sup> Many surgical techniques are available but conventional Miligan-Morgan open Haemorrhoidectomy is still the most commonly practiced. MIPH was first described by Longo in 1993 and since then this technique is quite popular.<sup>5,7</sup> In this study we have compare the outcome and various intra-operative factors between conventional Miligan-Morgan Haemorrhoidectomy and MIPH. It was found that mean age of patients presenting with grade III and IV Haemorrhoids was  $45.43 \pm 13.08$  year and approximately 90 percent of them were male. Painless bleeding per rectum and Haemorrhoidal prolapse were most common complaints however painful defecation was associated in approximately 30 percent cases.<sup>1,2</sup>

When compared with various studies mean duration of surgery for MIPH and post-operative bleeding was significantly less than open haemorrhoidectomy.<sup>8-10</sup> In MIPH group post-operative pain score (analyzed with VAS scoring system) with and subsequent requirement of analgesics was significantly reduced. Average wound healing time and early return to normal activities was much better for MIPH patients.<sup>8-11</sup> Recurrence and incontinence were not seen in any group in our study with a follow up of 6 months. Similarly various studies had shown no significant differences between long term complications in cases of MIPH and conventional open haemorrhoidectomy.<sup>10,11</sup> A systemic review and Meta-analyses by Tjandra JJ and Chan MK had shown similar results, however few studies had also shown high recurrence rates as a long term complication of MIPH.<sup>9-11</sup>

### Conclusion

MIPH is a widely used safe technique for grade III and IV Haemorrhoids with reduced pain, hospital stay and early post-operative complications. Wound healing and return to normal activities is faster and there is no significant difference in long term complications when compared with Miligan-Morgan technique. Cost of MIPH stapler gun may be a limiting factor.

**Conflict of Interest:** None.

### References

1. Sanchez C, Chinn BT. Hemorrhoids. *Clin Colon Rectal Surg* 2011;24(1):5-13.
2. Sun Z, Migaly J. Review of Hemorrhoid Disease: Presentation and Management. *Clin Colon Rectal Surg* 2016;29(1):22-9.
3. Lohsiriwat V. Hemorrhoids: from basic pathophysiology to clinical management. *World J Gastroenterol* 2012;18(17):2009-17.
4. Hall JF. Modern management of hemorrhoidal disease. *Gastroenterol Clin North Am* 2013;42(4):759-72.
5. Milligan E, Morgan C. Surgical anatomy of the anal canal and operative treatment of Hemorrhoids. *Lancet* 1937;2:1119-24.
6. Ferguson JA, Heaton JR. Closed hemorrhoidectomy. *Dis Colon Rectum* 1959;2(2):176-9.
7. Longo A.(1998) Treatment of haemorrhoids disease by reduction of mucosa and haemorrhoidal prolapse with a circular suturing device: a new procedure. In: Proceedings of the 6th World Congress of Endoscopic Surgery, Rome Italy.
8. Bota R, Ahmed M, Aziz A. Is Stapled Hemorrhoidectomy a Safe Procedure for Third and Fourth Grade Hemorrhoids? An Experience at Civil Hospital Karachi. *Indian J Surg* 2014;77(Suppl 3):1057-60.
9. Gravié JF, Lehur PA, Hutten N. Stapled hemorrhoidopexy versus milligan-morgan hemorrhoidectomy: a prospective, randomized, multicenter trial with 2-year postoperative follow up. *Ann Surg* 2005;242(1):29-35.
10. Fueglistaler P, Guenin MO, Montali. Long-term results after stapled hemorrhoidopexy: high patient satisfaction despite frequent postoperative symptoms. *Dis Colon Rectum* 2007;50(2):204-12.
11. Tjandra JJ, Chan MK. Systematic review on the procedure for prolapse and hemorrhoids (stapled hemorrhoidopexy). *Dis Colon Rectum* 2007;50(6):878-92.