

## Bladder preservation in radiation induced high grade urinary bladder sarcoma: A case report

Gautam Ram Choudhry<sup>1\*</sup>, Pawan Garg<sup>2</sup>, Aasma Nalwa<sup>3</sup>

<sup>1</sup>Associate Professor, <sup>2,3</sup>Assistant Professor, All India Institute of Medical Sciences (AIIMS), Jodhpur, Rajasthan, India

\*Corresponding Author: Gautam Ram Choudhry

Email: gautamoshu@gmail.com

### Abstract

Long-term survivors of malignancy who received radiotherapy are at a significantly increased risk for the development of second malignant neoplasms (SMNs). Urinary bladder (UB) is one of the target organ for SNM following infra-diaphragmatic radiotherapy for seminoma. Management depends upon stage of presentation and patients clinical profile often limited. Bladder sparing surgery for muscle invasive bladder cancer in carefully selected patients give equivalent results with radical cystectomy. We managed a patient of urinary bladder sarcoma who received radiotherapy for testicular seminoma 14 years ago. Patients with second malignant neoplasm have limited choices of treatment because of prior chemo- radiation, however careful selection of treatment gives appropriate results. In our case, with simultaneous marking the line of cystotomy on both side of the urinary bladder helped in preserving good capacity urinary bladder. Follow up to 28 months patient have no recurrence and no lower urinary tract symptoms.

**Keywords:** Bladder, Partial, Radiation, Sarcoma, Seminoma, Urinary.

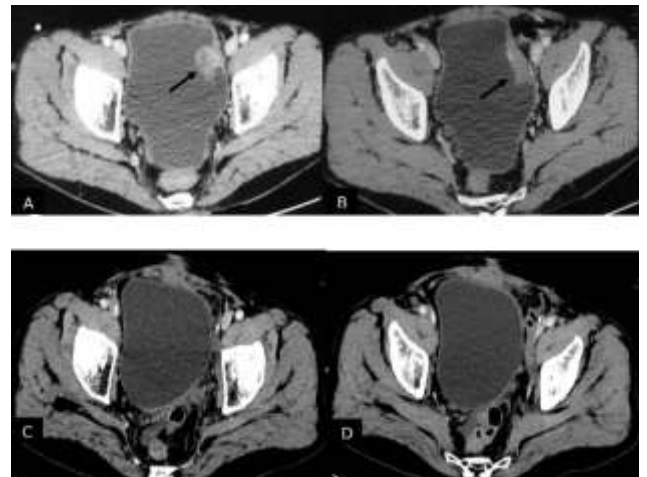
### Case

A 54 years' old gentleman, opium dependent, had received radiotherapy for left sided testicular seminoma in 2003 (26 Gy in 13#). Presented to us with history of gross, intermittent haematuria for 2 years, evaluated and found to have bladder mass (Fig. 1a). For that transurethral resection (TURBT) done in October 2016, histopathology report (HPR) was muscle invasive high grade carcinosarcoma. Partial cystectomy with pelvic lymph node dissection was performed in January 2017; step 1- cystoscopy performed ensured only single growth rest of bladder mucosa healthy, step 2- approximately 1 cm safety margin from tumour marked with Collin's knife (monopolar current), step 3- simultaneously other team already reached in extravescical space by lower abdominal midline incision, step 4- keeping cystoscope into the bladder the line of partial cystectomy marked on bladder from outside too step5- bladder decompressed and partial cystectomy with bilateral standard pelvic lymph node dissection performed. Intra-operative frozen section sent from bladder margin, was negative. In post-operative period he had urinary tract infection needed injectable antibiotics. HPR was undifferentiated pleomorphic Sarcoma (NOS) (Grade III). Follow up contrast enhanced computed tomography (CECT) in March and July 2017 showing good capacity bladder with no evidence of residual/ recurrence disease (Fig. 1b). last follow up was 1month ago, patient is doing well.

### Discussion

Following radiotherapy, second malignant neoplasm (SMN) may be in field or out of field and multiple pathogenesis have been given for this pattern. Common in field secondary malignancies after radiotherapy for seminoma are colon, prostate, uterus and bladder. With the increasing number of long-term cancer survivors, there is a growing concern about the risk of radiation induced second malignant neoplasm. It depends on type and dose of radiation and also

depends upon other factors like pre-existing susceptible genetics. Scattering of radiation and radiation induced bystander effect are the possible pathogenesis of out-of-field malignancies.<sup>2</sup>



**Fig. 1:**

Alexandra et al and Lois B et al studied testicular tumour, and SMN and found that the incidence of SMNs was increased in organs situated in areas commonly irradiated for testicular carcinoma (stomach, pancreas, urinary bladder, and kidney).<sup>3,4</sup> In a population-based study using SEER data Brown et al concluded that radiotherapy for carcinoma endometrium are associated with increased SMNs of the small intestine, colon, vagina, and urinary bladder. In their study, they found that endometrial cancer patients treated with radiotherapy, cumulative incidence for bladder SMNs at 30 years was 1.25% for patients receiving no radiation, 2.14% for brachytherapy alone, 2.71% for EBRT, and 3.48% for both in combination. They also found that patients diagnosed before age 50 years have elevated

risk for SMN and patients with well-differentiated, Grade 1 tumors had a decreased risk of SMN. Chaturvedi et al also shown that colon, rectum/anus, urinary bladder, ovary/fallopian tubes, and female genital sites were statistically significantly elevated risk of SMN.<sup>5,6</sup>

Treatment of bladder cancer primarily depends upon stage and grade of tumour. TURBT is the treatment for non-muscle invasive, low burden disease and Radical cystectomy with lymph node dissection is the treatment for muscle invasive tumour. Bladder preservation in the form of only Radiation, TURBT + Radiation and TURBT + Radiation+ Chemotherapy are other options with almost equal overall and cancer specific survival.<sup>7</sup> Solitary urinary bladder tumour away from trigone area are good candidates for bladder preservation. Results of Partial cystectomy for sarcoma are not inferior in selected population (5 years disease specific survival ranges 69-87%)<sup>8,9</sup> Hays et al, in 1995 published “the results of the partial vs total cystectomy with bladder RMS during Intergroup Rhabdomyosarcoma Study (IRS)” 40 out of 171 were treated with partial cystectomy. Thirty-one of 40 patients treated with partial cystectomy (78.5%) have been disease free for 2-16 years, one required total cystectomy and two require augmentation for small capacity bladder.<sup>10</sup> Local cancer control is not inferior in urothelial malignancy for carefully selected candidates, however late recurrence and metastasis warrants lifelong follow up.<sup>11</sup> Similarly index patient was also a good candidate for partial cystectomy and doing good till 8 months post-surgery. In SMN treatment options further narrowed because small bowel is already irradiated, so even in high grade sarcoma if negative margin can be achieved partial cystectomy is a preferred surgical option.

### Summary

Solitary urinary bladder tumour, even radiation induced, in favourable location can be treated with bladder preservation without compromising oncological principal. Lifelong follow up for recurrence and second malignant neoplasm is integral part of management of malignancy.<sup>11</sup>

**Conflict of Interest:** None.

### References

1. Kassouf W, Swanson D, Kamat AM. Partial cystectomy for muscle invasive urothelial carcinoma of the bladder: a contemporary review of the M. D. Anderson Cancer Center experience. *J Urol* 2006;175:2058–62.
2. Second Malignant Neoplasms Following Radiotherapy. Kumar S. *Int J Environ Res Public Health* 2012;9(12):4744-59.
3. Horwich A, Fossa SD, Huddart R. Second cancer risk and mortality in men treated with radiotherapy for stage I seminoma. *Br J Cancer* 2014;110(1):256-63.
4. Brown AP, Neeley ES, Werner. A population-based study of subsequent primary malignancies after endometrial cancer: genetic, environmental, and treatment-related associations. *Int J Radiat Oncol Biol Phys* 2010;78(1):127-35.
5. Travis LB, Fossa SD, Schonfeld SJ. Second cancers among 40,576 testicular cancer patients: focus on long-term survivors. *J Natl Cancer Inst* 2005;97(18):1354-65.
6. Chaturvedi AK, Engels EA, Gilbert ES. Second cancers among 104,760 survivors of cervical cancer: evaluation of long-term risk. *J Natl Cancer Inst* 2007;99(21):1634-43.
7. Smith ZL, Christodouleas JP, Keefe SM. Bladder preservation in the treatment of muscle-invasive bladder cancer (MIBC): a review of the literature and a practical approach to therapy. *BJU Int* 2013;112(1):13–25.
8. Kassouf W, Swanson D, Kamat AM, Leibovici D et al. Partial cystectomy for muscle invasive urothelial carcinoma of the bladder: a contemporary review of the M> D. Anderson Cancer Center experience. *J Urol* 2006;175(6):2058-62.
9. Stein ME, Zidan J, Charas T, Ben-Yosef R. Radiotherapy for Stage IIA seminoma: The Northern Israel Oncology Center Experience, 1971–2010. *Rep Pract Oncol Radiothe* 2014;19(5):281-6.
10. Hays DM, Raney RB, Wharam MDI. Children with vesical rhabdomyosarcoma (RMS) treated by partial cystectomy with neoadjuvant or adjuvant chemotherapy, with or without radiotherapy. A report from the Intergroup Rhabdomyosarcoma Study (IRS) Committee. *J Pediatr Hematol Oncol* 1995;17(1):46-52.
11. Capitanio U, Isbarn H, Shariat SF. Partial cystectomy does not undermine cancer control in appropriately selected patients with urothelial carcinoma of the bladder: a population-based matched analysis. *Urol* 2009;74:858–64.

**How to cite this article:** Choudhry GR, Garg P, Nalwa A. Bladder preservation in radiation induced high grade urinary bladder sarcoma: A case report. *J Urol, Nephrol Hepatol Sci* 2019;2(2):27-8.